

# **Unknown Slides Conference**

**Jae Y. Ro, MD, PhD**

**Weill Medical College of Cornell Univ.**

**The Methodist Hospital, and UT**

**MD Anderson Cancer Center**

**Houston, TX**

**November 9, 2013**

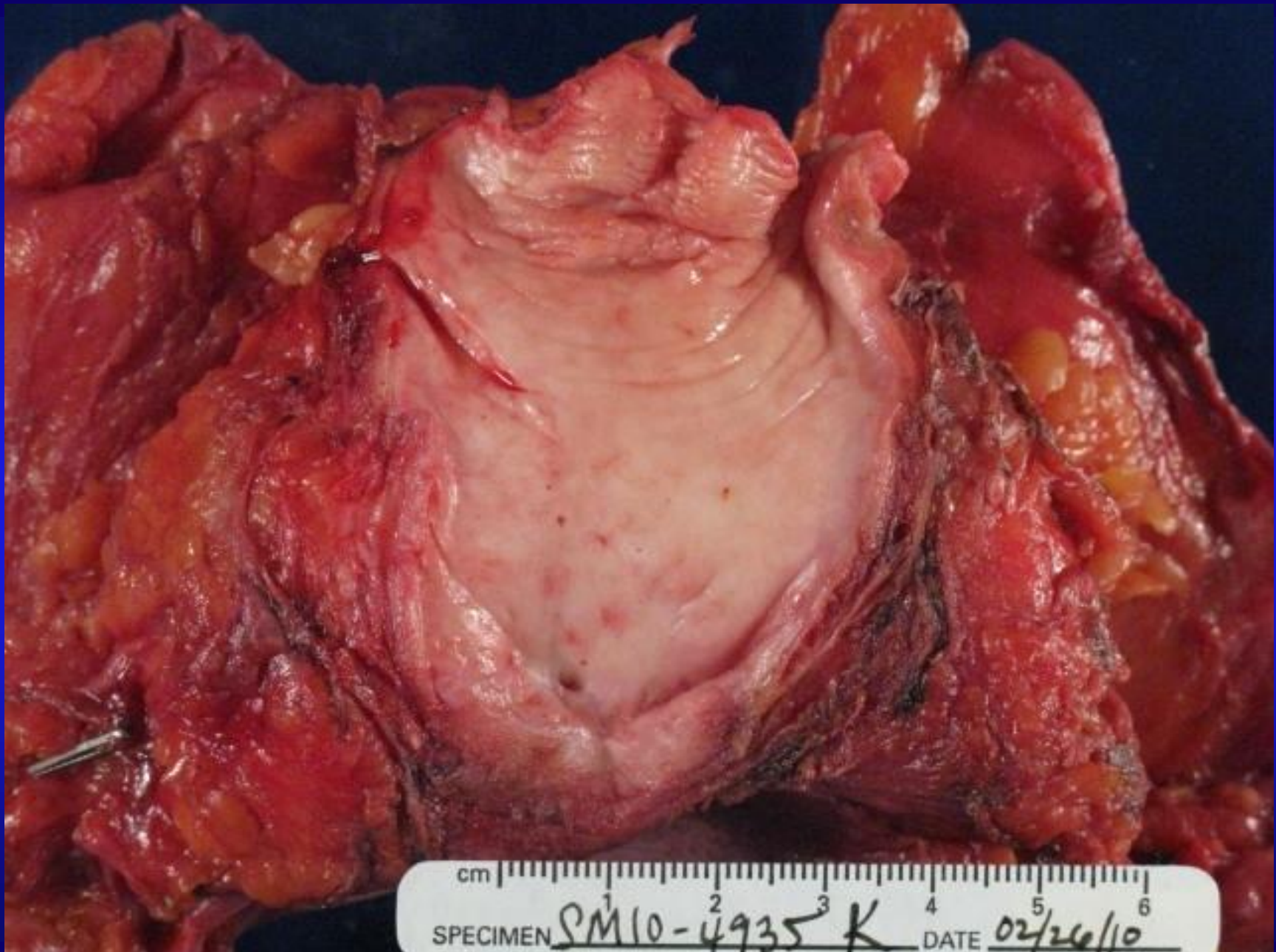**Amman, Jordan**

**25<sup>th</sup> Congress of IAP, Arab Division**  
**5<sup>th</sup> Int. Conf of Jordanian Society of Pathologists**  
November 7-9, 2013 , Amman, Jordan

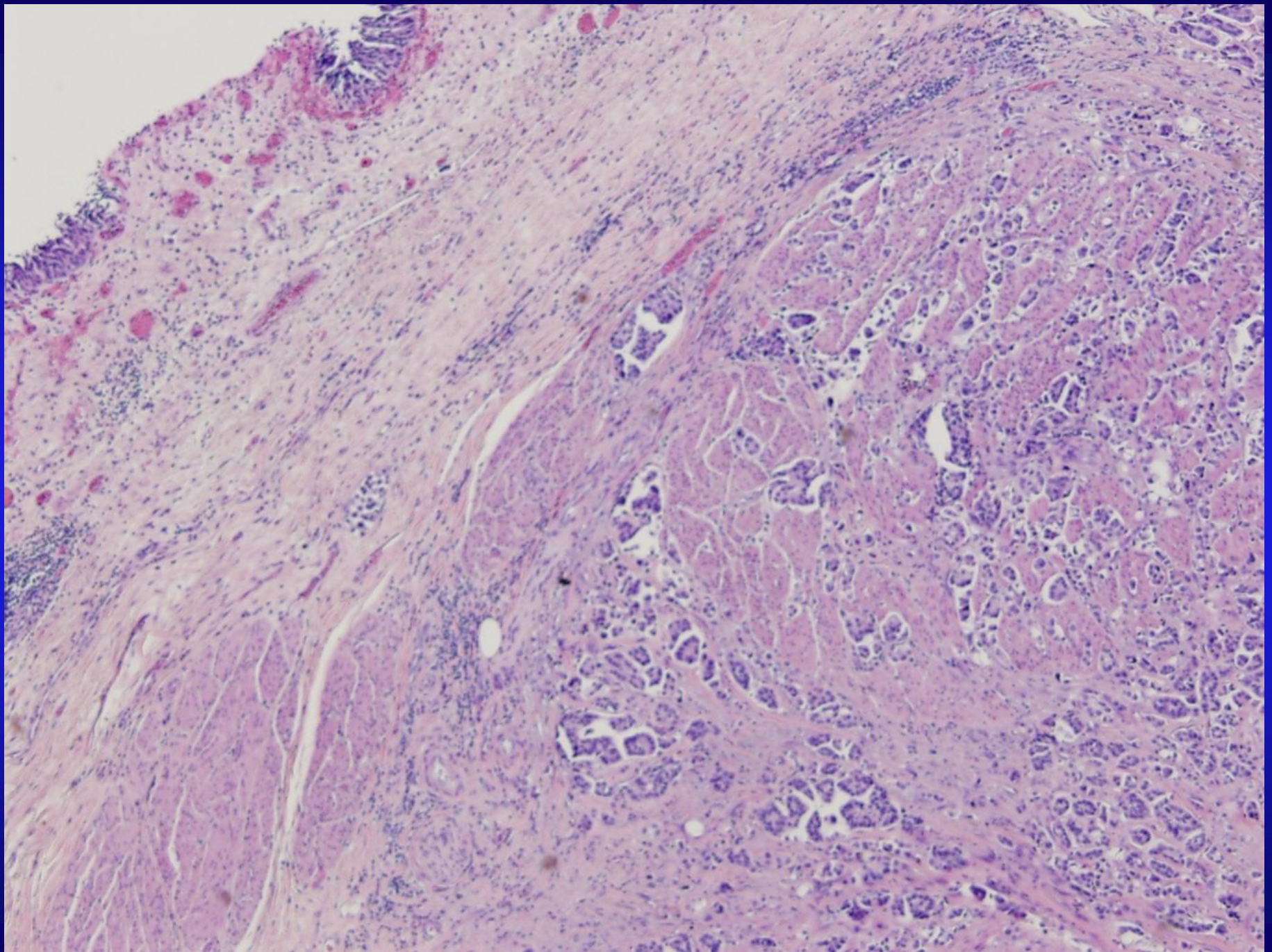


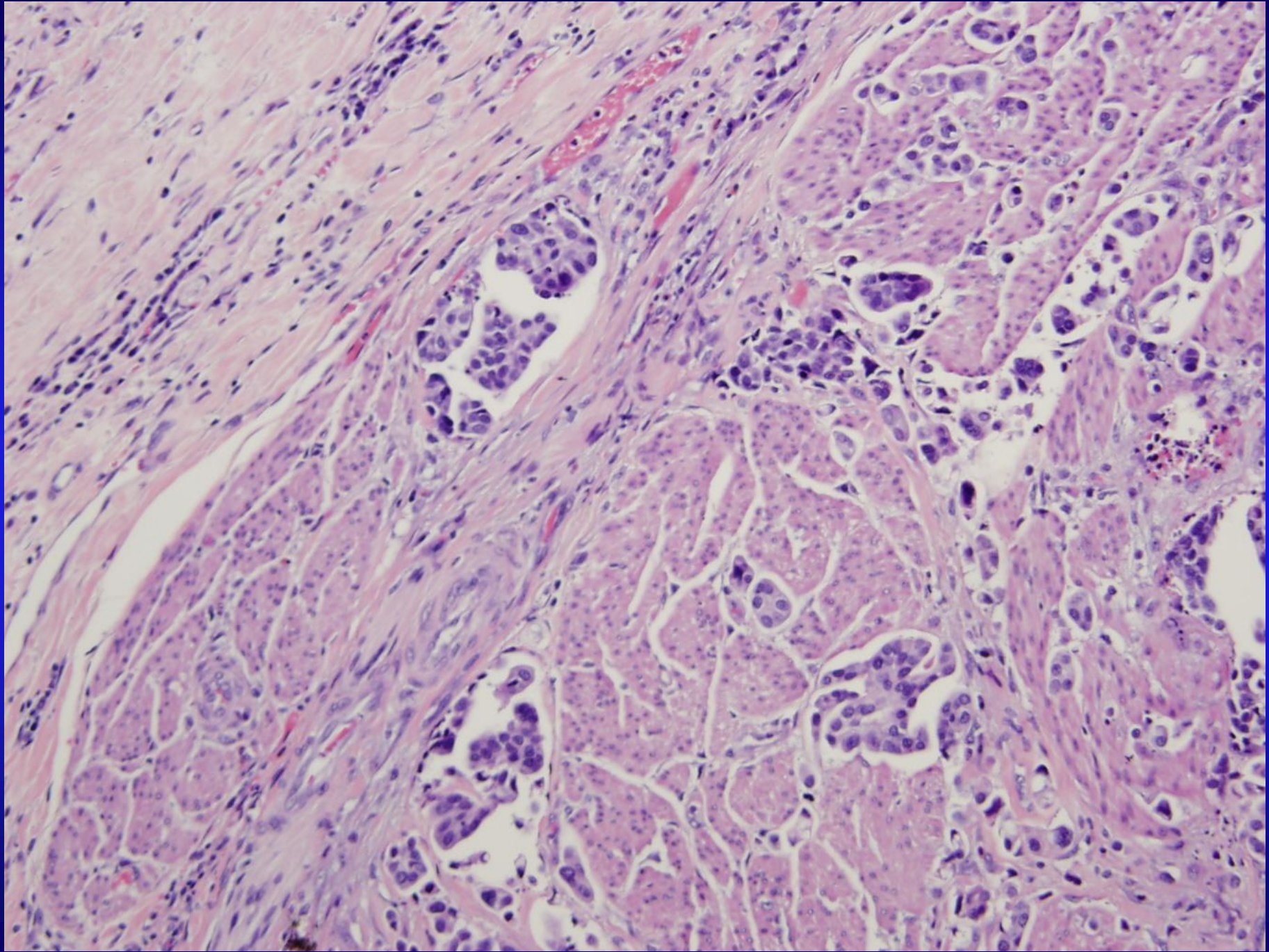
# Case 1

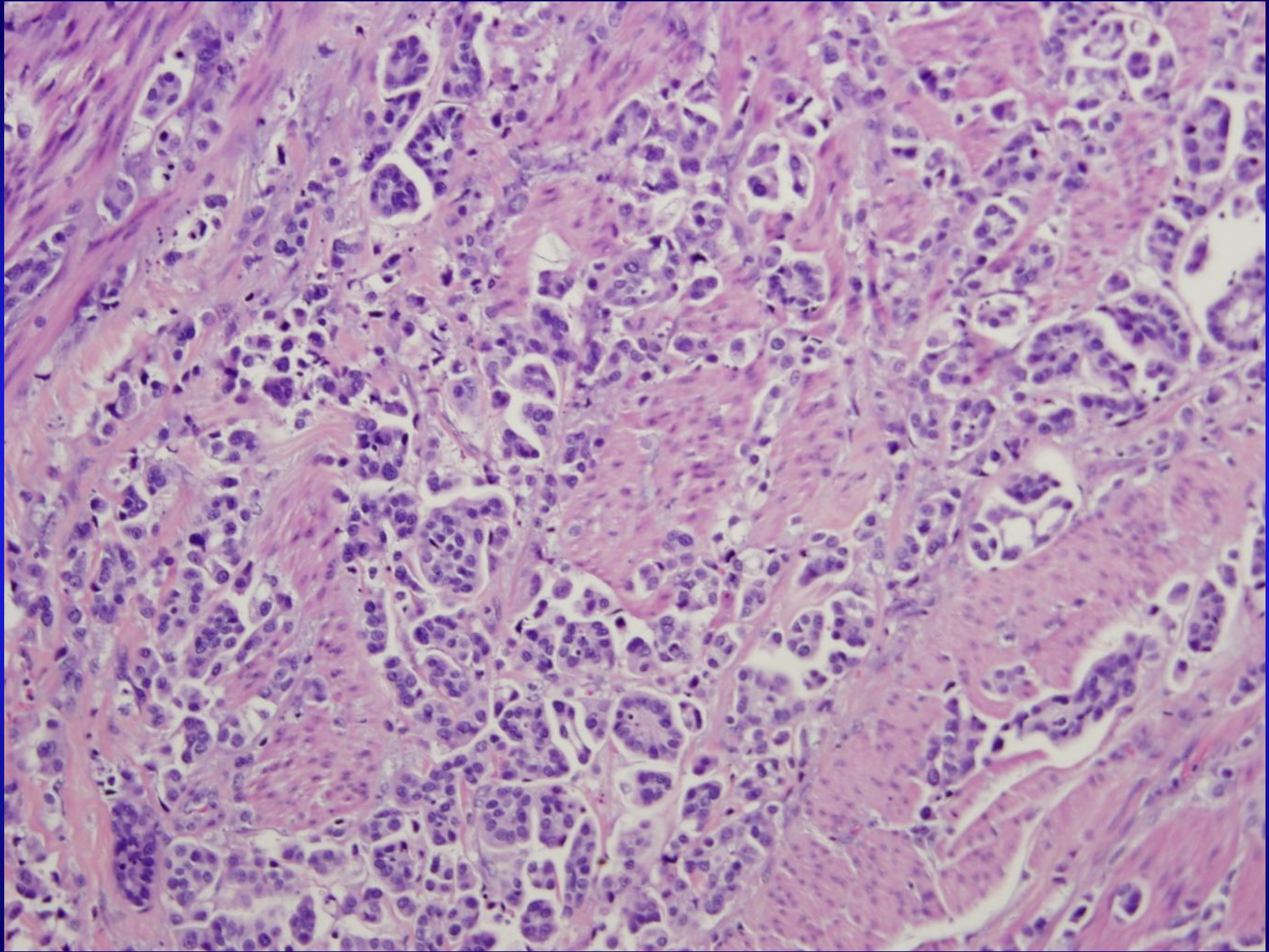
- **SM10-4935**
- **72 yo female. CT scan showed a right renal simple cysts and abnormal bladder wall thickening.**
- **TURBT with T2a grade 3 TCC.**

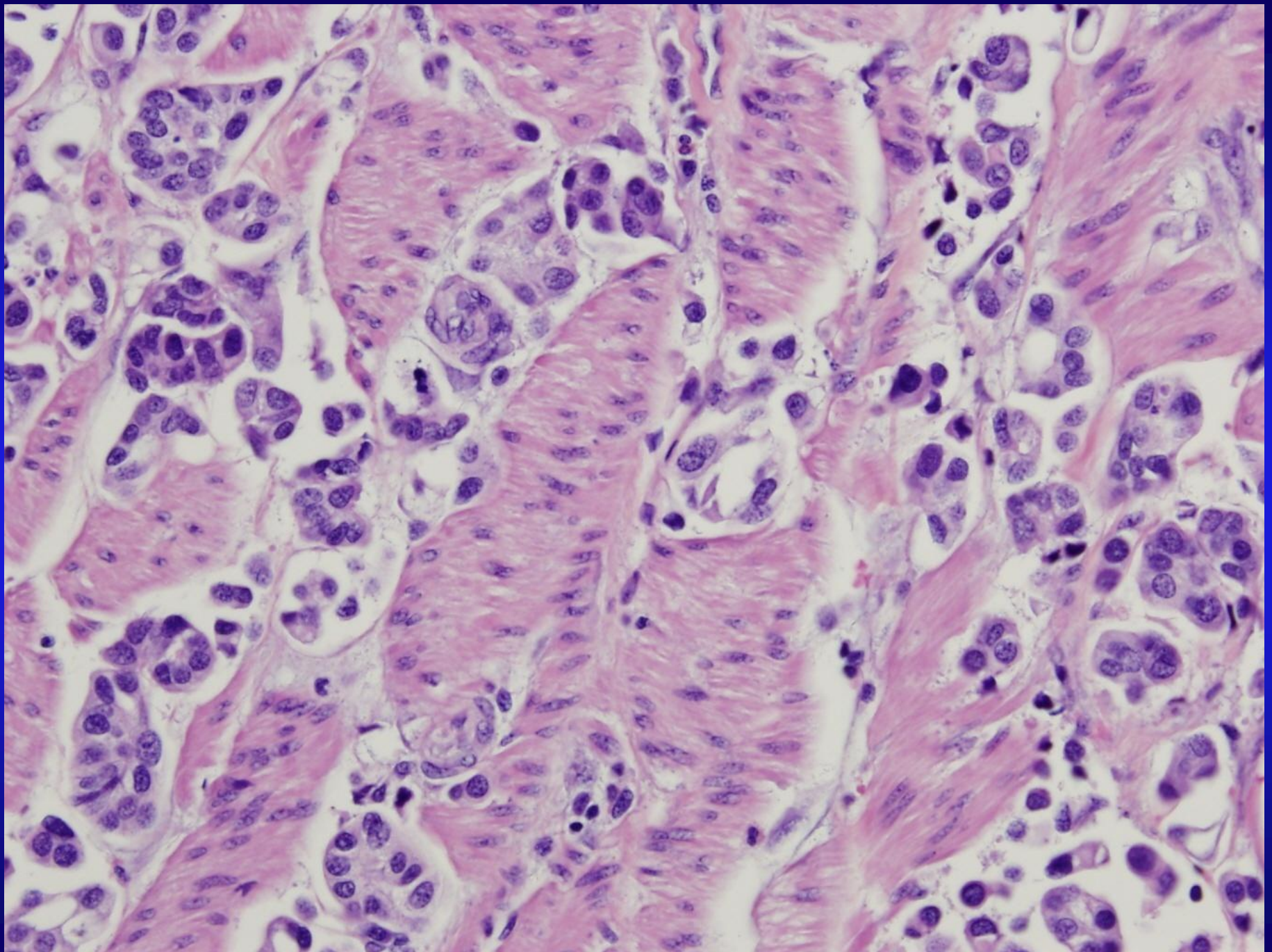


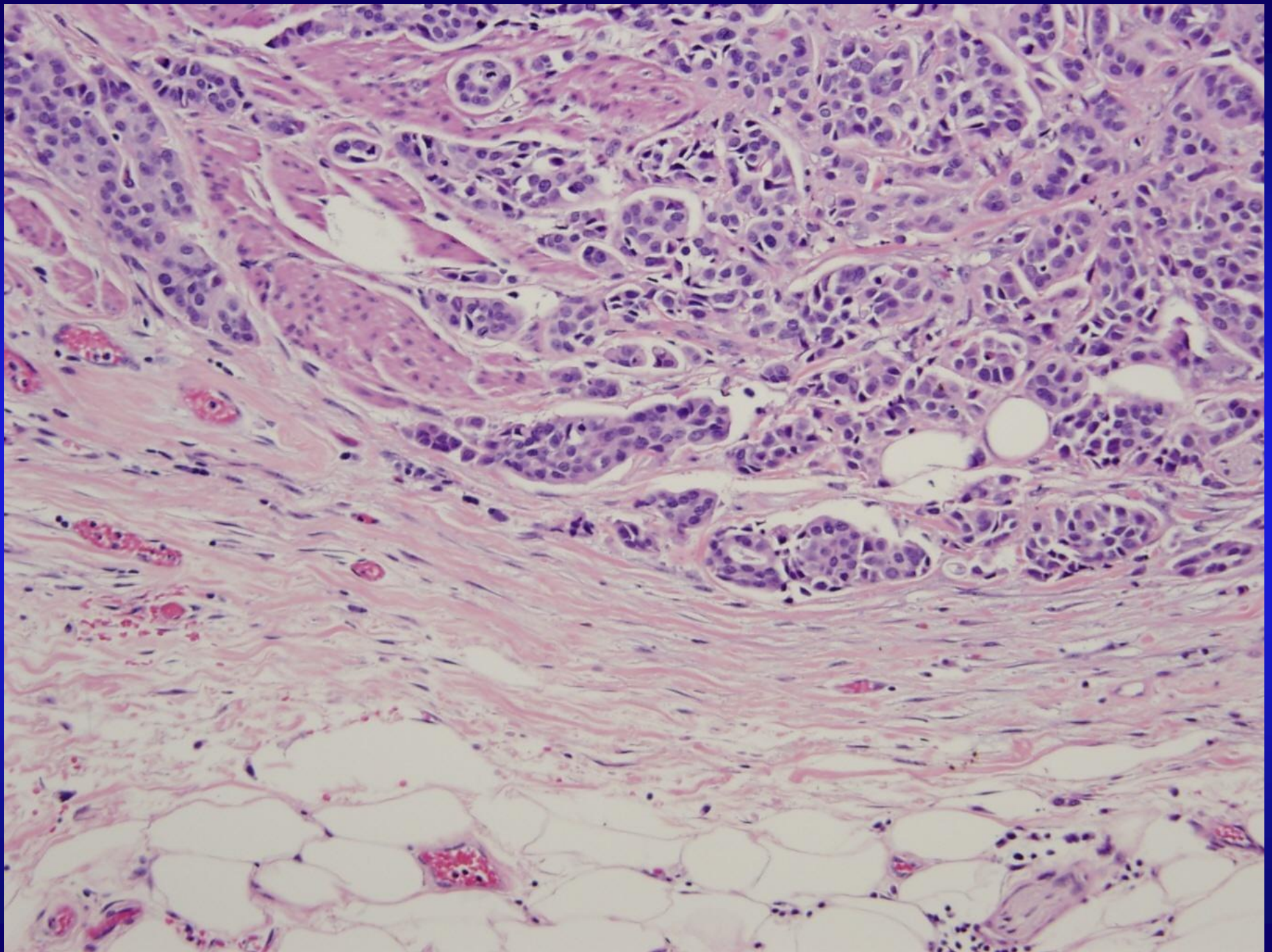
cm 1 2 3 4 5 6  
SPECIMEN SM10-4935<sup>3</sup> K DATE 02/26/10

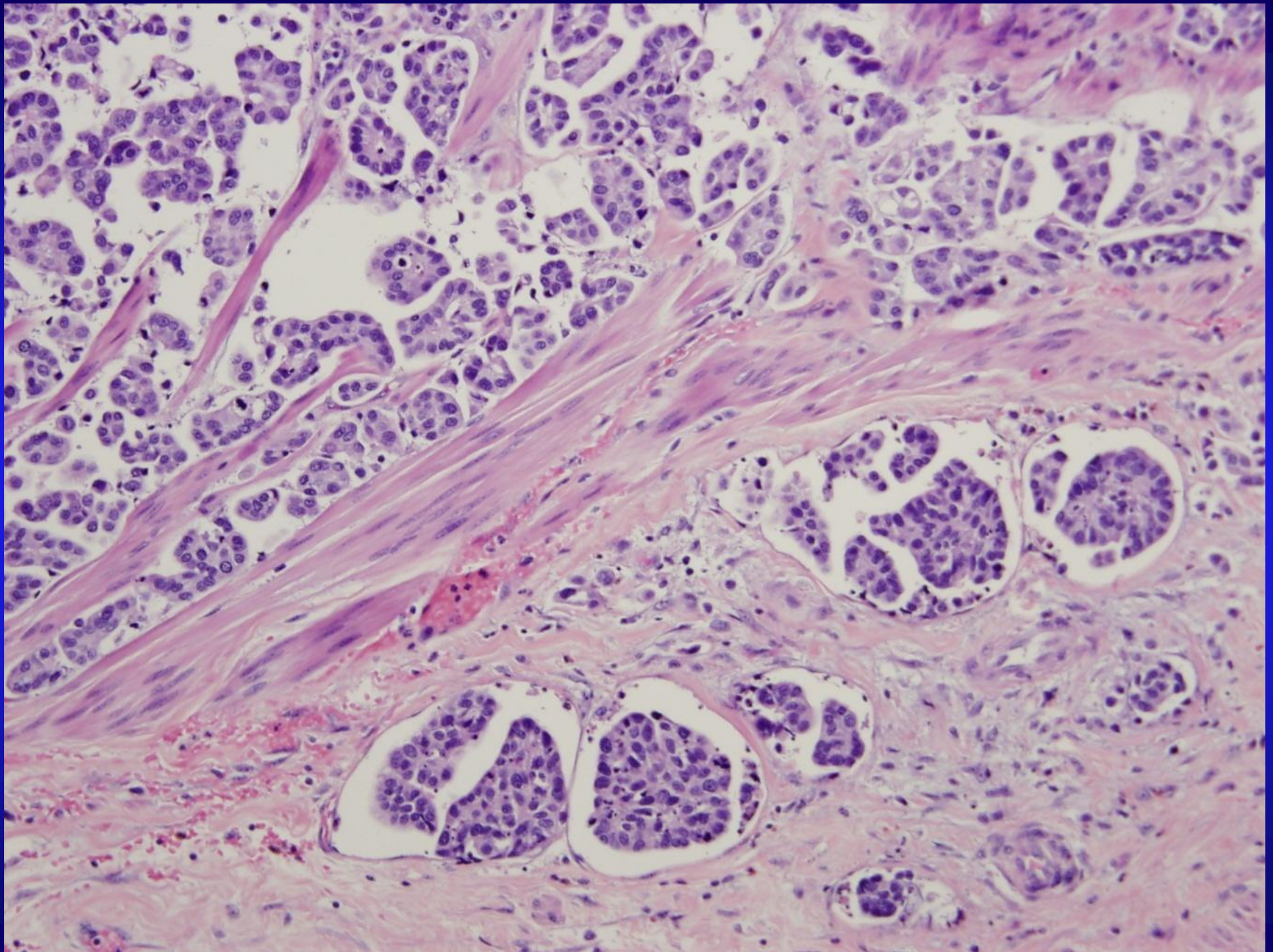


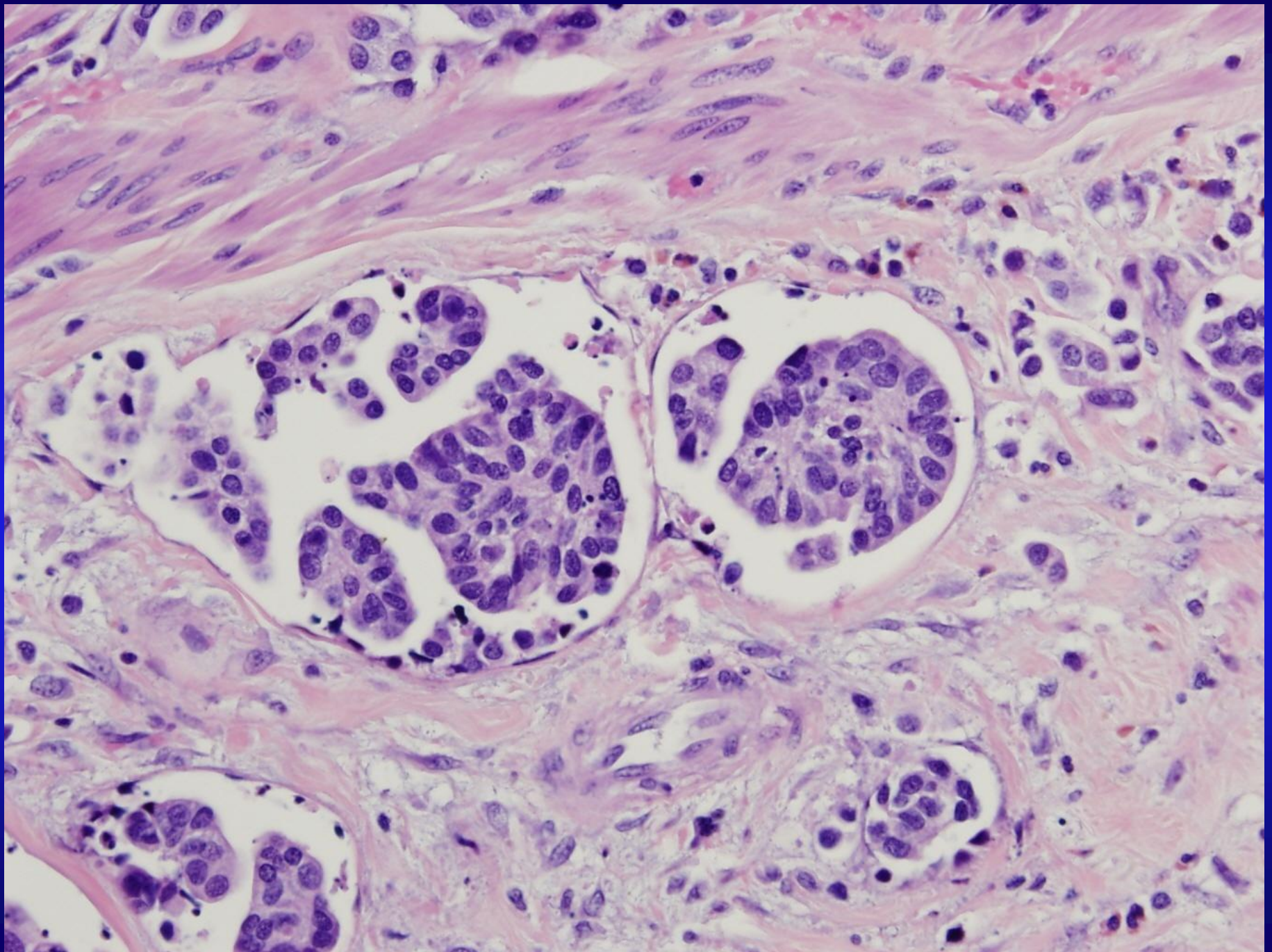


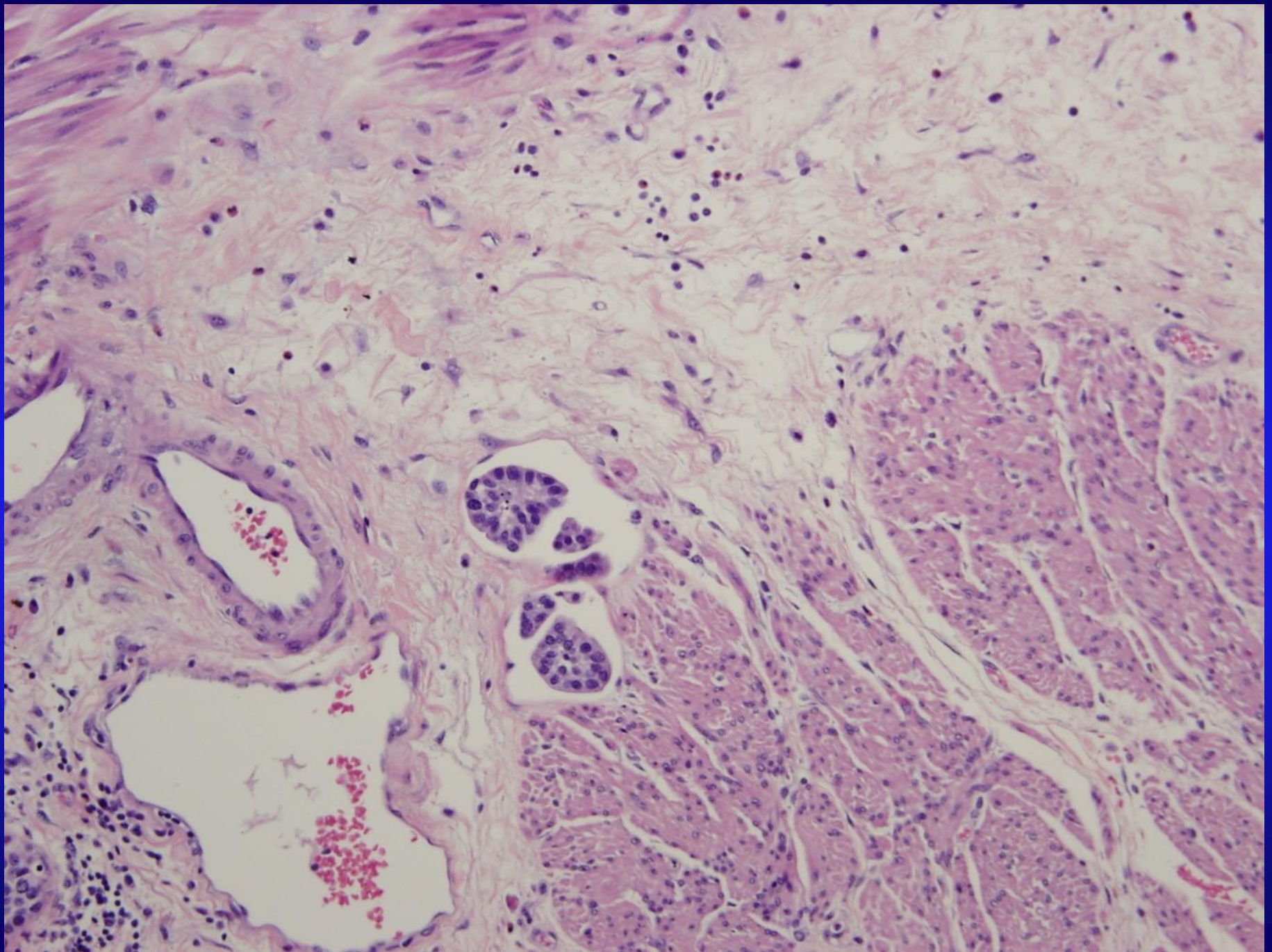


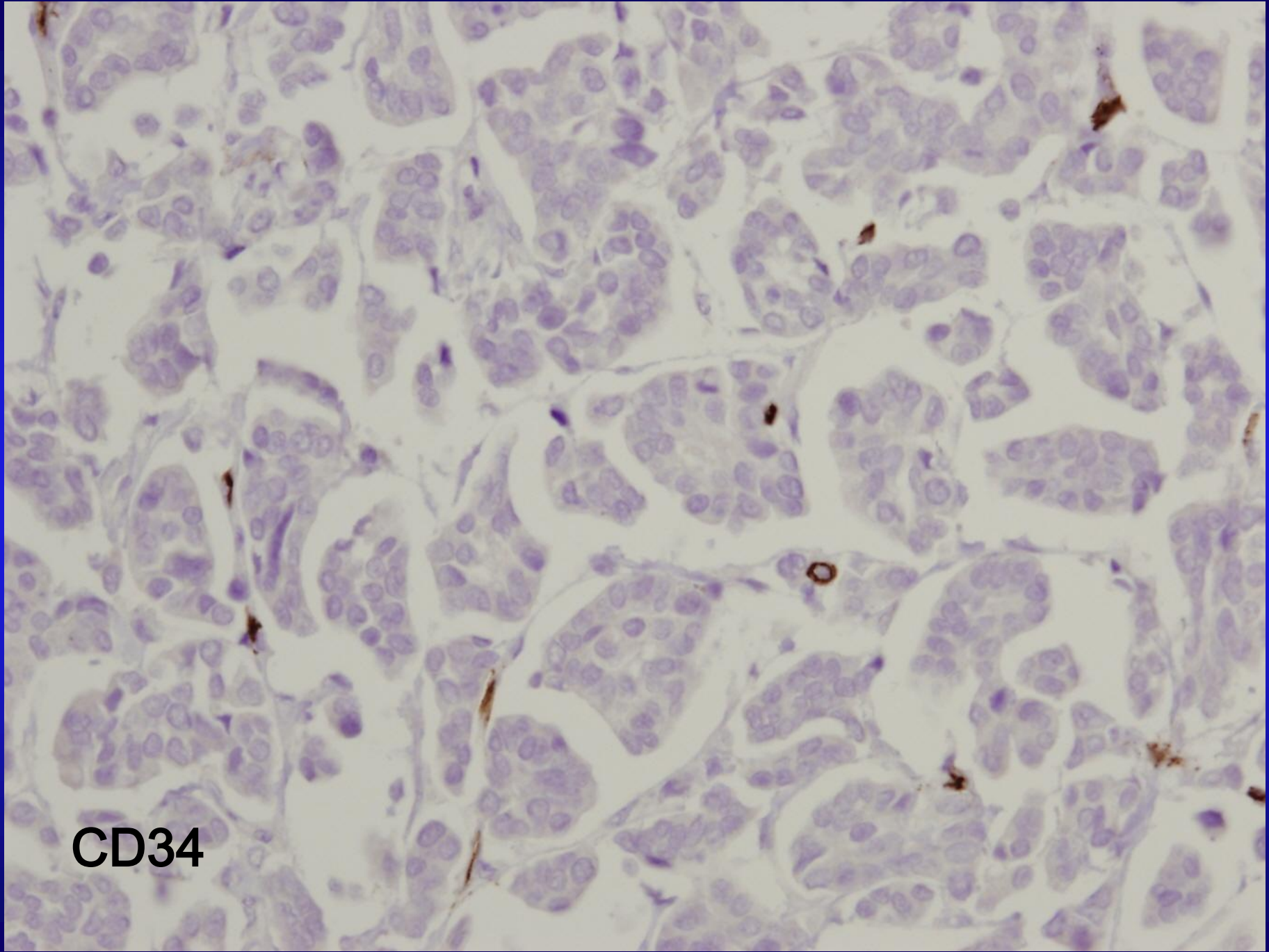




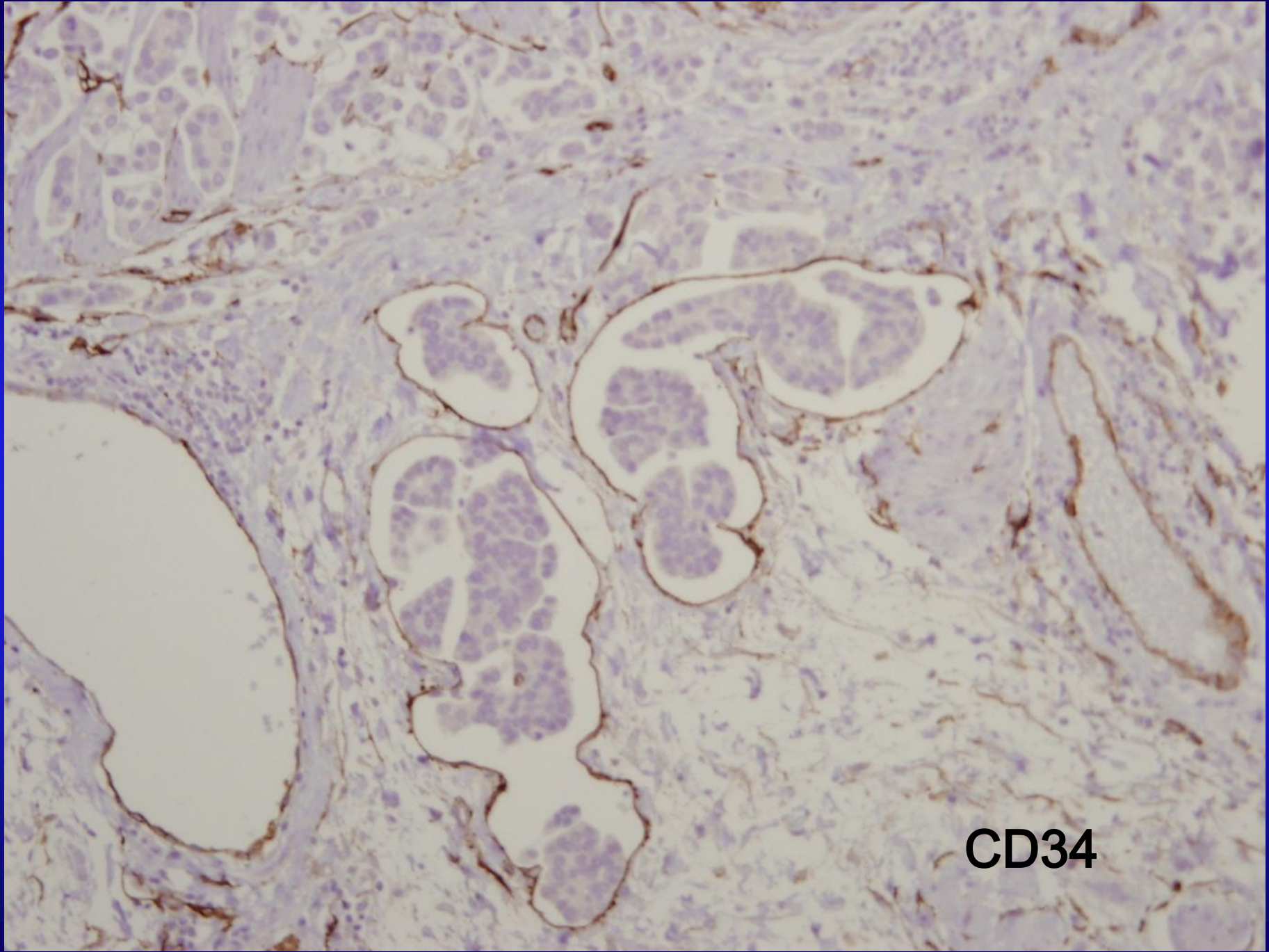




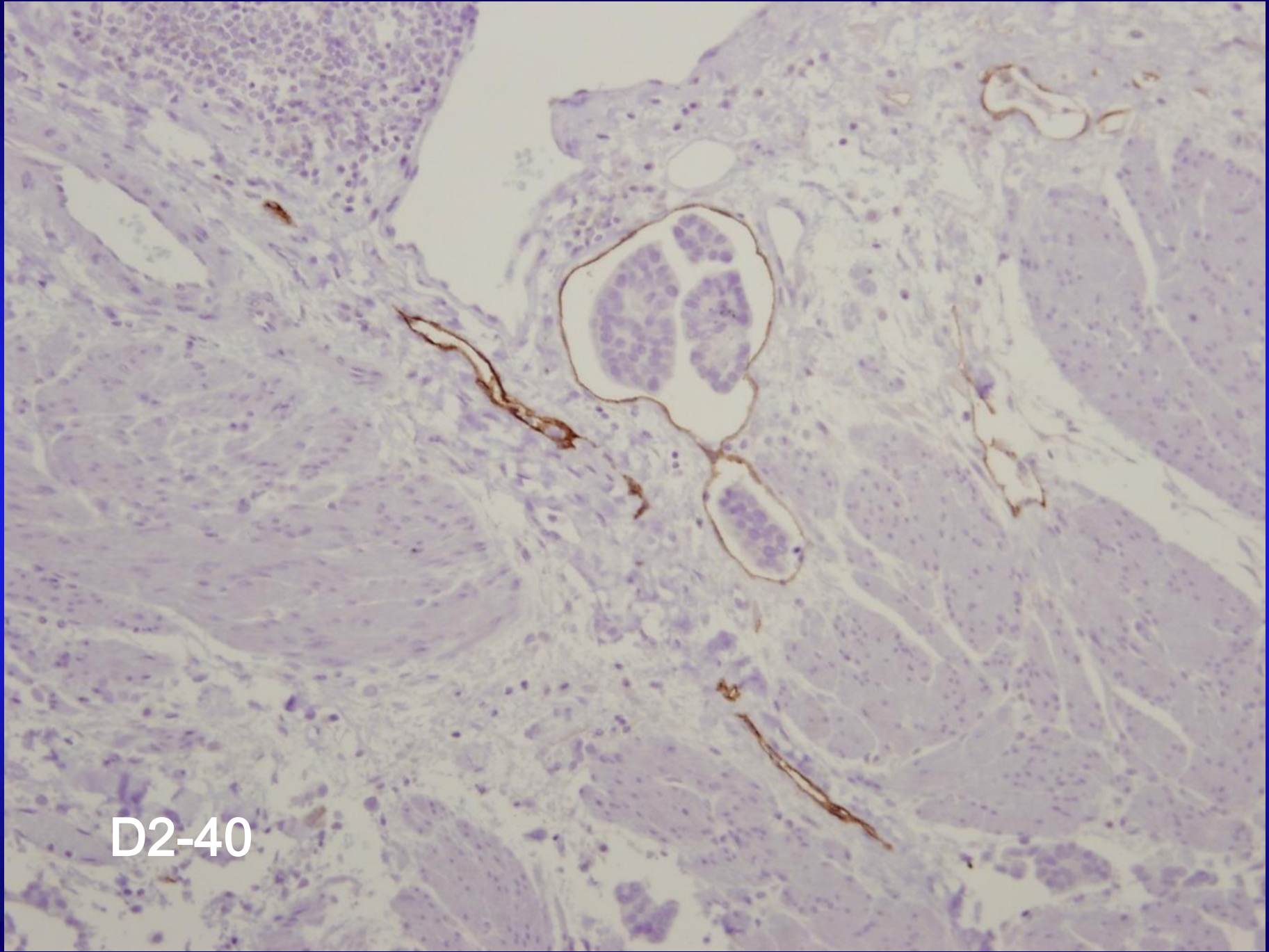




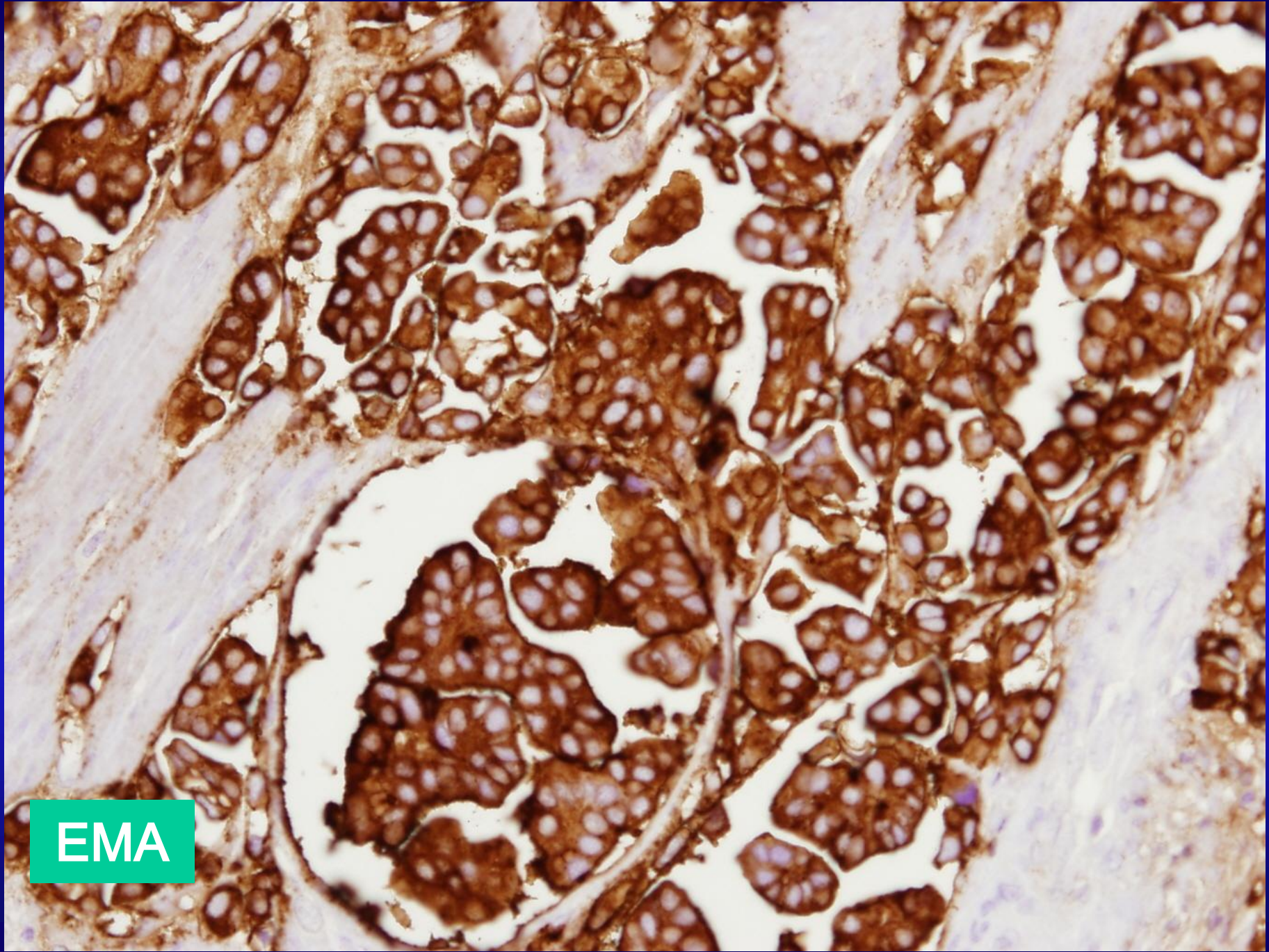
**CD34**



**CD34**



D2-40

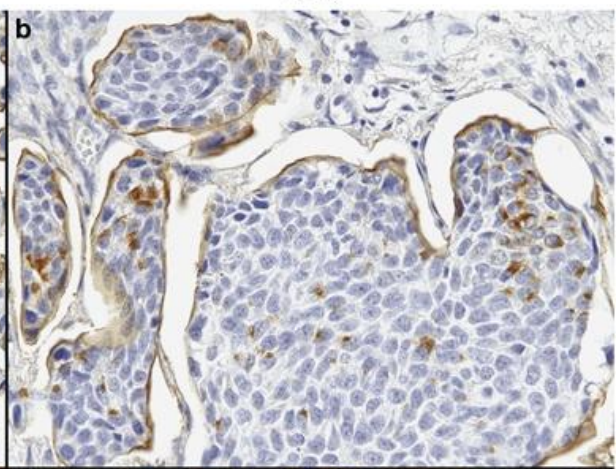
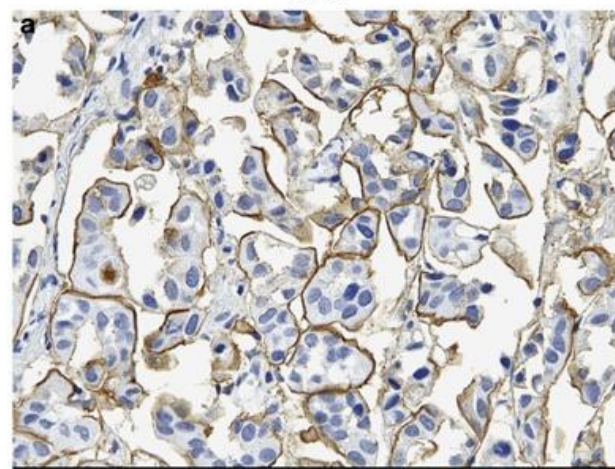


EMA

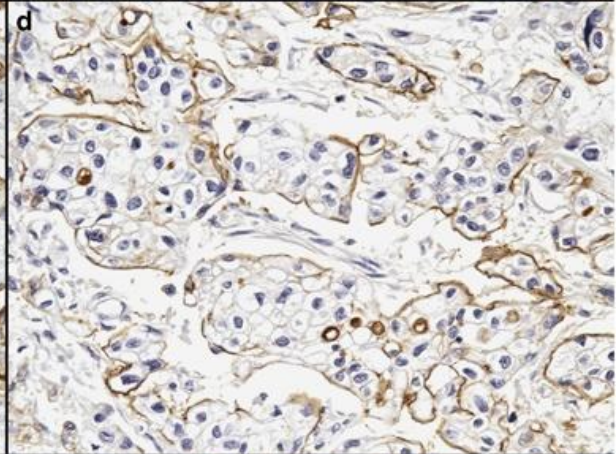
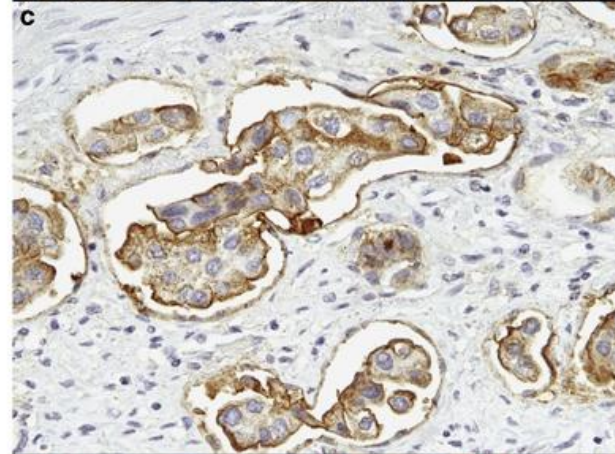
IMPC

IUC-R

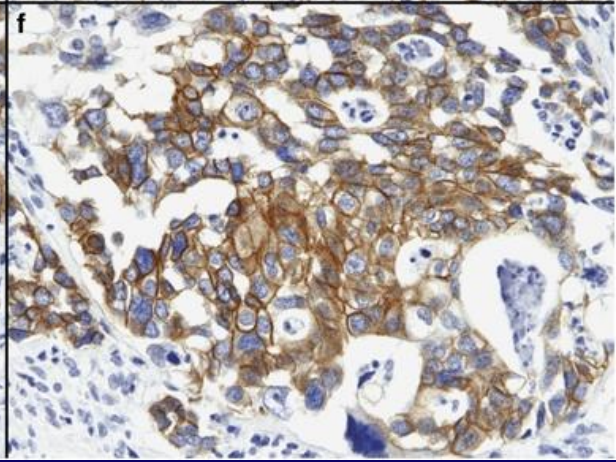
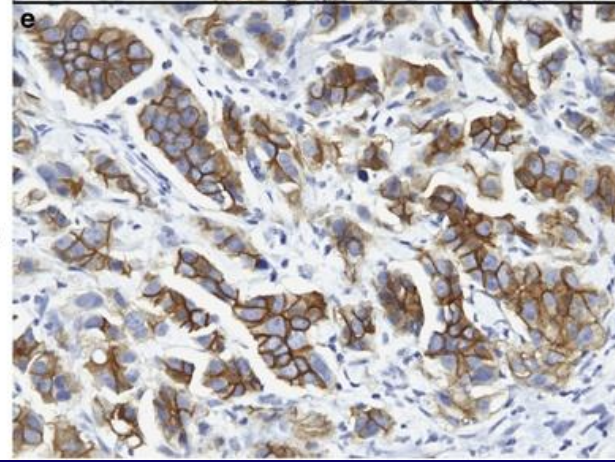
MUC1



CA125



Hev2Neu



# Diagnosis

- **Micropapillary carcinoma**
- **MPC-mimicker**

# **Micropapillary carcinoma**

- **At least 500 cases of MPC of the bladder have been reported as a special variant since its first description in 1994 by Amin et al.**
- **MPC is reported to comprise 0.6 to 8.2% of urothelial carcinoma**
- **Male to female ratio of 5:1 to 10:1 which is higher than that for conventional UC which is 3:1**

# **Micropapillary carcinoma**

- **reminiscent of the papillary configuration seen in ovarian papillary serous tumors**
- **mucosal surface as slender delicate processes which are usually devoid of a fibrovascular core and appear as glomeruloid bodies on cross section**
- **invasive component as small tight cell nests or balls contained in lacunae or stromal retraction spaces**
- **reversed polarity to the external surface of tumor nests: LVI frequent**
- **Psammoma bodies, rare; combined with other TCC**

# **Micropapillary carcinoma**

- **its distinction from conventional UC with prominent retraction artifacts**
- **Sangoi et al (Am J Surg Pathol. 2010;34:1367-76)**
- ✓ **multiple or small tumor nests in lacunar spaces are important diagnostic clues, while large or branching nests with anastomoses and confluence argue against the diagnosis**
- **combining uroplakin III and CK20 (bladder), and CK20 and CDX2 (colon), TTF-1 (lung), ER and mammaglobin (breast) and WT-1 and PAX8 (ovary)**
- **early cystectomy for the non-muscle-invasive MPC is advocated (Kamat et al, MDACC)**

# **Infiltrating Urothelial Carcinoma**

## **Micropapillary Variant**

- **An aggressive, high grade, high stage variant of urothelial carcinoma**
- **Male predominance, 5<sup>th</sup>-9<sup>th</sup> decade (Avg. 66y/o)**
- **Associated with conventional urothelial carcinoma or rarely with adenocarcinoma**
- **Slender-delicate fine papillae and fillform processes**
- **Invasive portion show tiny cell nests or slender papillae contained within tissue retraction (lacunar) spaces**
- **Nuclei with prominent nucleoli & irregular distribution of chromatin, abundant cytoplasm. Few to numerous mitoses**

# Infiltrating Urothelial Carcinoma Micropapillary Variant

- Invariably muscle invasive (*presence of a micropapillary surface component, noninvasive or lamina propria invasive tumor w/o muscularis propria in the specimen should prompt suggestion of rebiopsy because of the high association of muscularis propria invasion*)
- High incidence of lymphovascular invasion, high incidence of metastases and mortality

# **Infiltrating Urothelial Carcinoma Micropapillary Variant**

- **Immunoprofile**
  - **Positive for CK7, CK20, EMA, CEA**
  - **Positive for MUC1, CA125 and Her2/neu (micropapillary vs. conventional); only MUC1 (P=0.0102)**

**Mod Pathol 2009 May;22(5):660-7.**

**Epub 2009 Mar 6**

# **Infiltrating Urothelial Carcinoma Micropapillary Variant**

- **Differentiated from other carcinomas with a micropapillary component:**
  - **Micropapillary carcinoma of lung, breast and ovary (CK7+/CK20-)**
  - **Micropapillary carcinoma of colon (CK7-/CK20+)**

# Infiltrating Urothelial Carcinoma

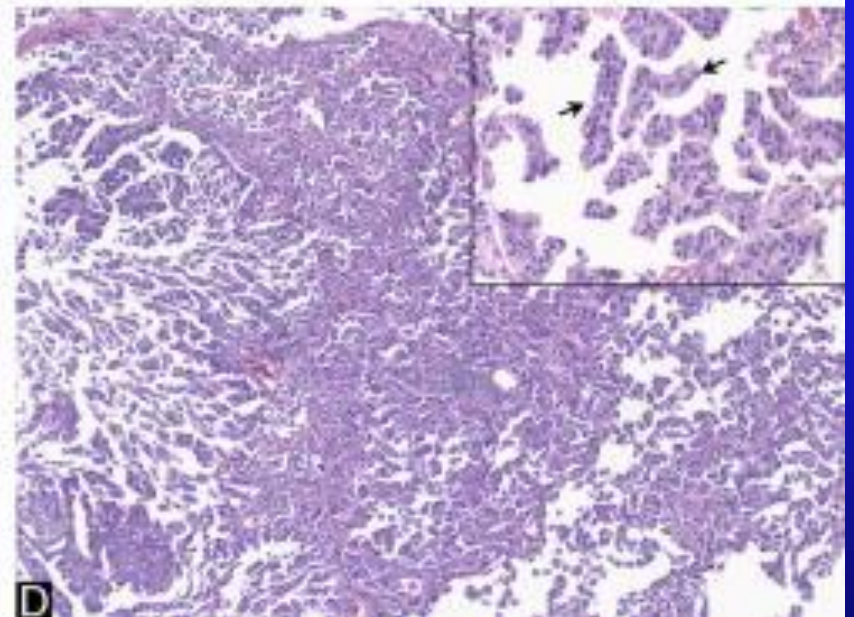
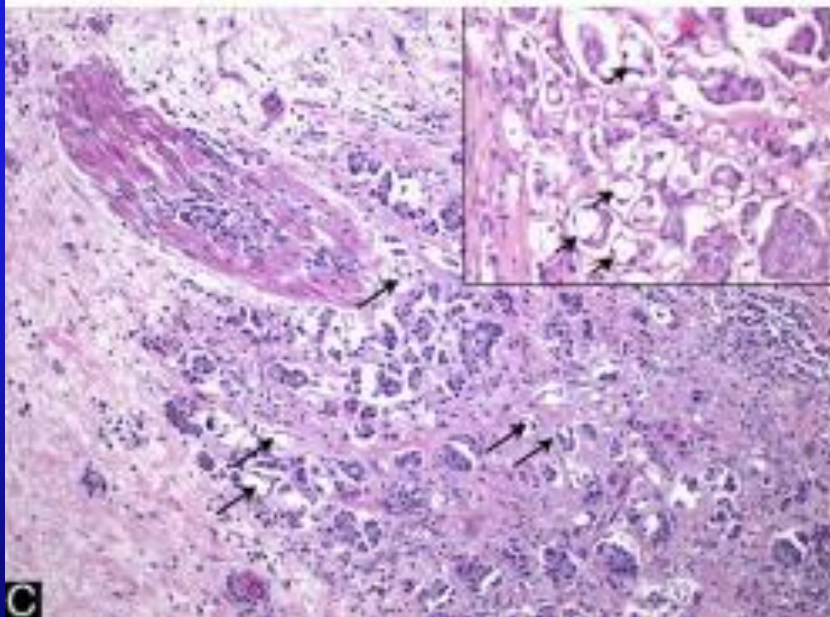
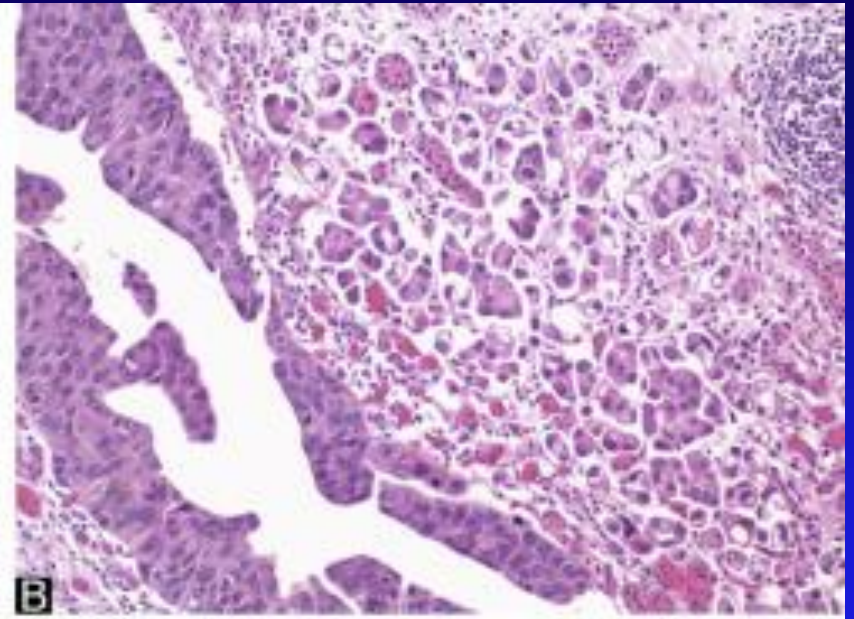
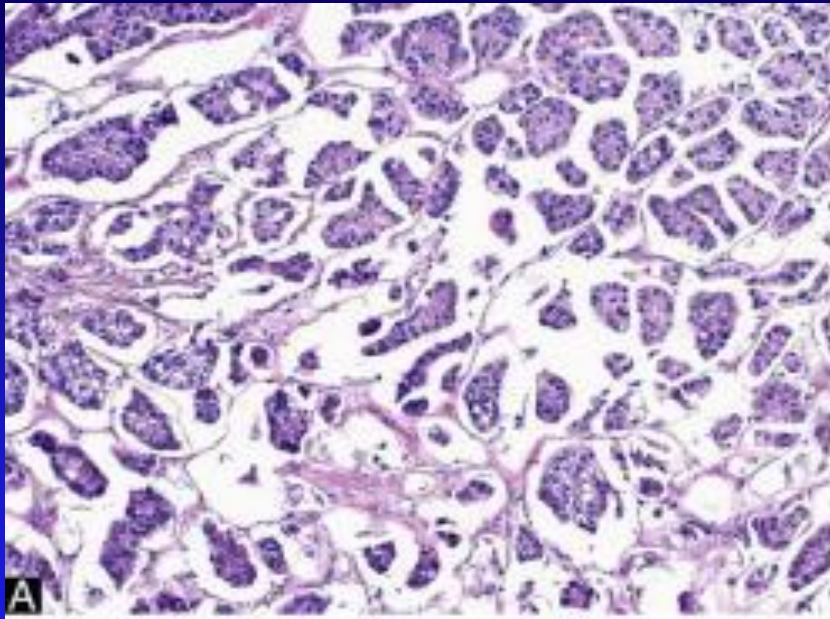
## Micropapillary Variant

- The prognosis is related to the proportion and location of the micropapillary component
- Focal & surface micropapillary component are not invariably associated with a poor prognosis but have a high chance of deep muscle invasion
- Micropapillary ca only invading lamina propria: candidate for cystectomy (?)

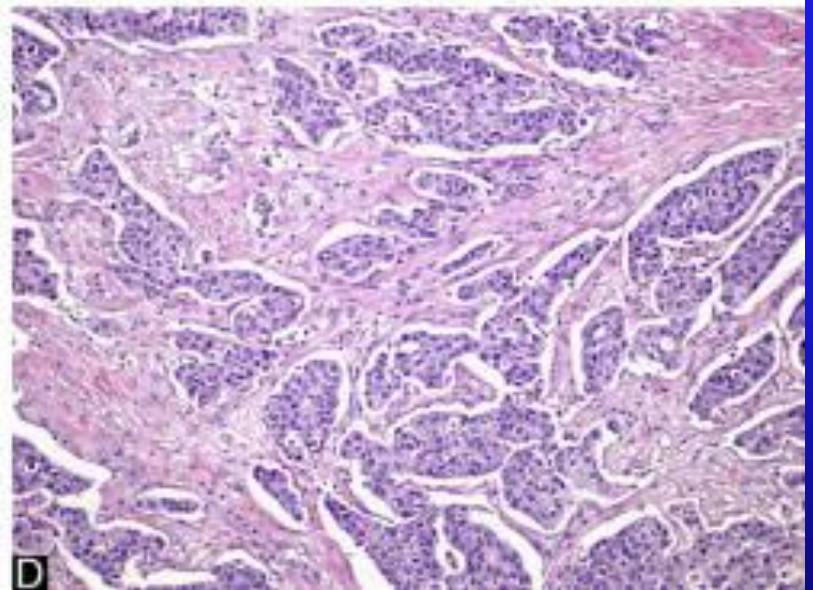
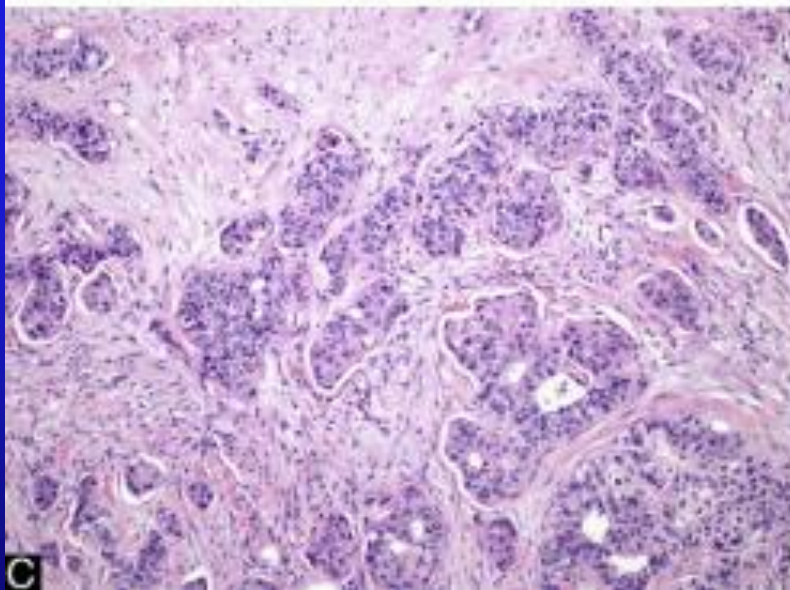
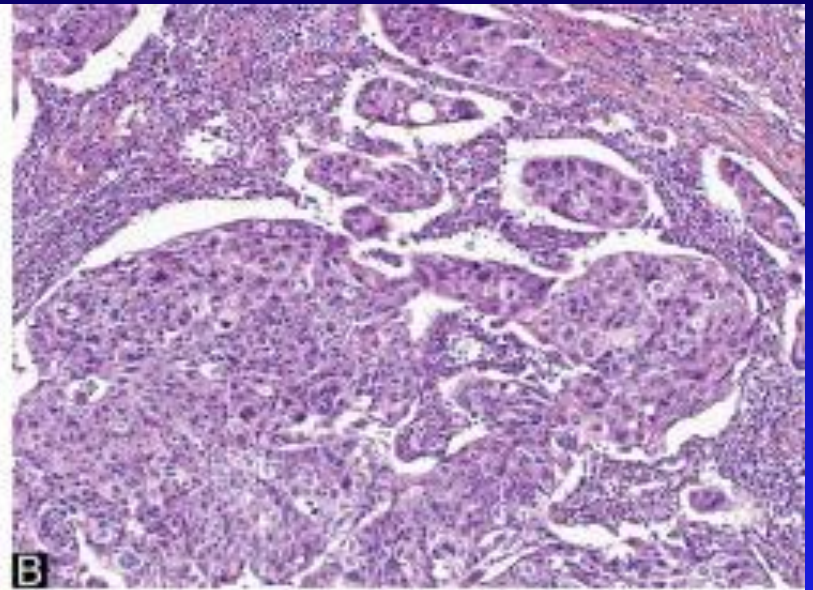
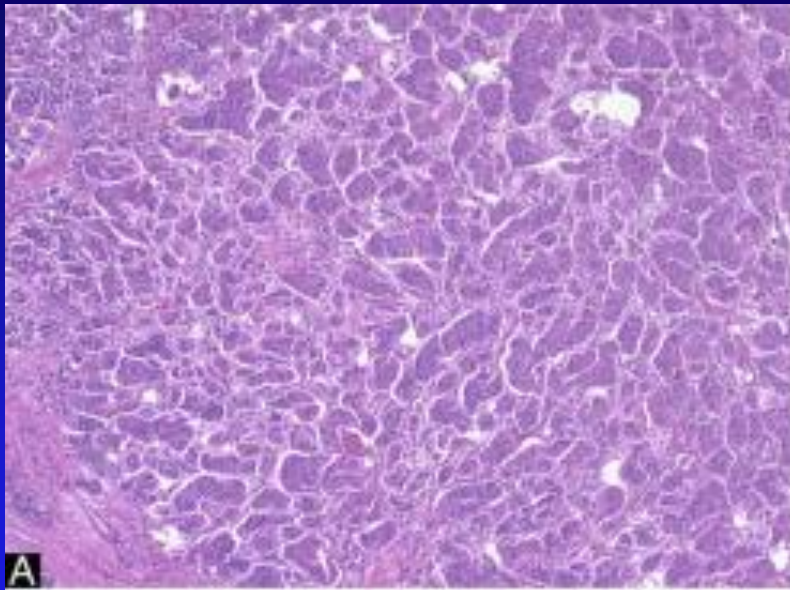
*Amin MB, Ro JY, El-Sharkawy T, et al: Micropapillary variant of transitional cell carcinoma of the urinary bladder: histologic pattern resembling ovarian papillary serous carcinoma. Am J Surg Pathol 18:1233-1239, 1994.*

*Samaratunga H & Khoo K. Micropapillary variant of urothelial carcinoma of the urinary bladder; a clinicopathological and immunohistochemical study. Histopathology. 45:55-64,2004*

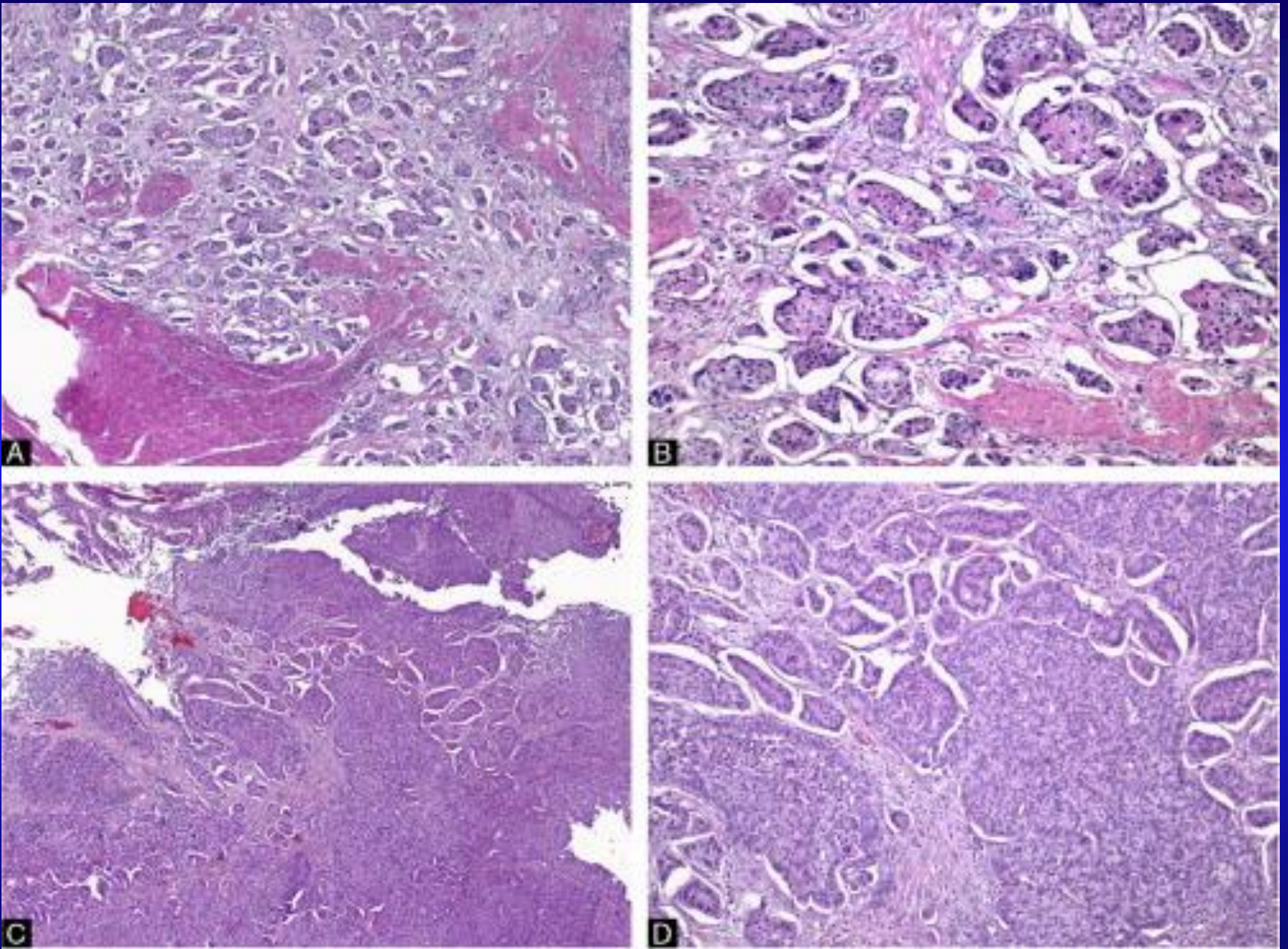
*Kamat AM, Dinney CP, Gee JR, et al: Micropapillary bladder cancer: a review of the University of Texas M. D. Anderson Cancer Center experience with 100 consecutive patients. Cancer 110:62-7,2007*



**Sangoi et al (Am J Surg Pathol. 2010;34:1367-76)**

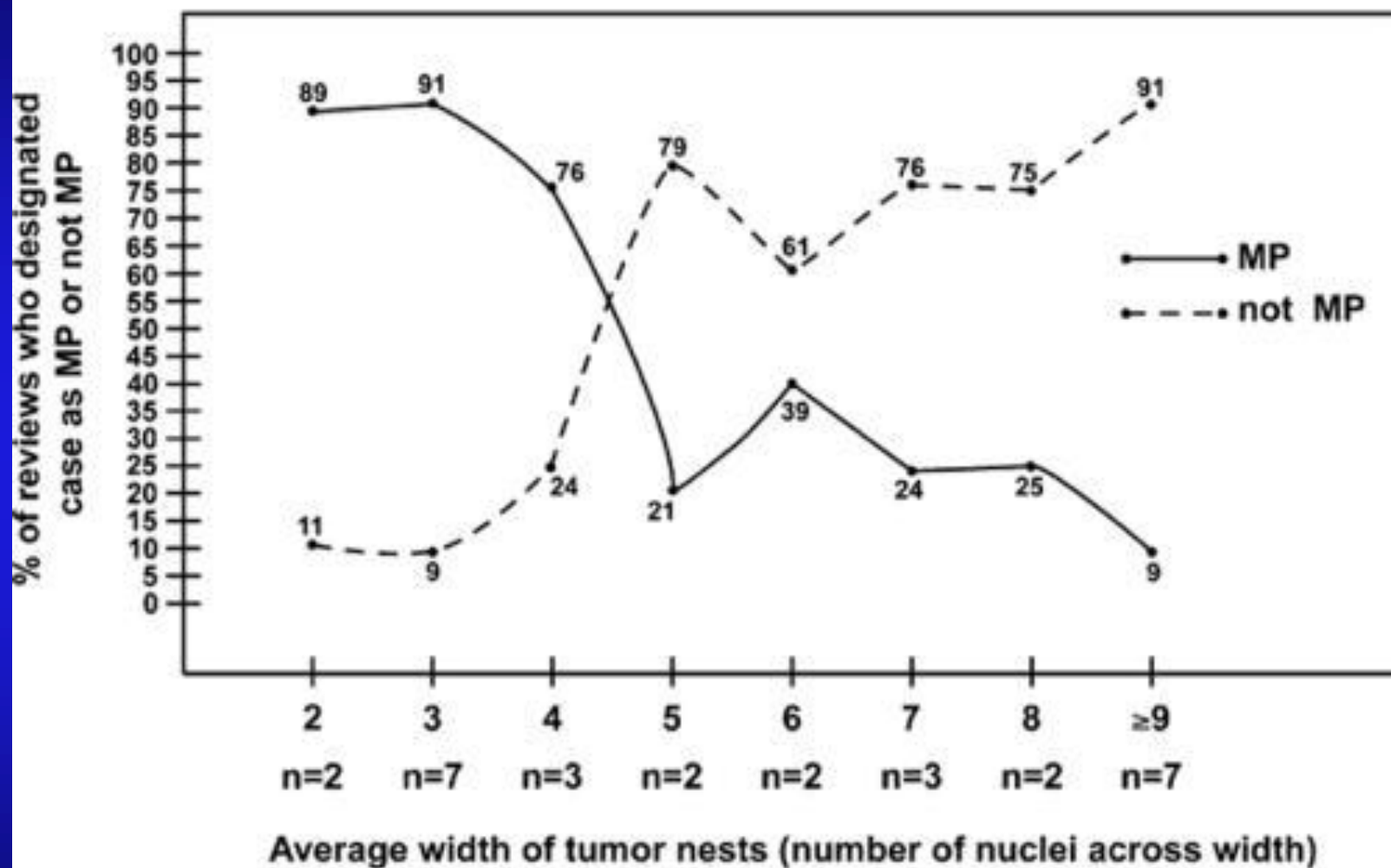


Sangoi et al (Am J Surg Pathol. 2010;34:1367-76)



**Sangoi et al (Am J Surg Pathol. 2010;34:1367-76)**

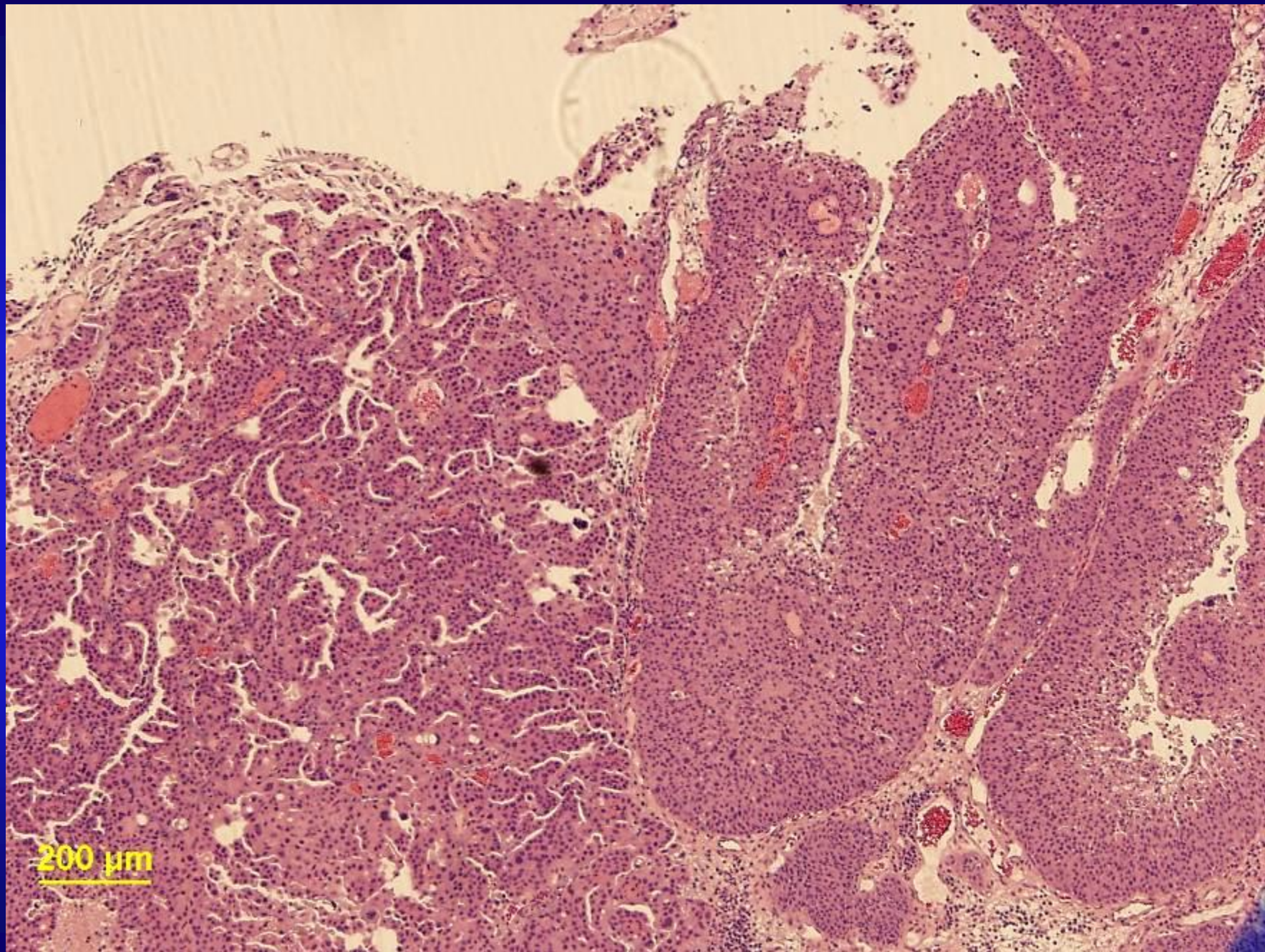
## Diagnosis by Tumor Nest Width



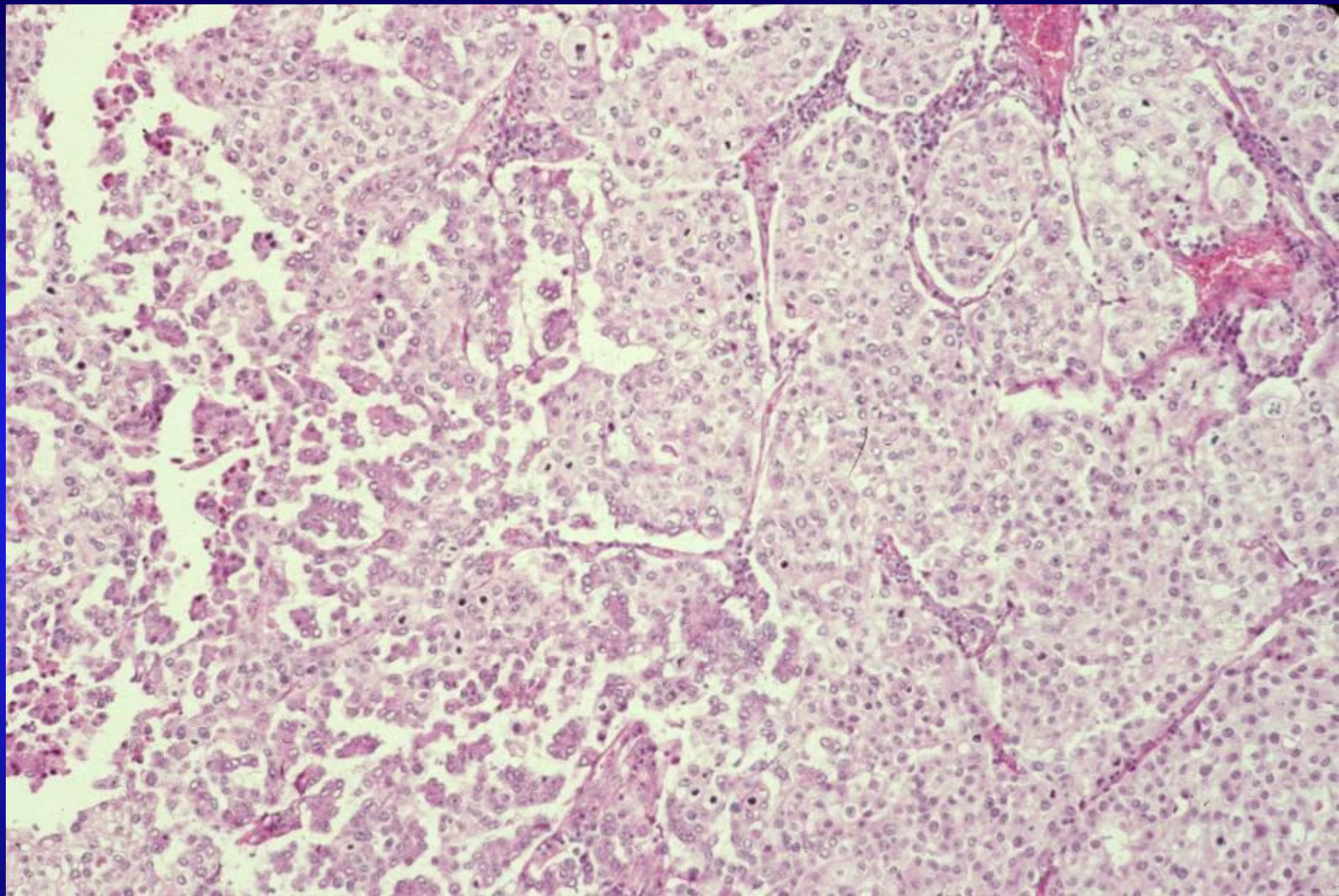
\* n=28 cases; 2 cases were not characterized by nests

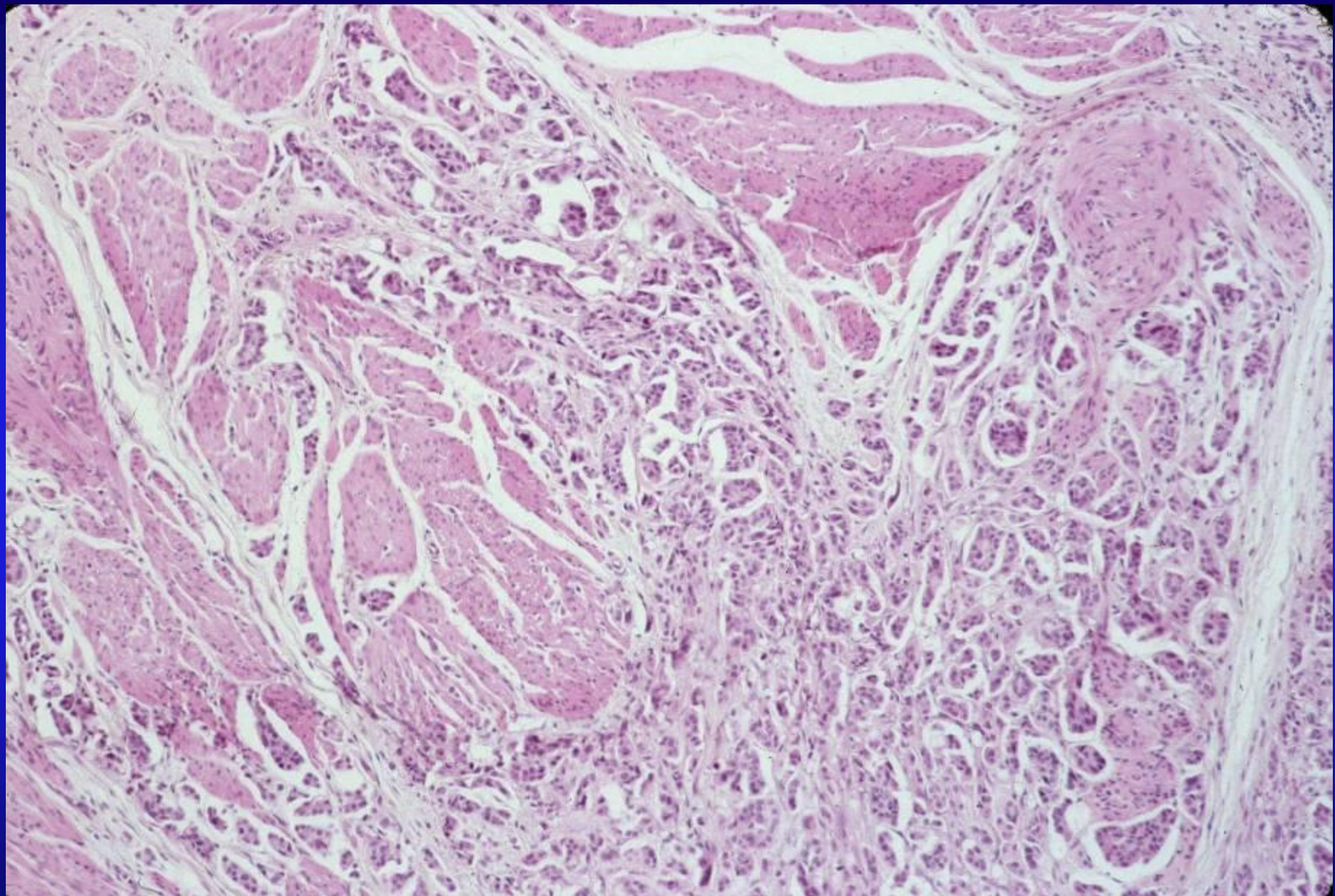
# Variants of TCC

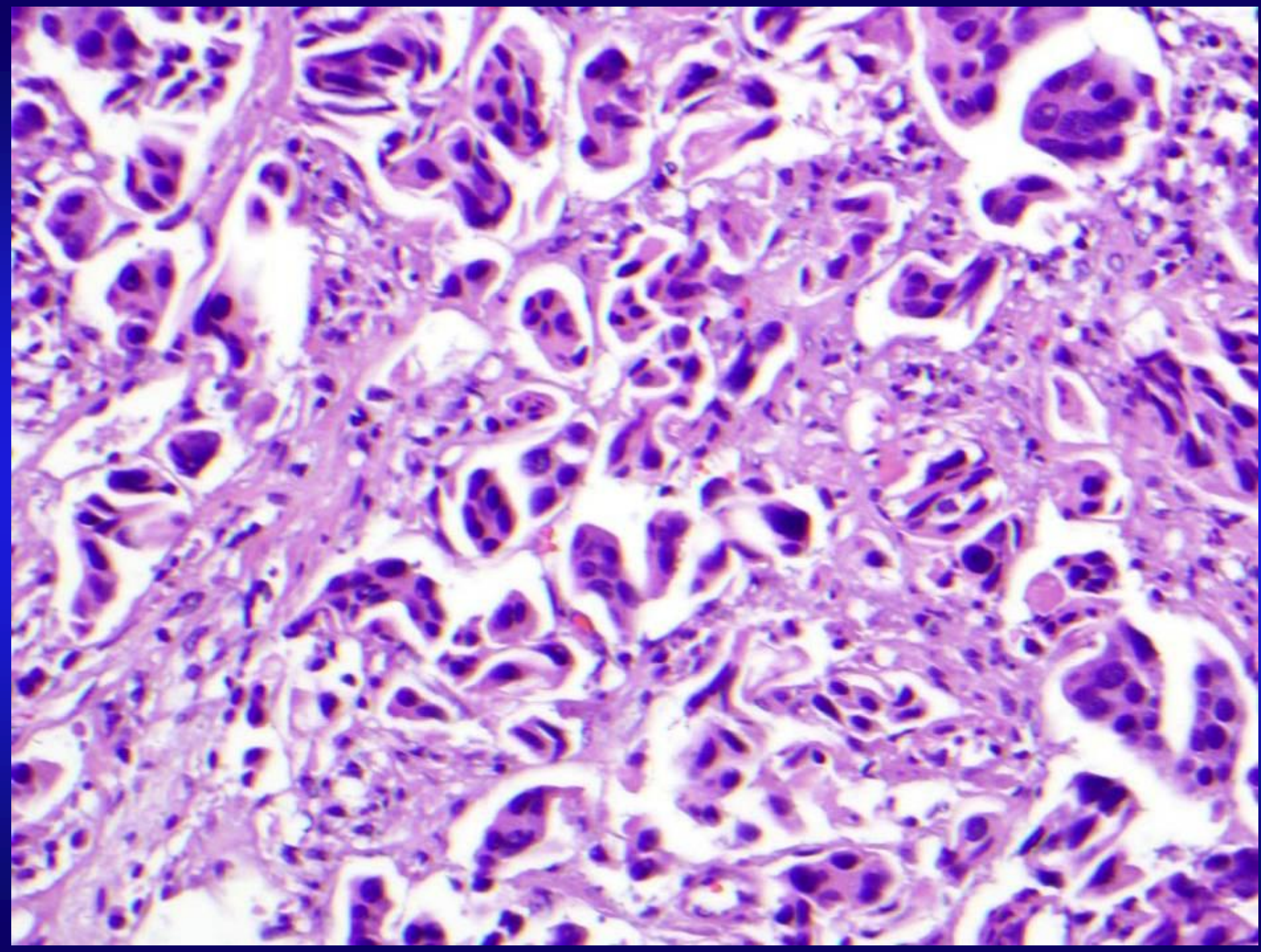
- TCC with squamous, glandular, trophoblastic diff
- micropapillary TCC
- deceptively benign features: nested pattern (von Brunn's nests appearing), small tubular pattern, microcystic pattern, inverted pattern
- sarcomatoid TCC
- plasmacytoid and clear cell TCC
- small cell ca and LELC
- Giant cell and undifferentiated

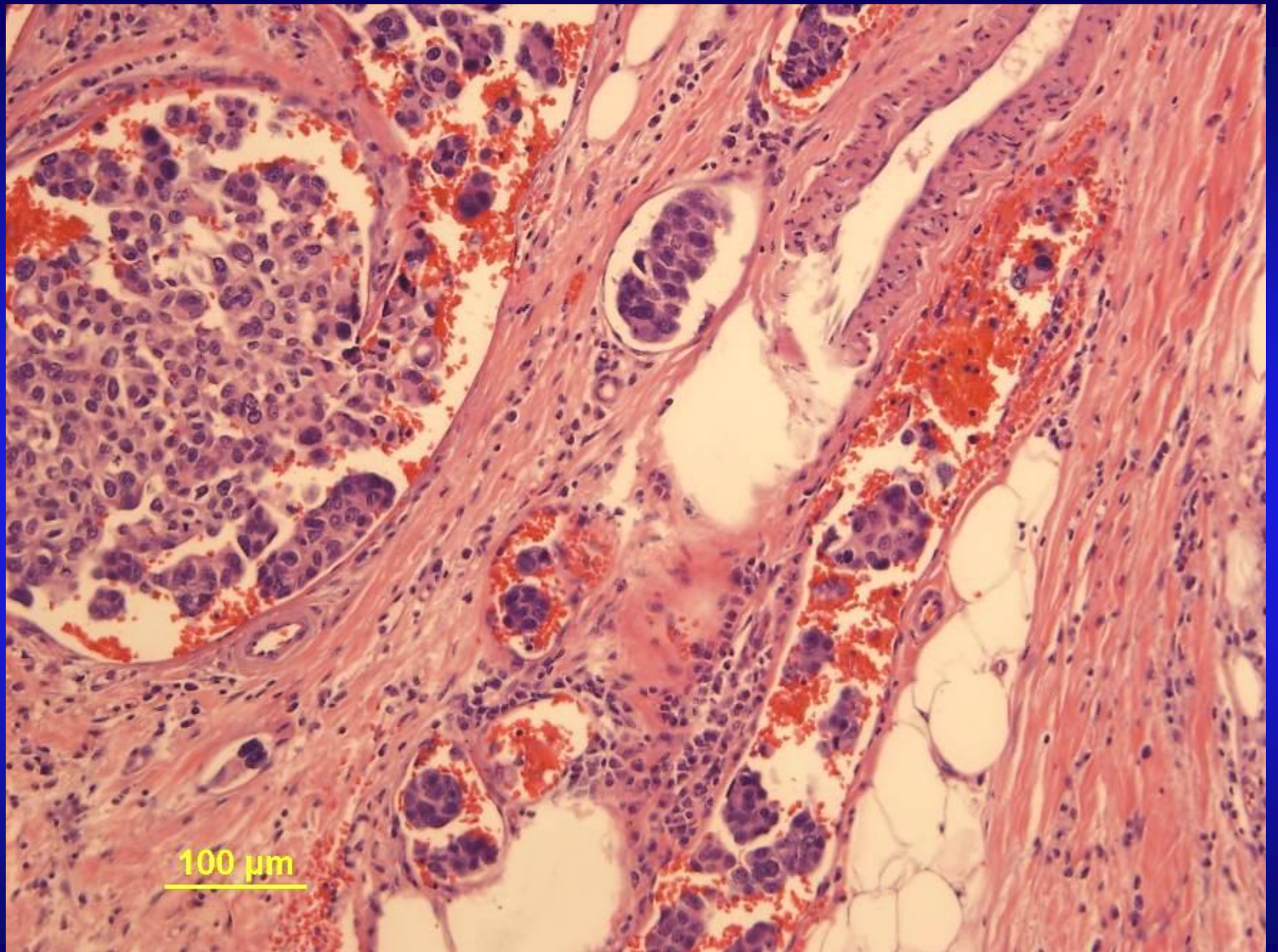


200  $\mu$ m

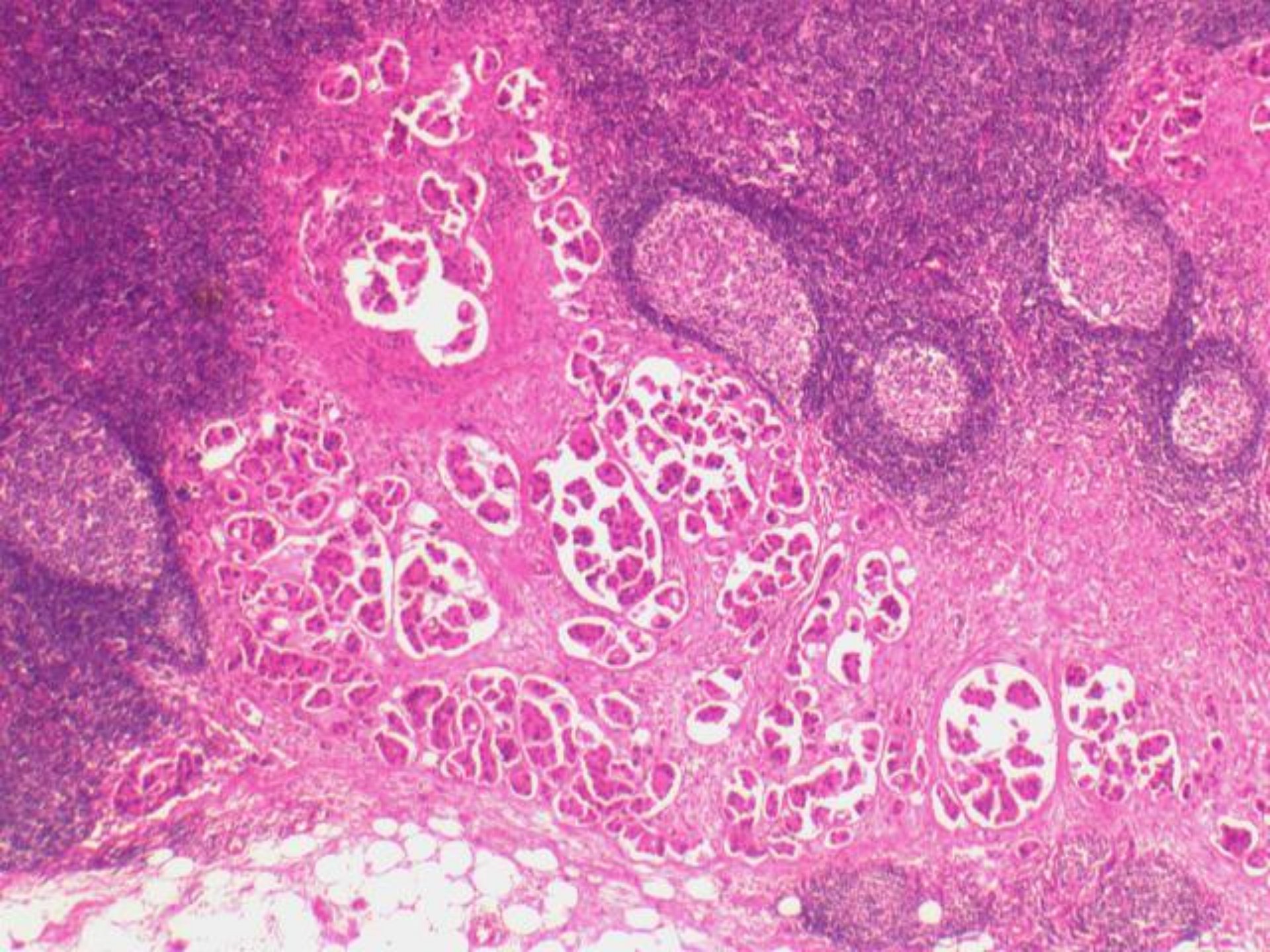


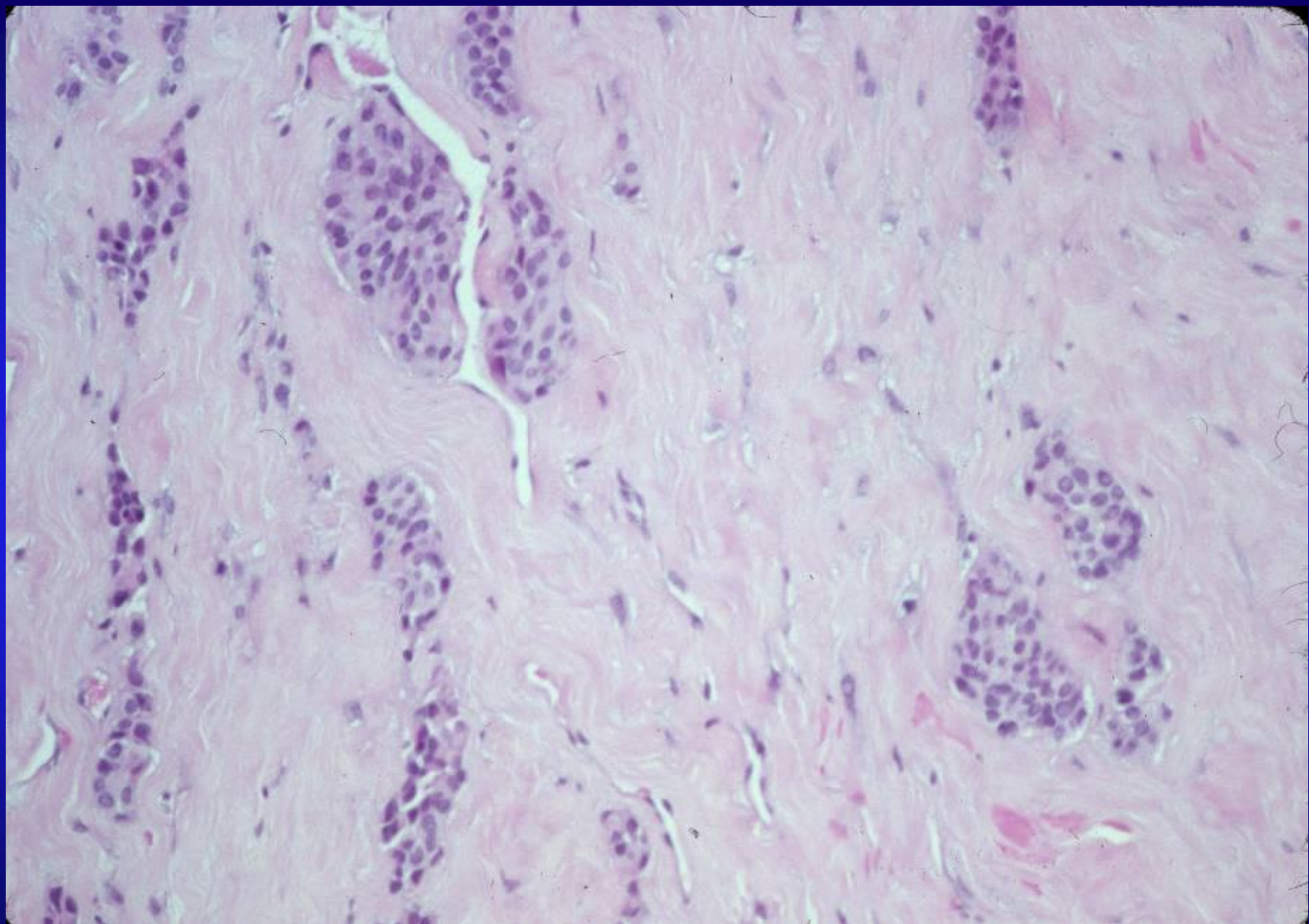


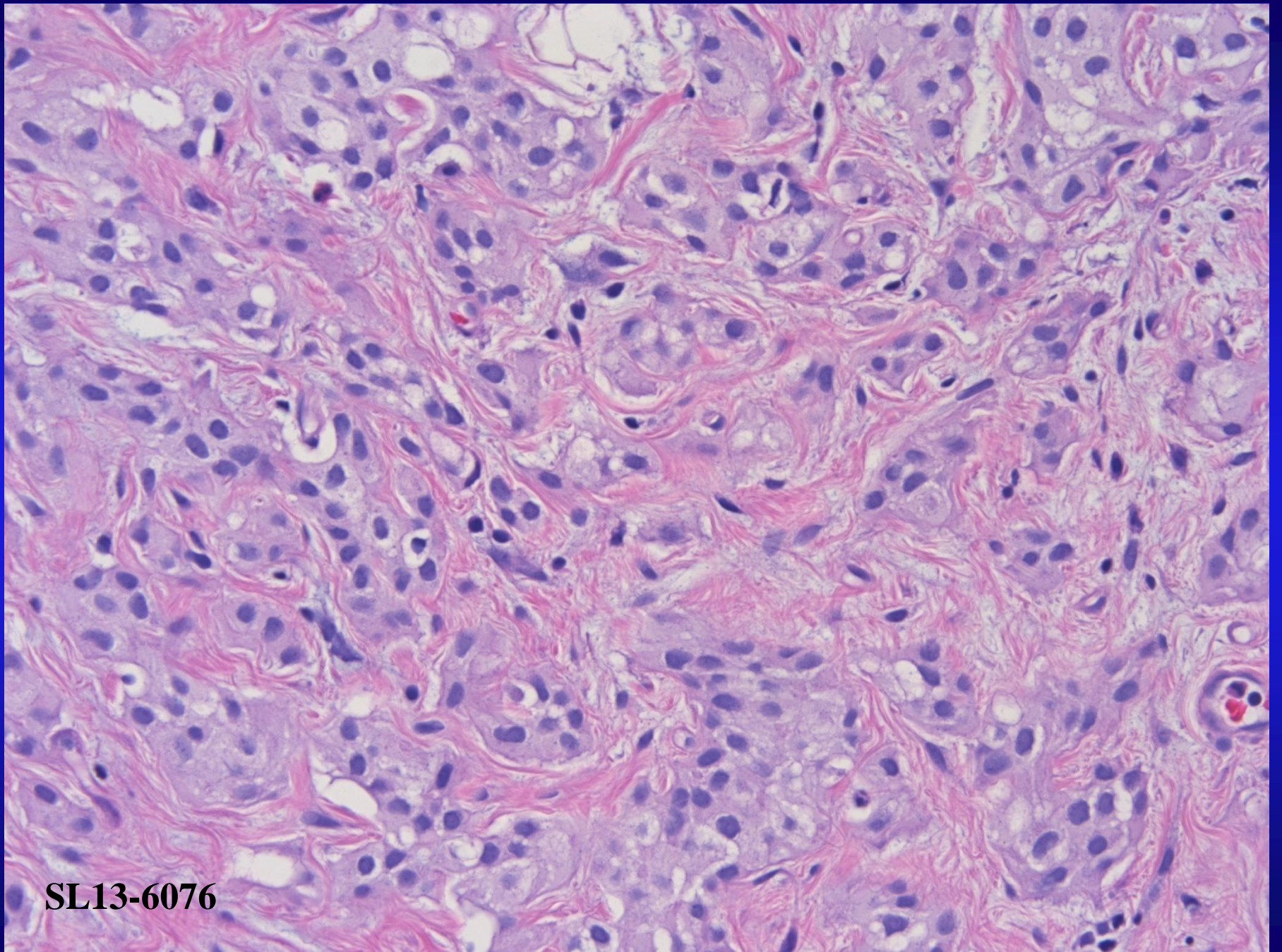




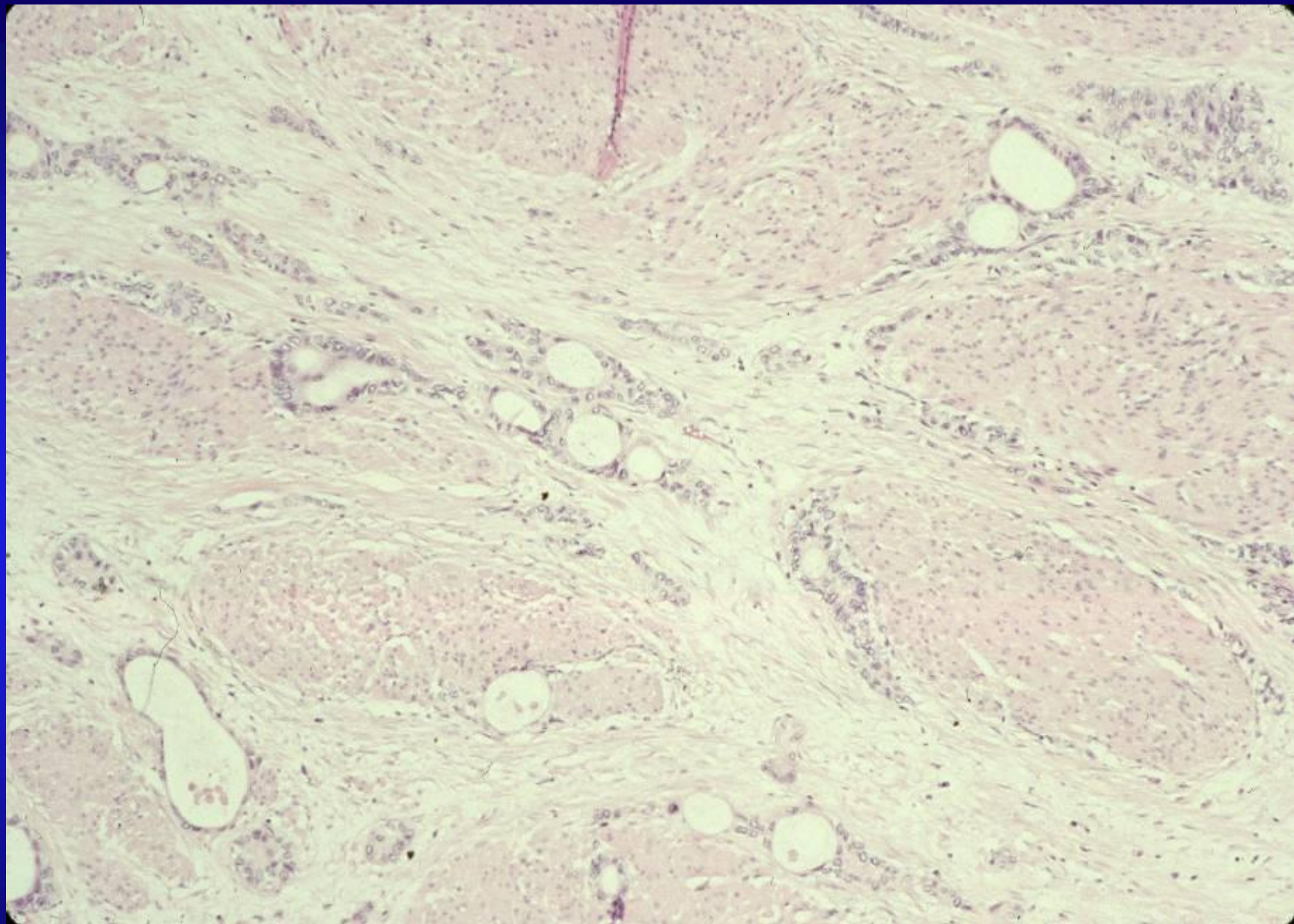
100 μm

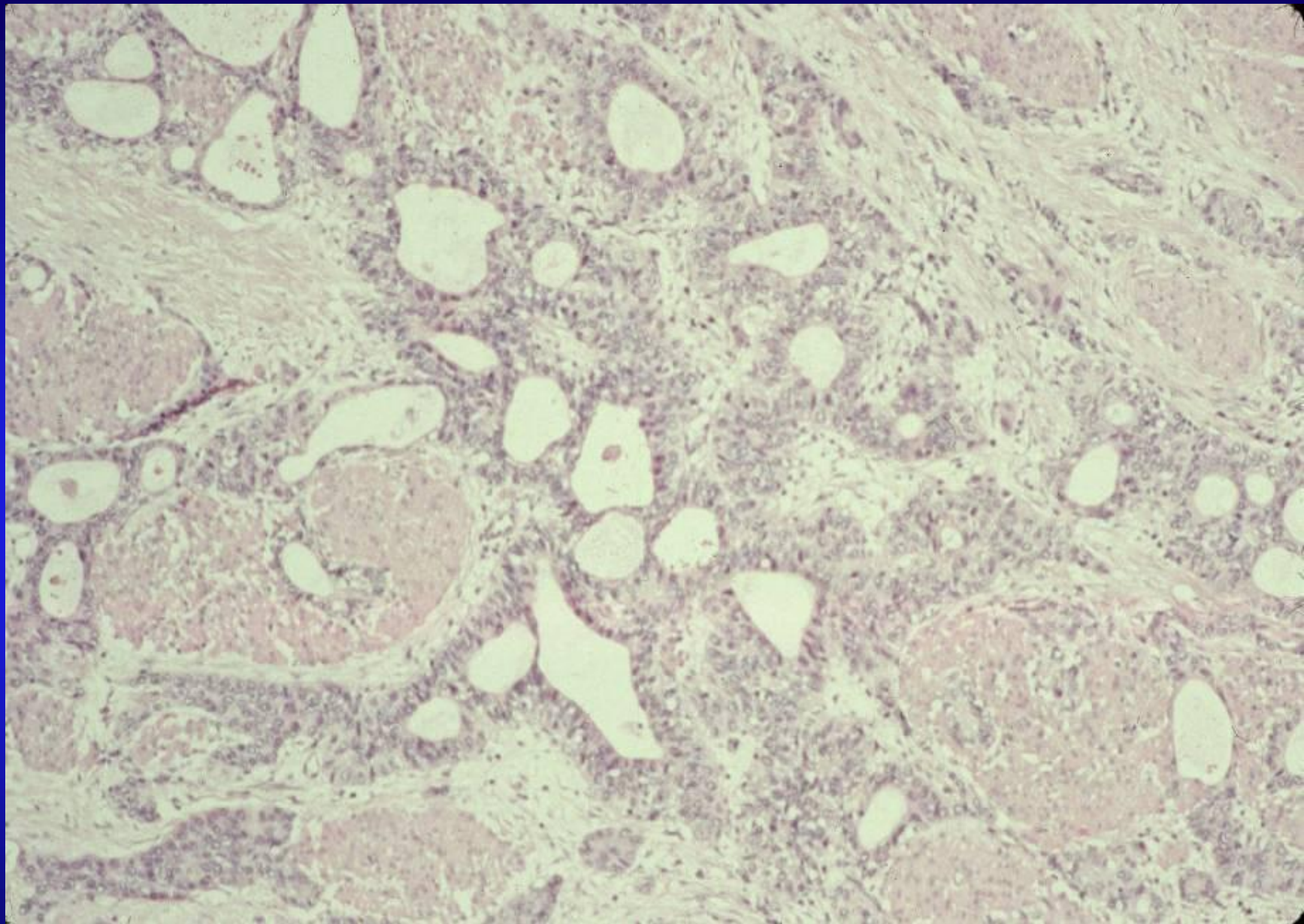


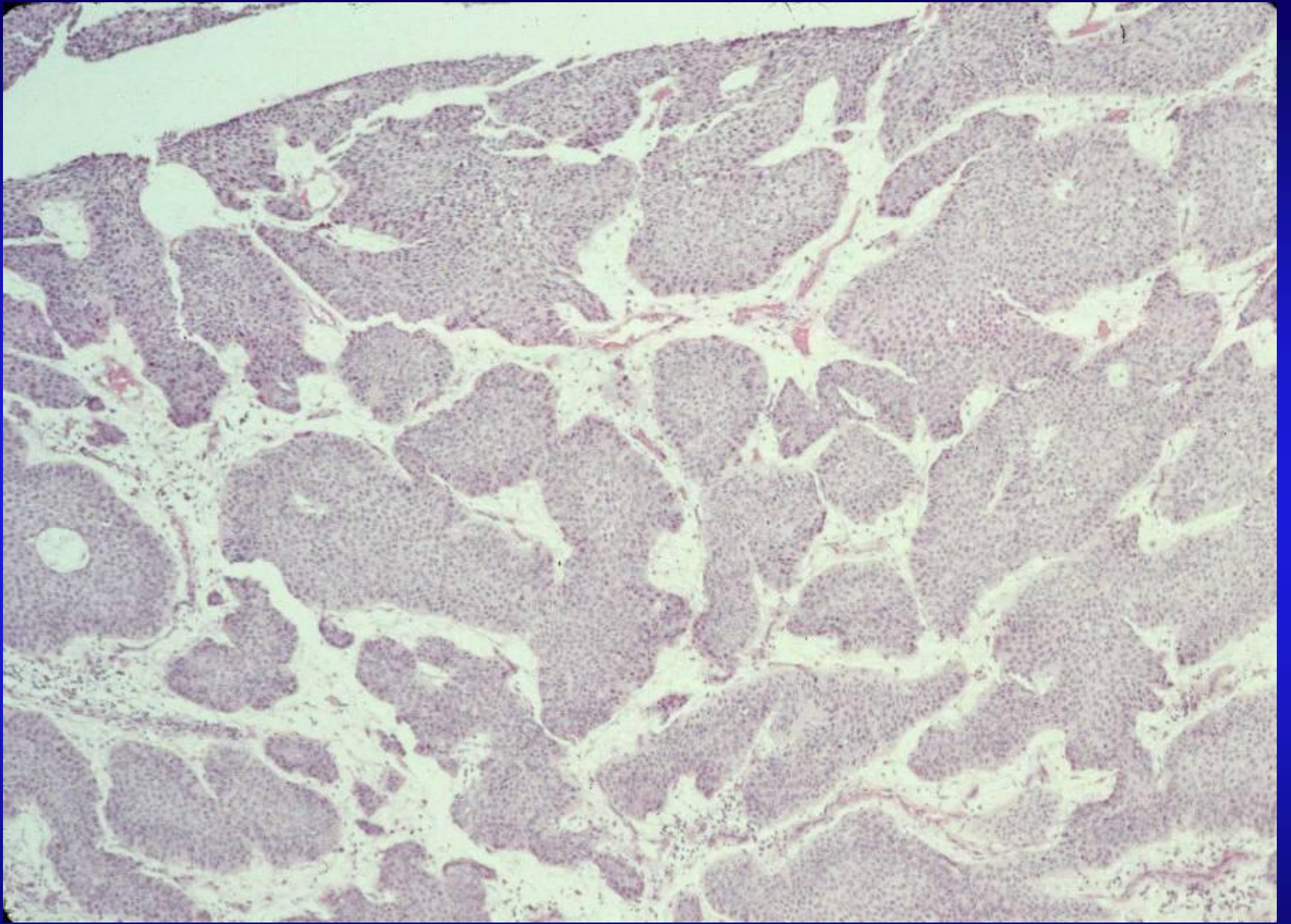


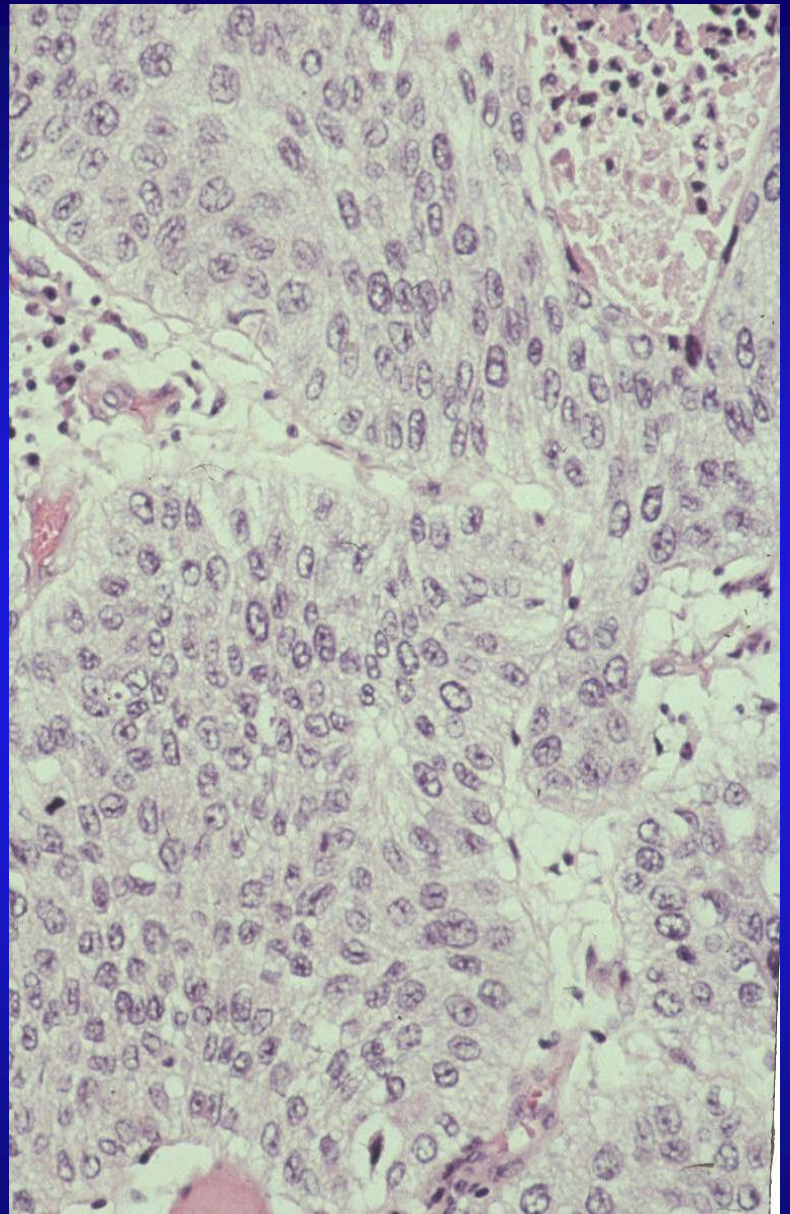
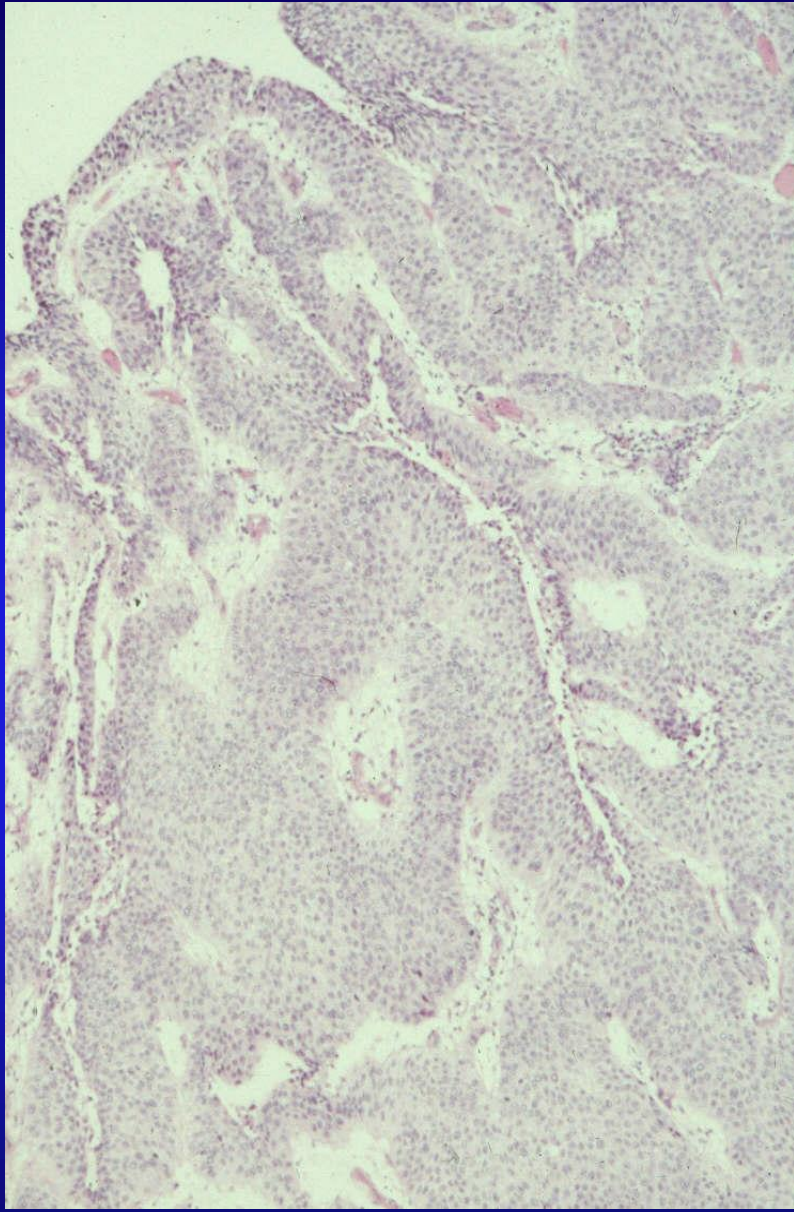


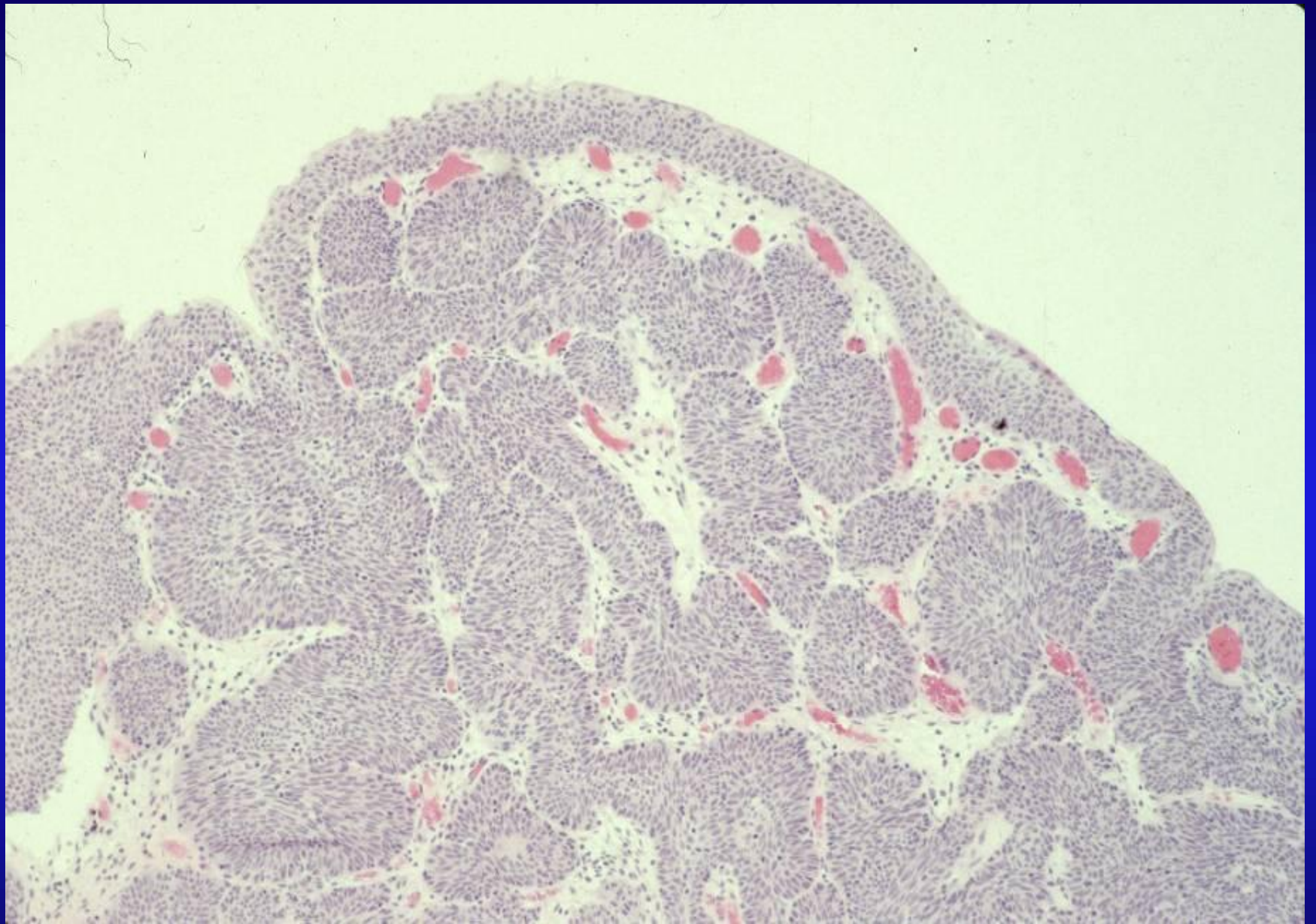
**SL13-6076**

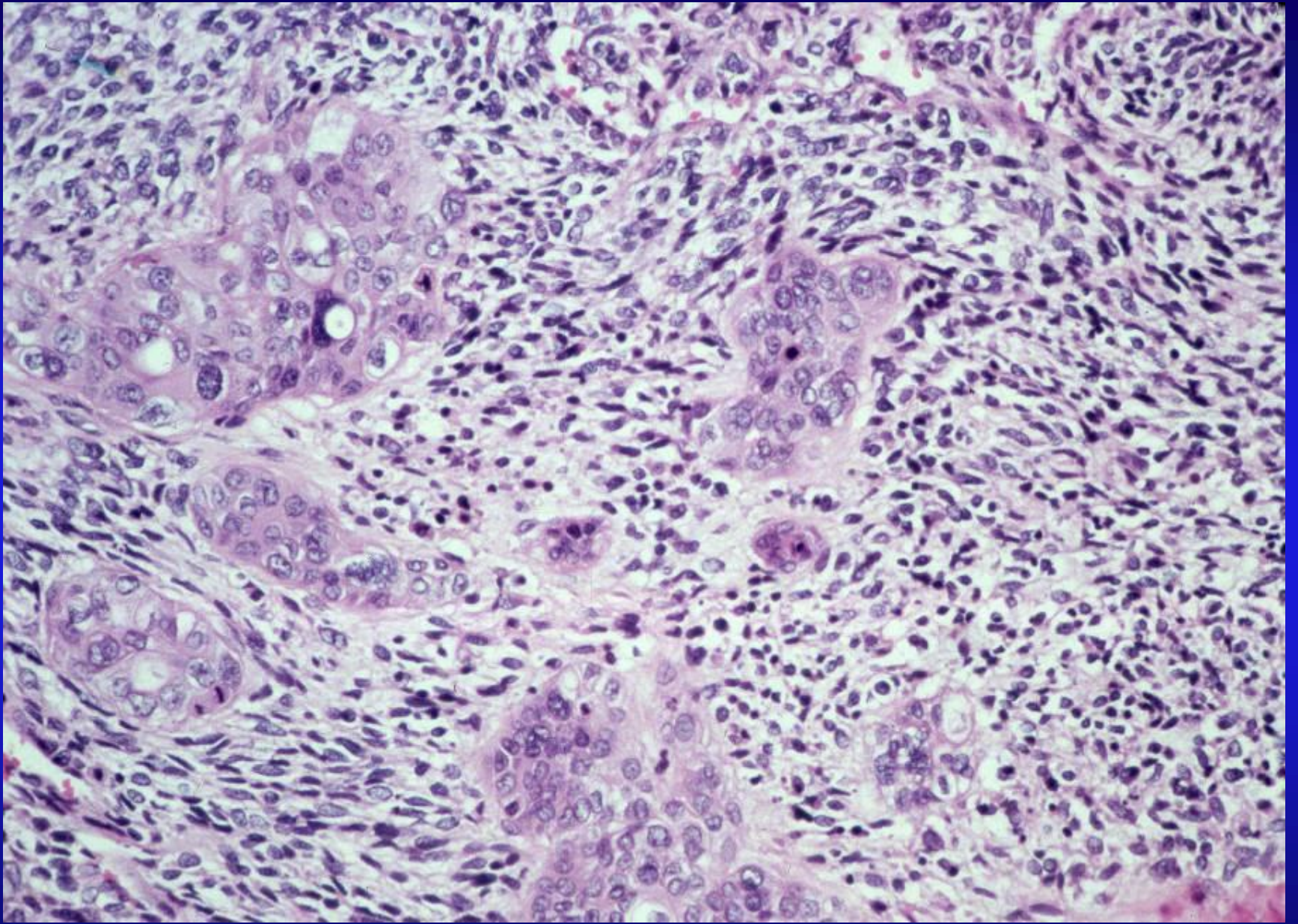


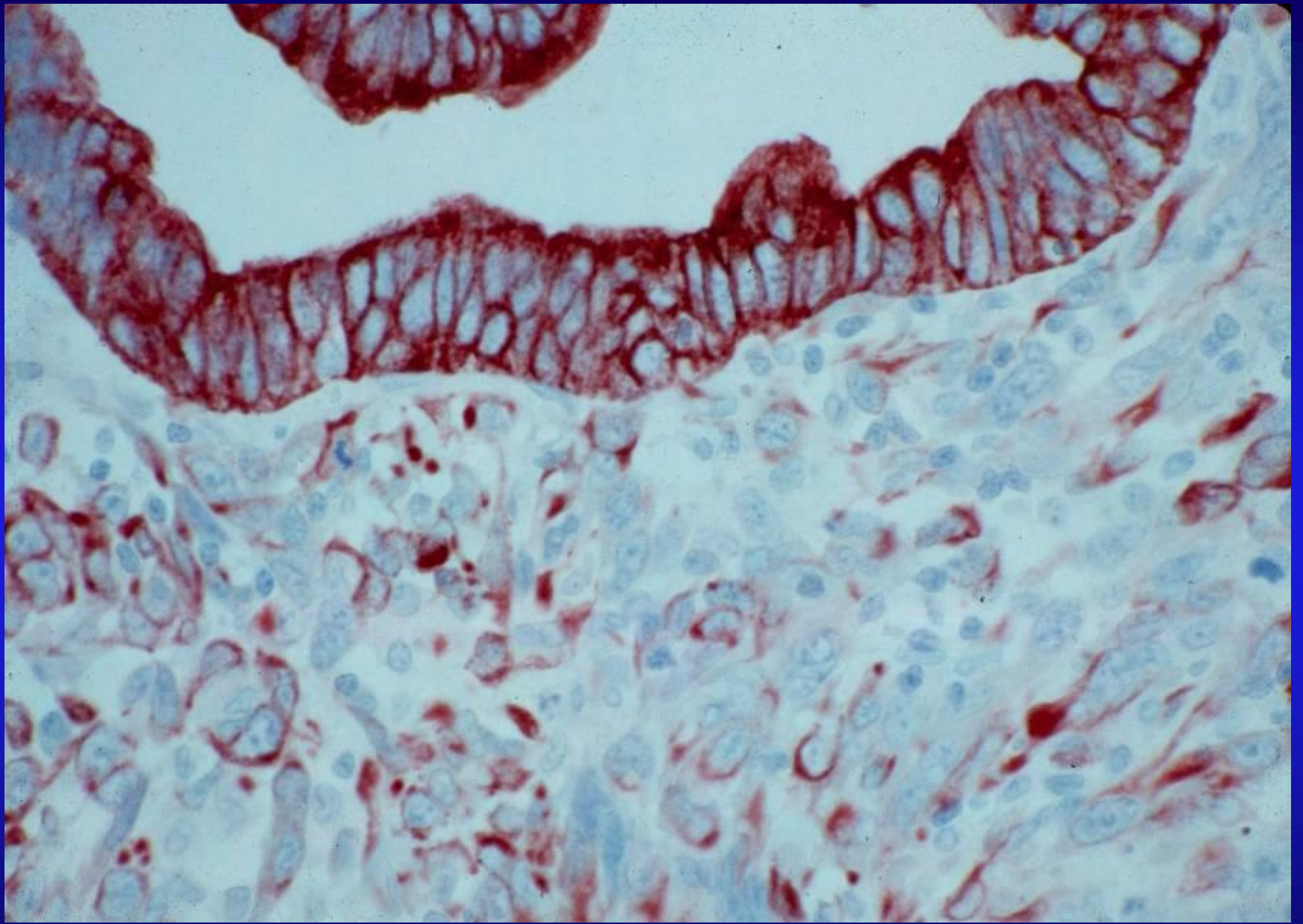


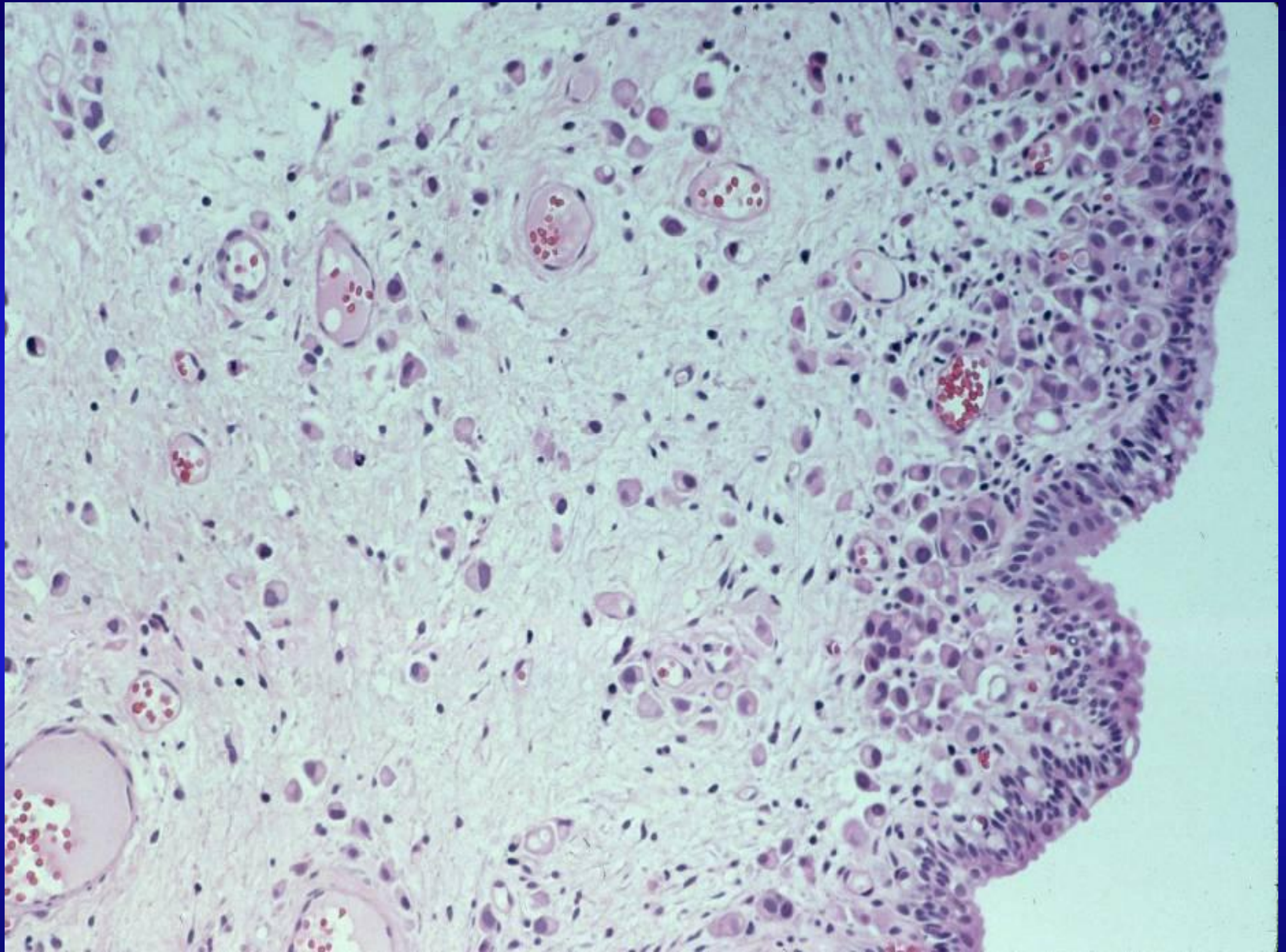




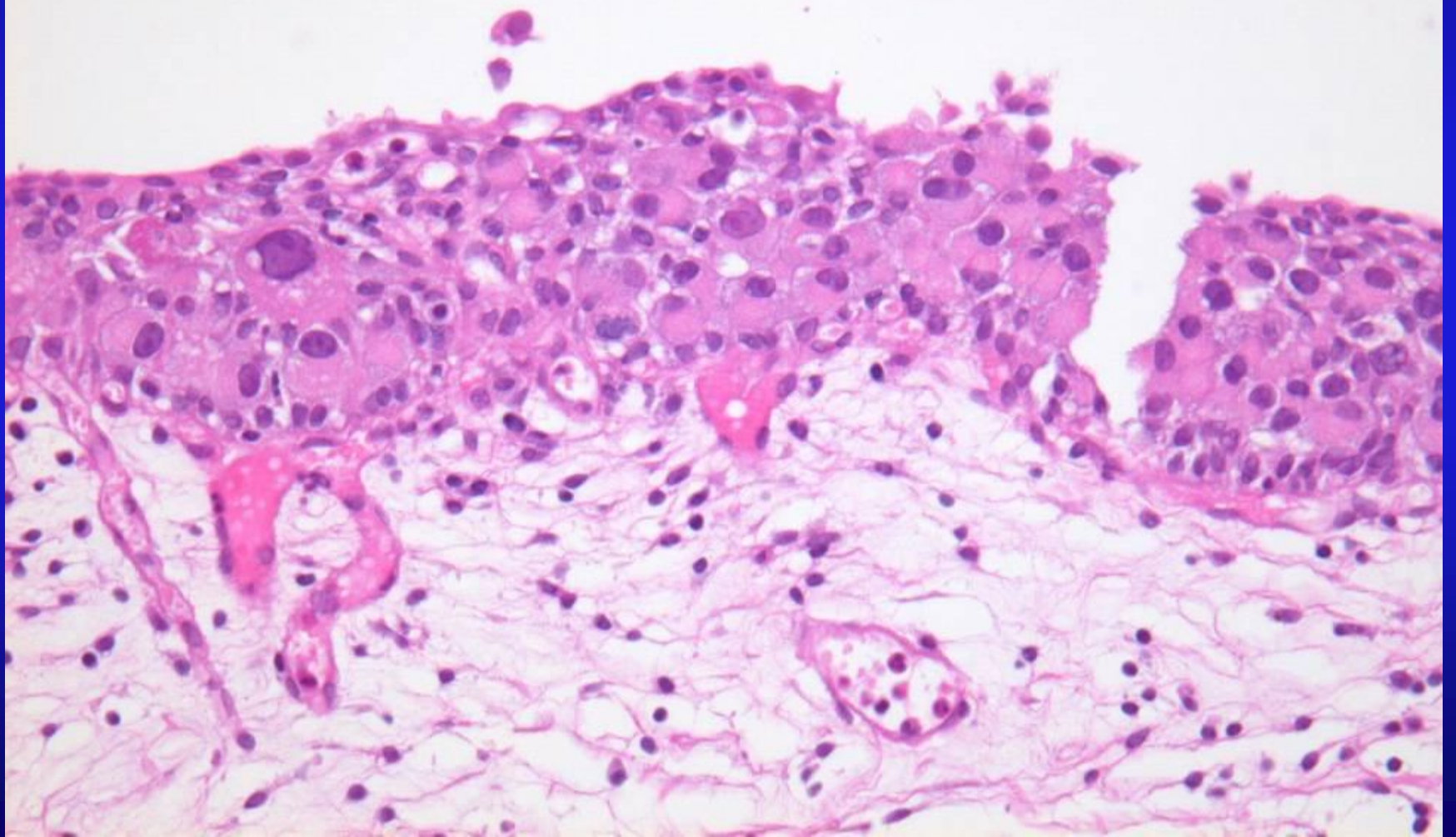


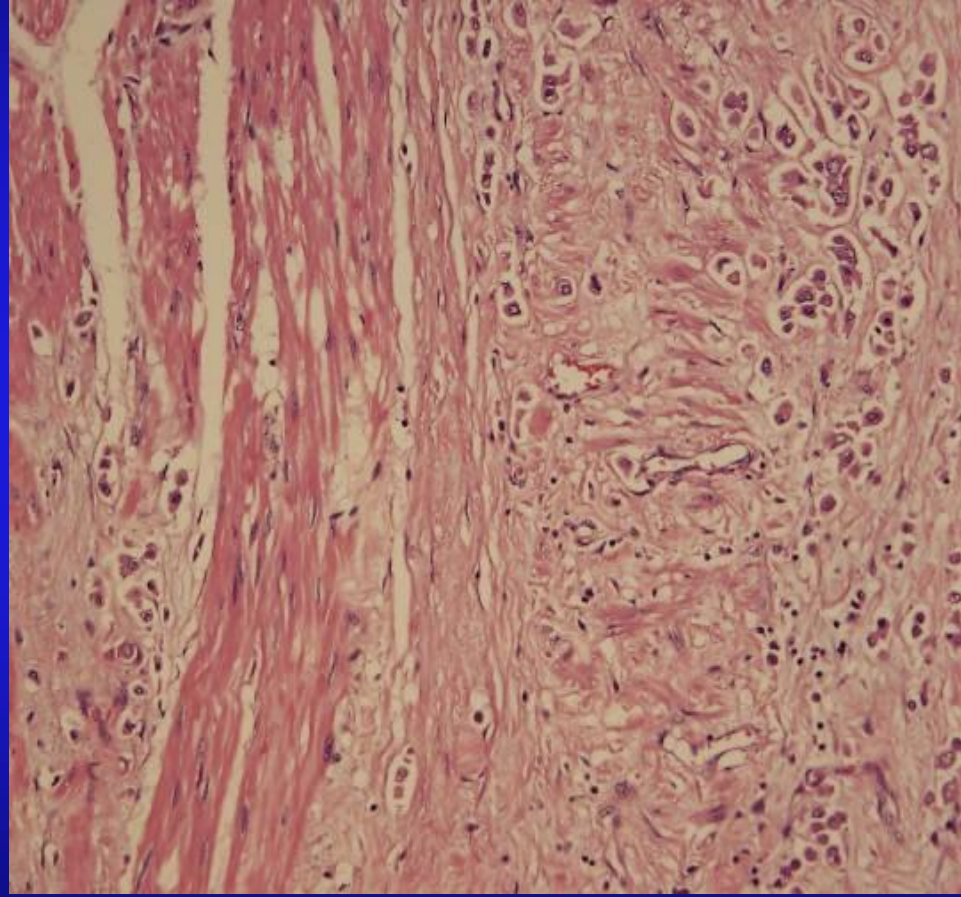
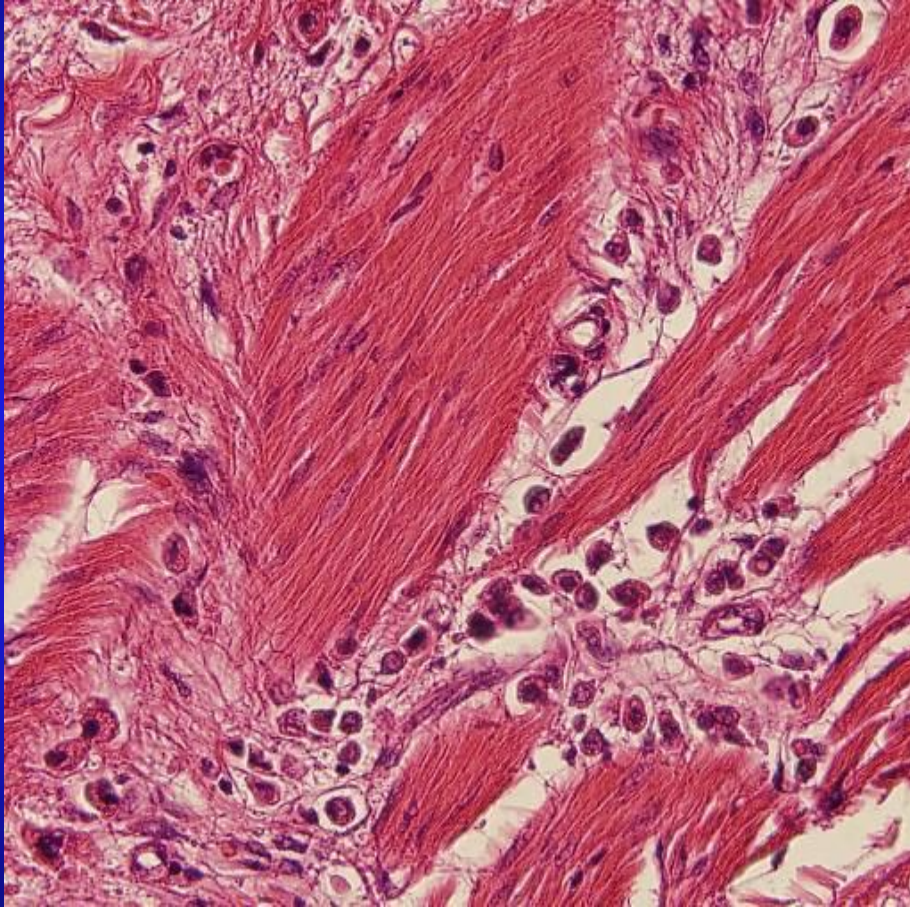


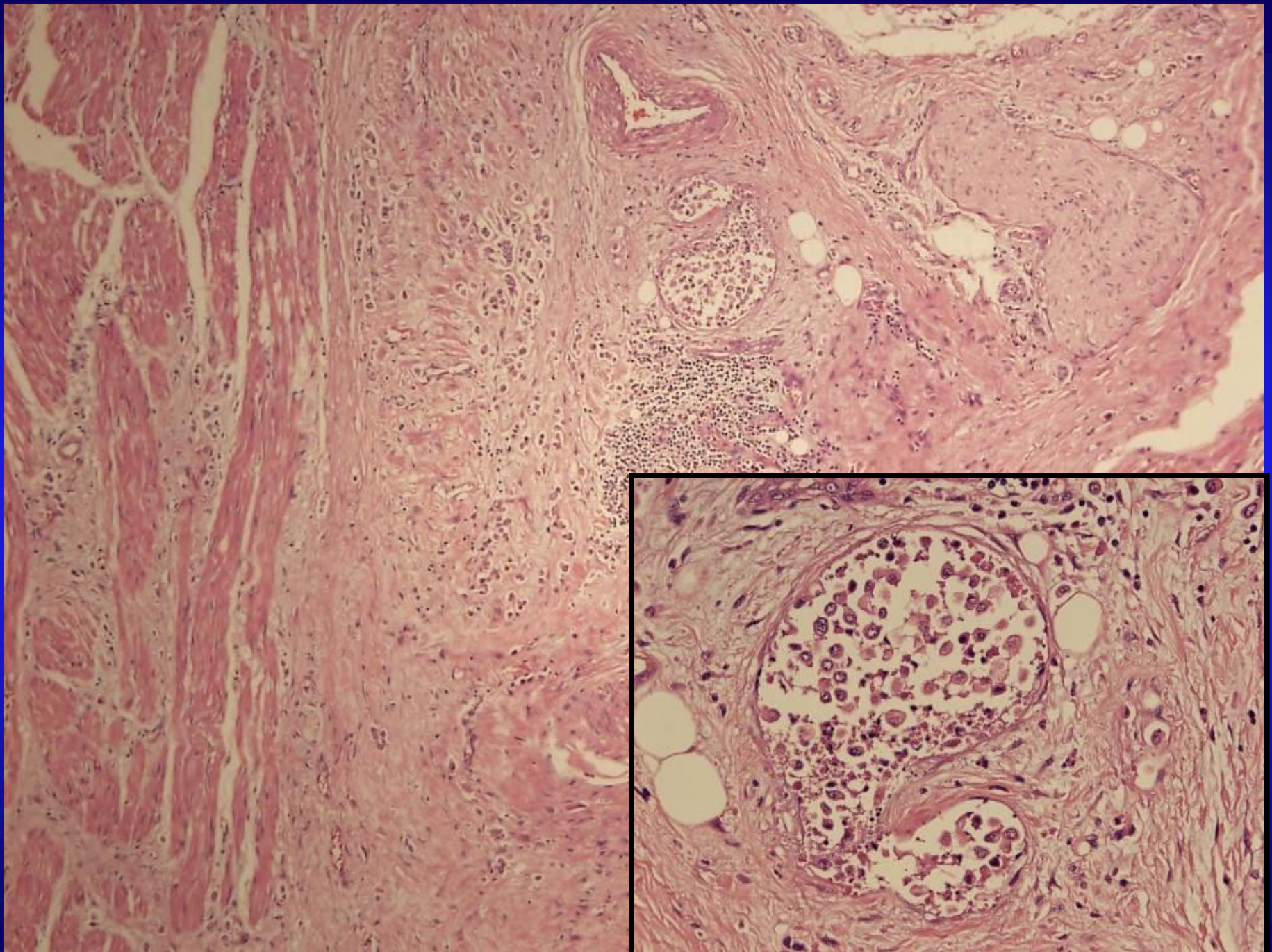




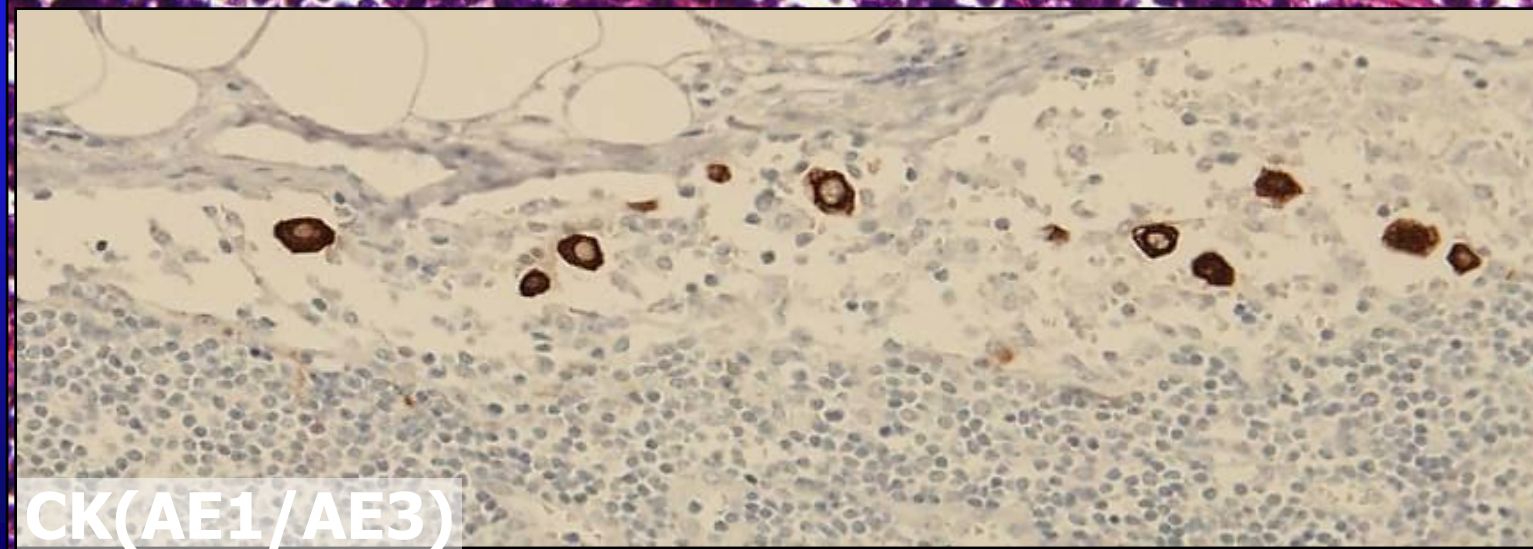
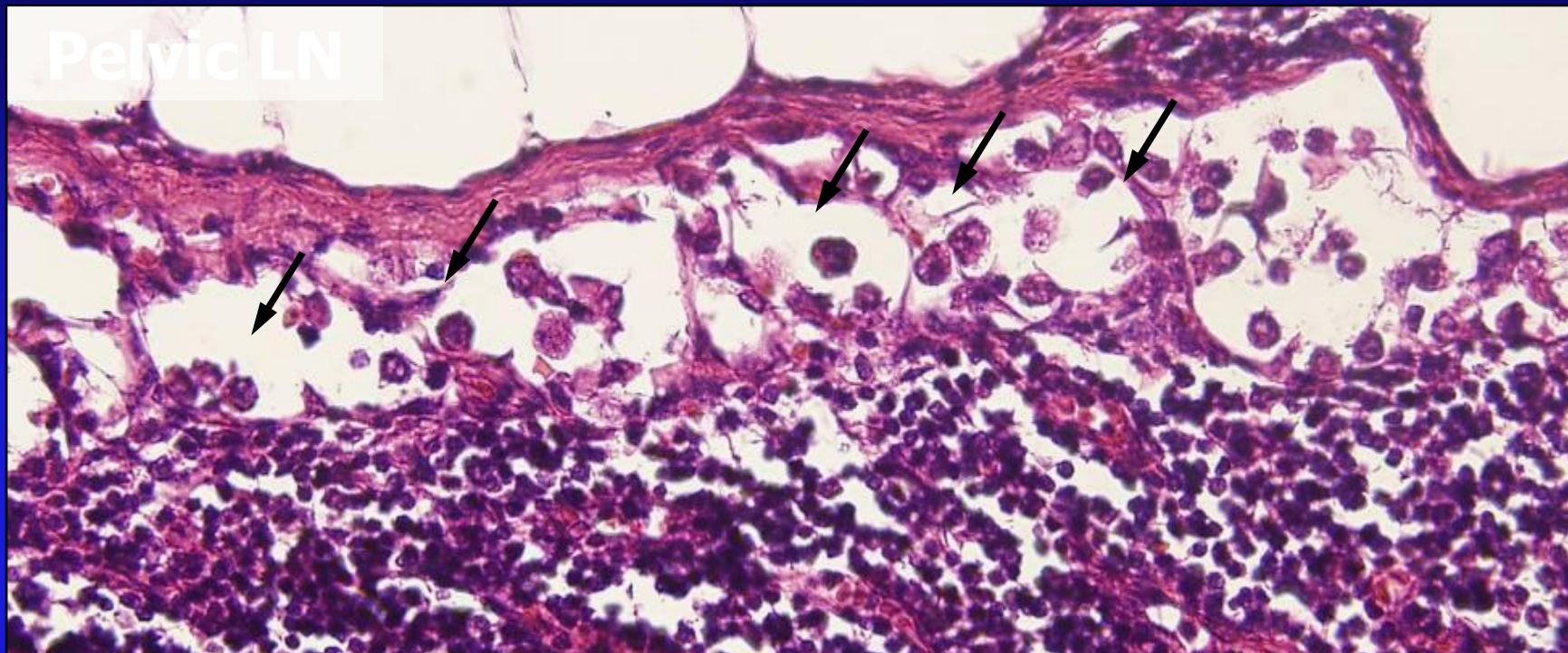
**AJSP, 2008**



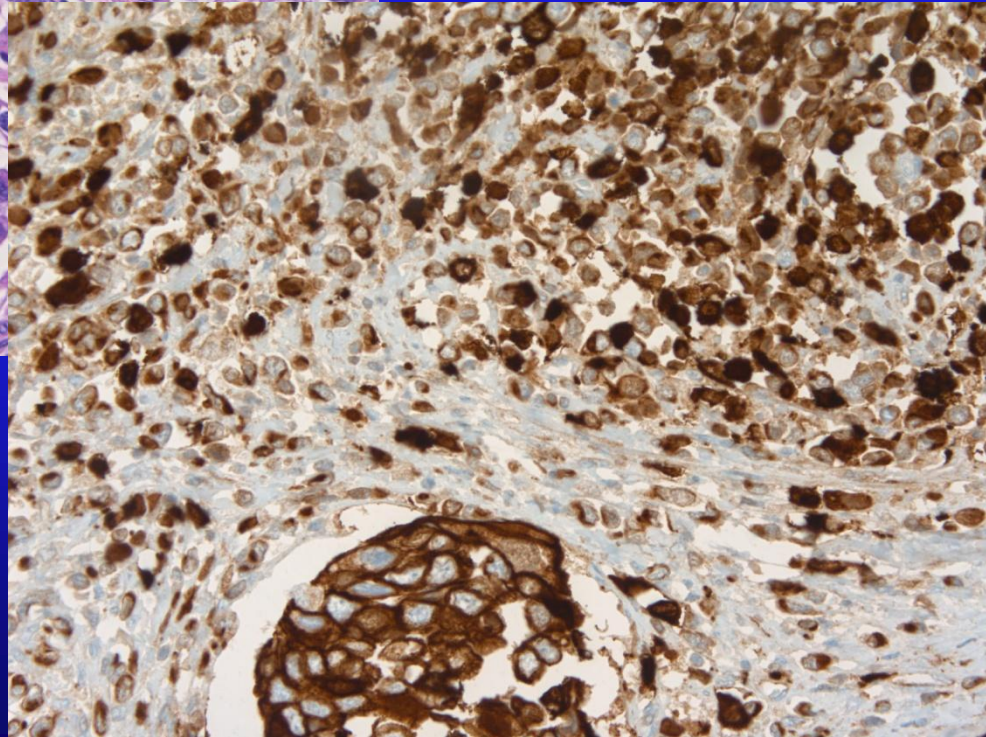
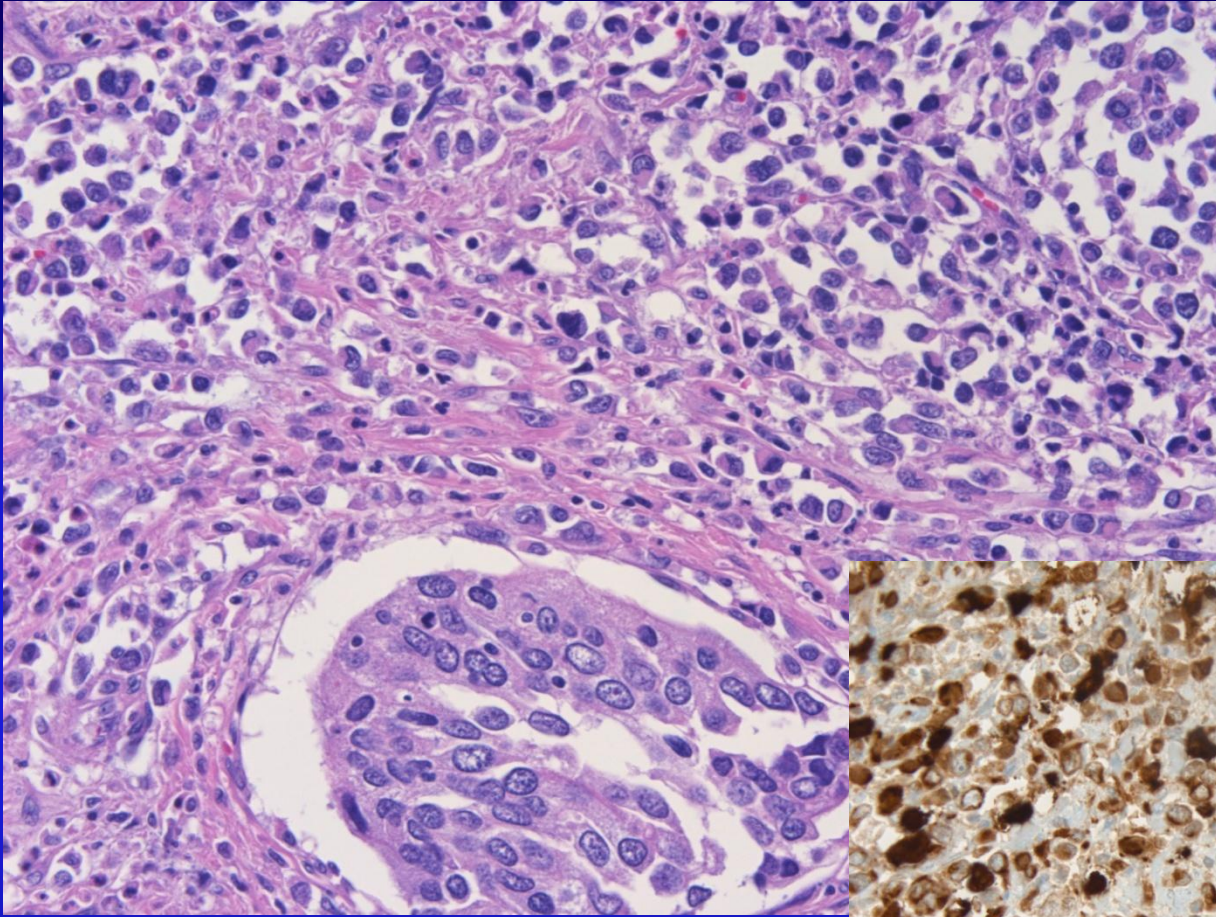




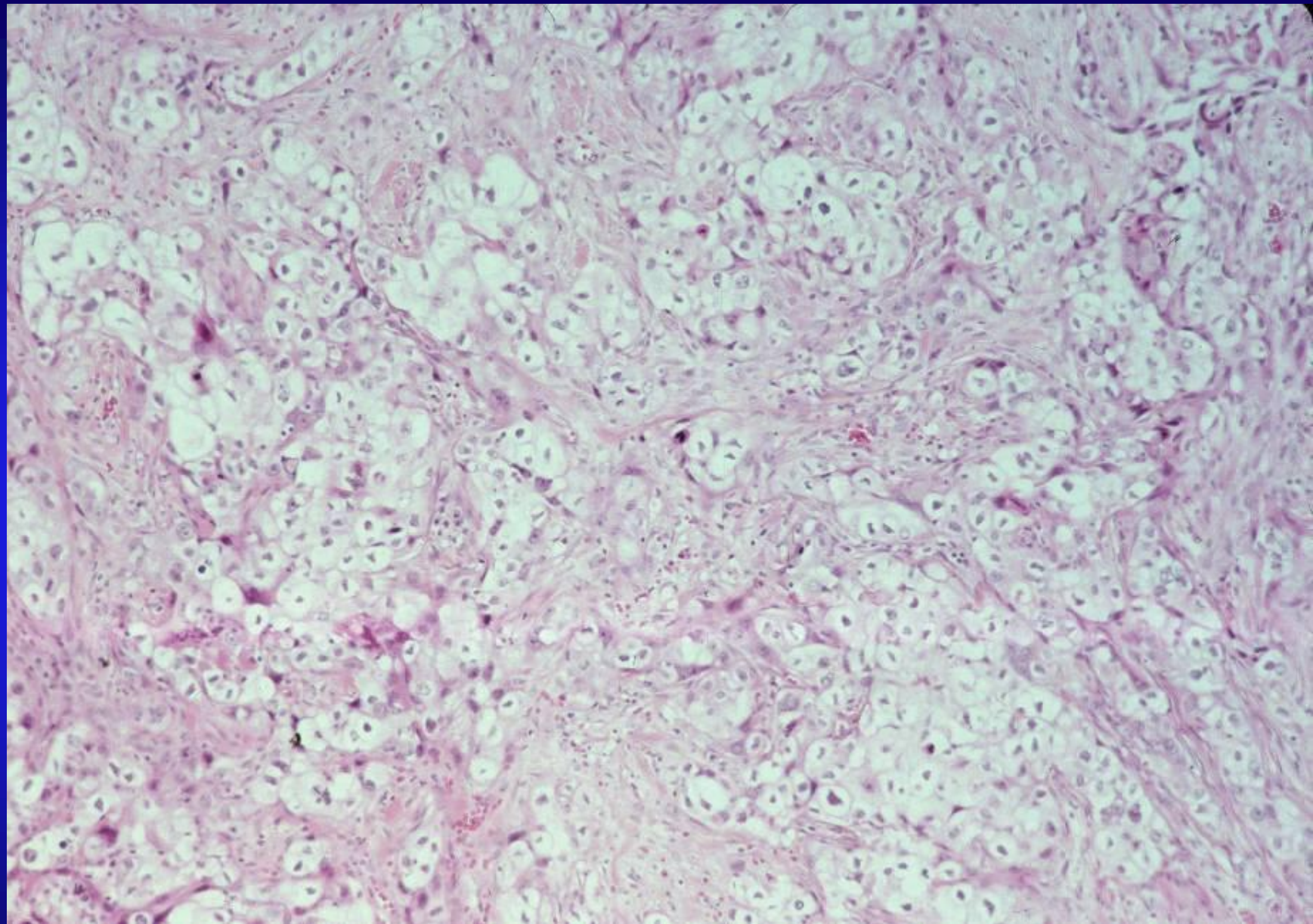
Pelvic LN

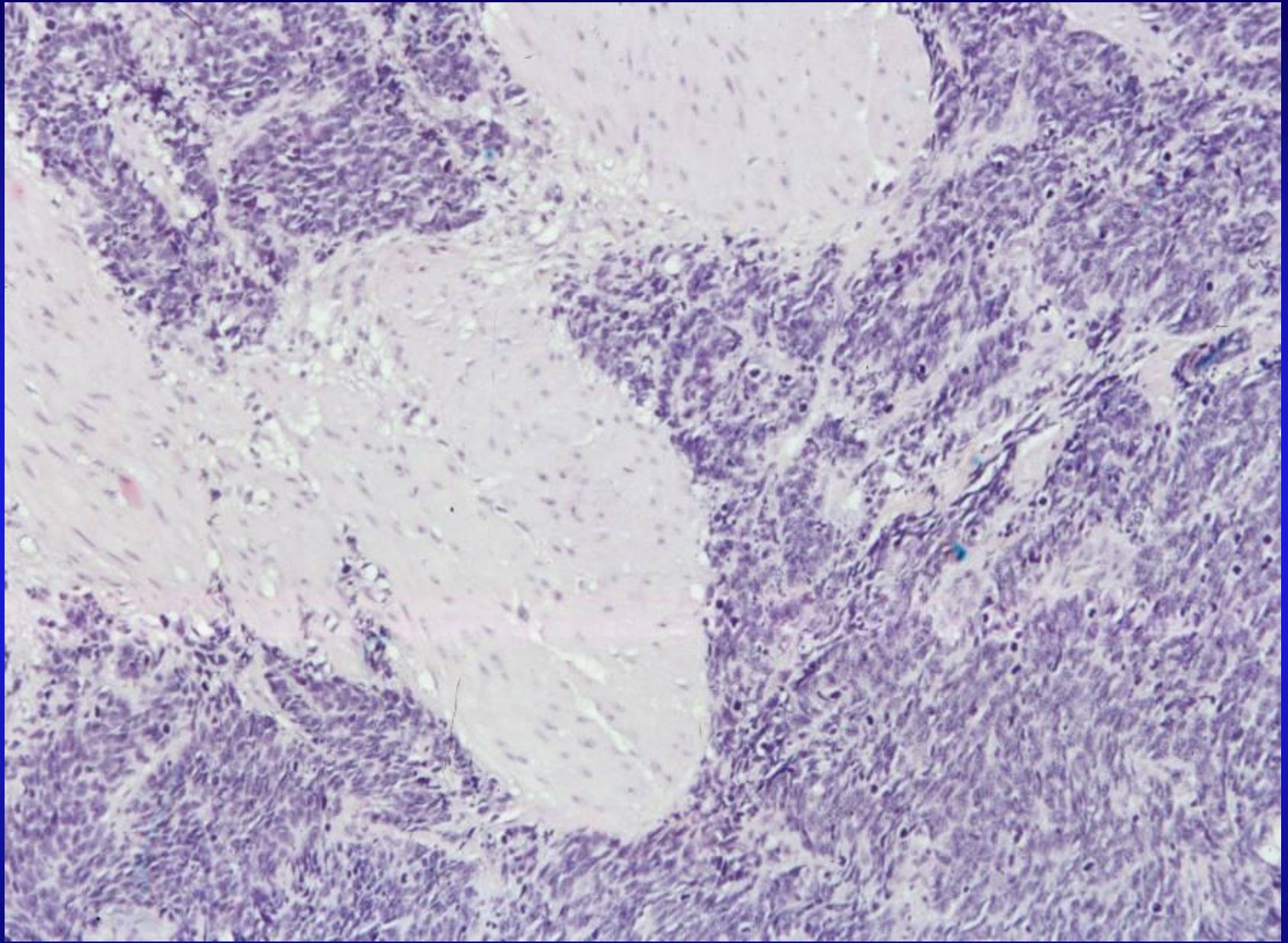


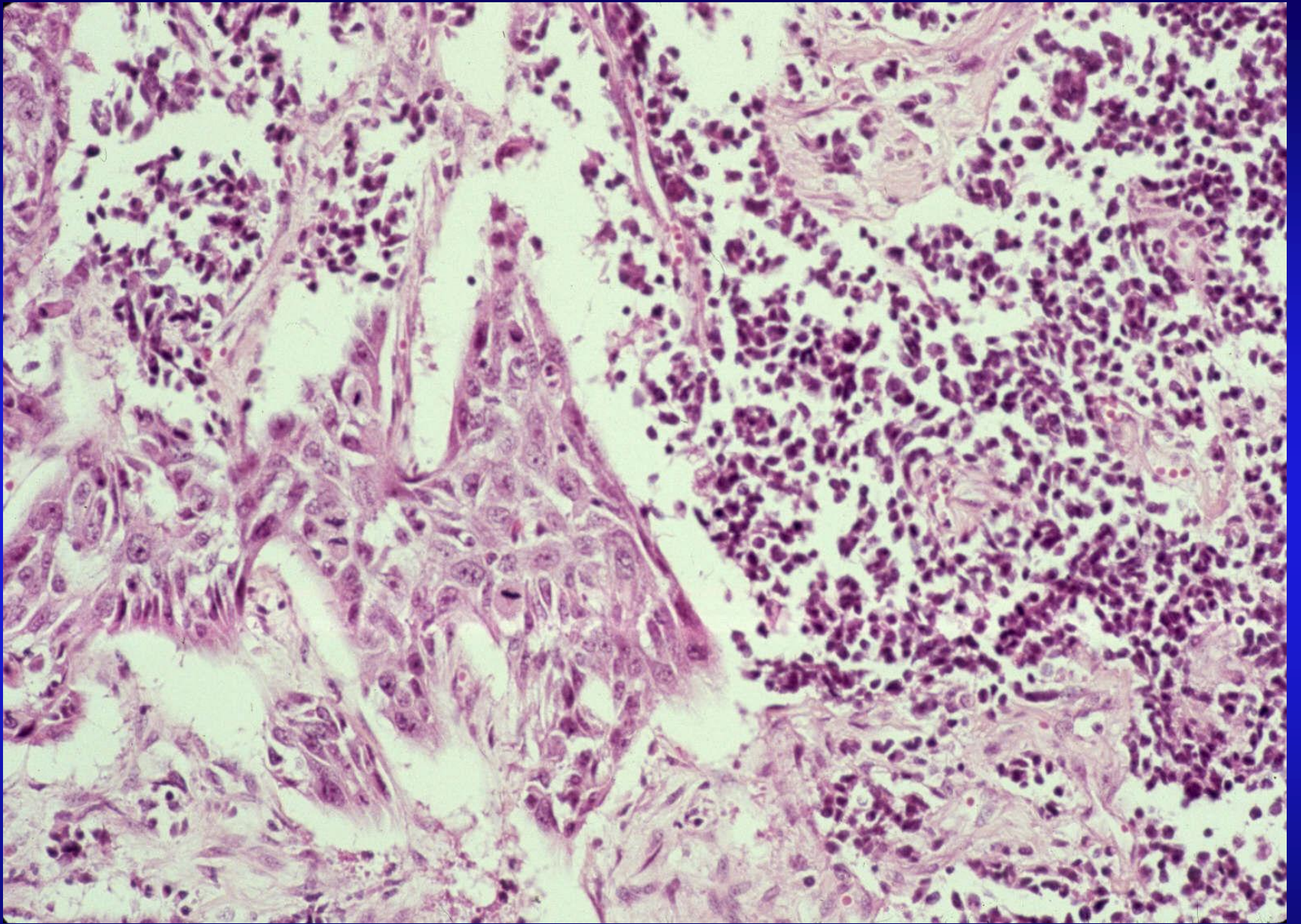
CK(AE1/AE3)

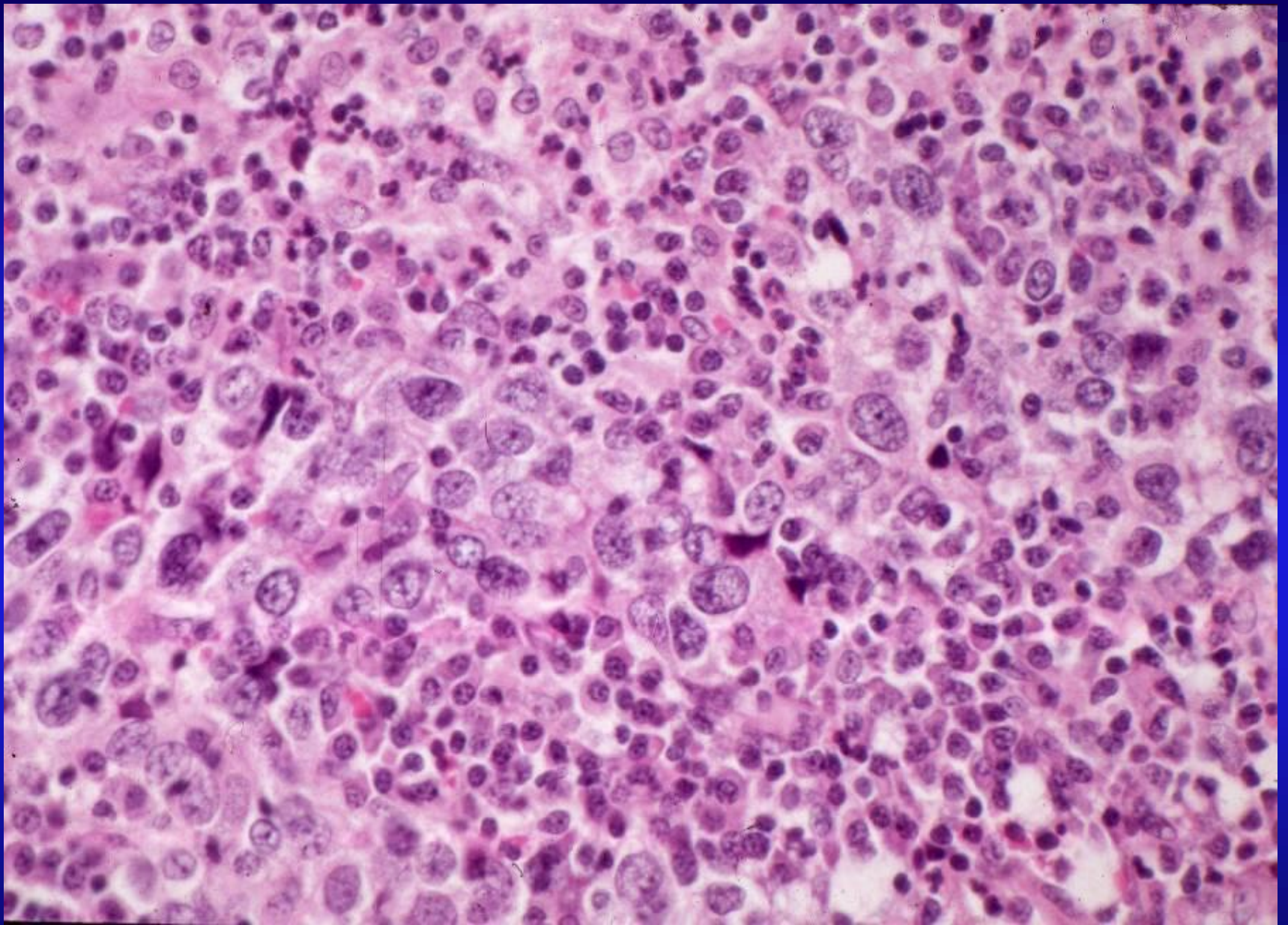


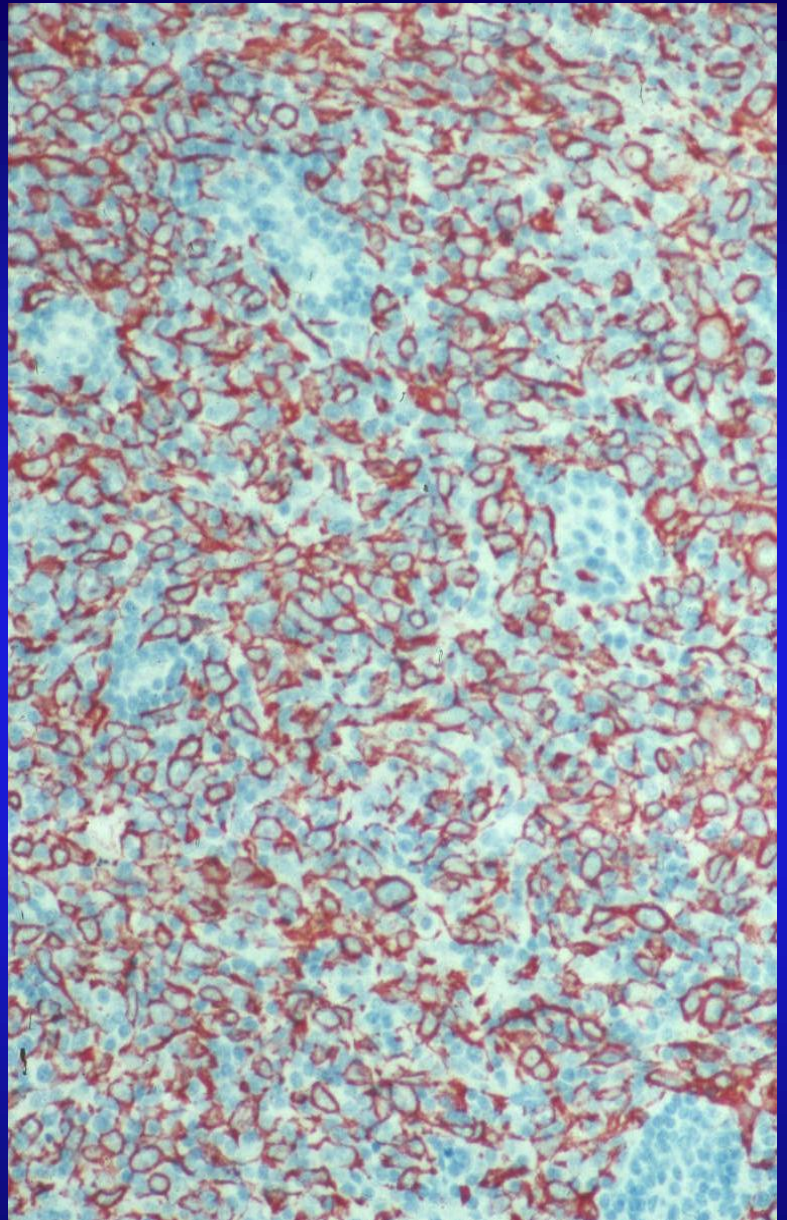
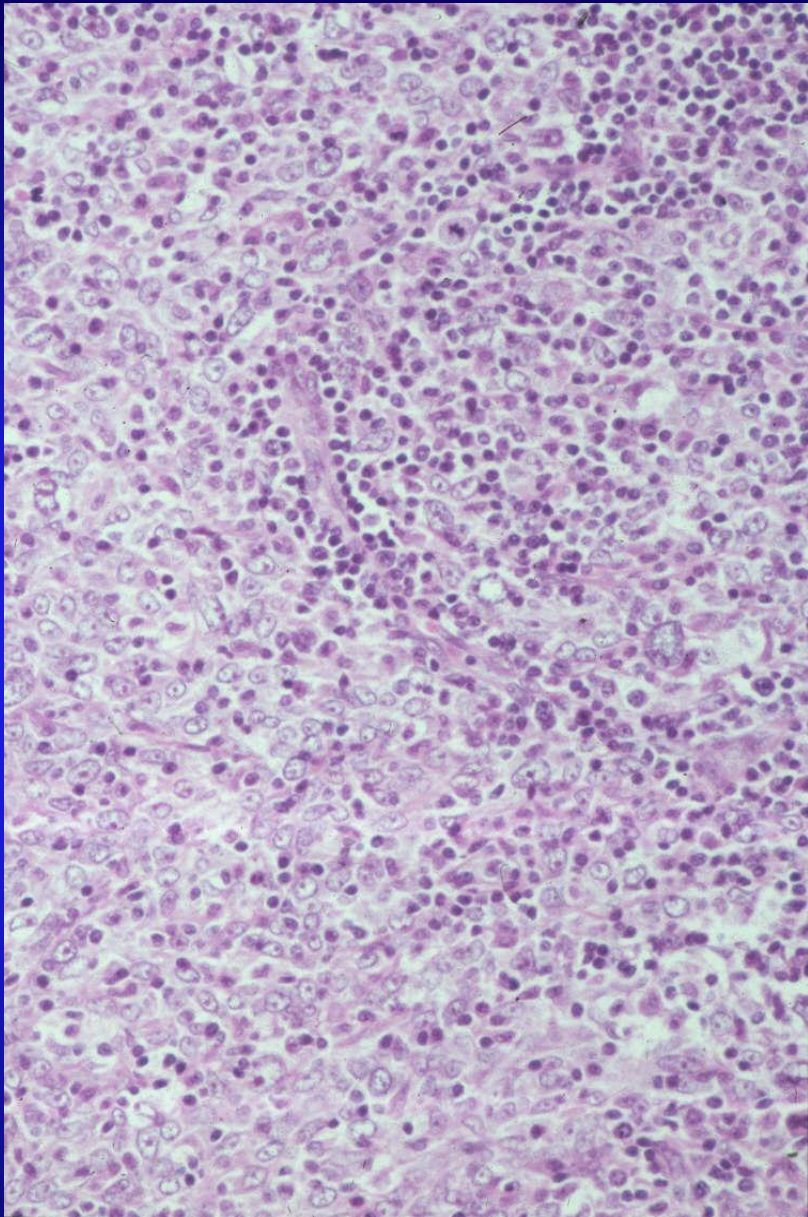
**SM13-23224**

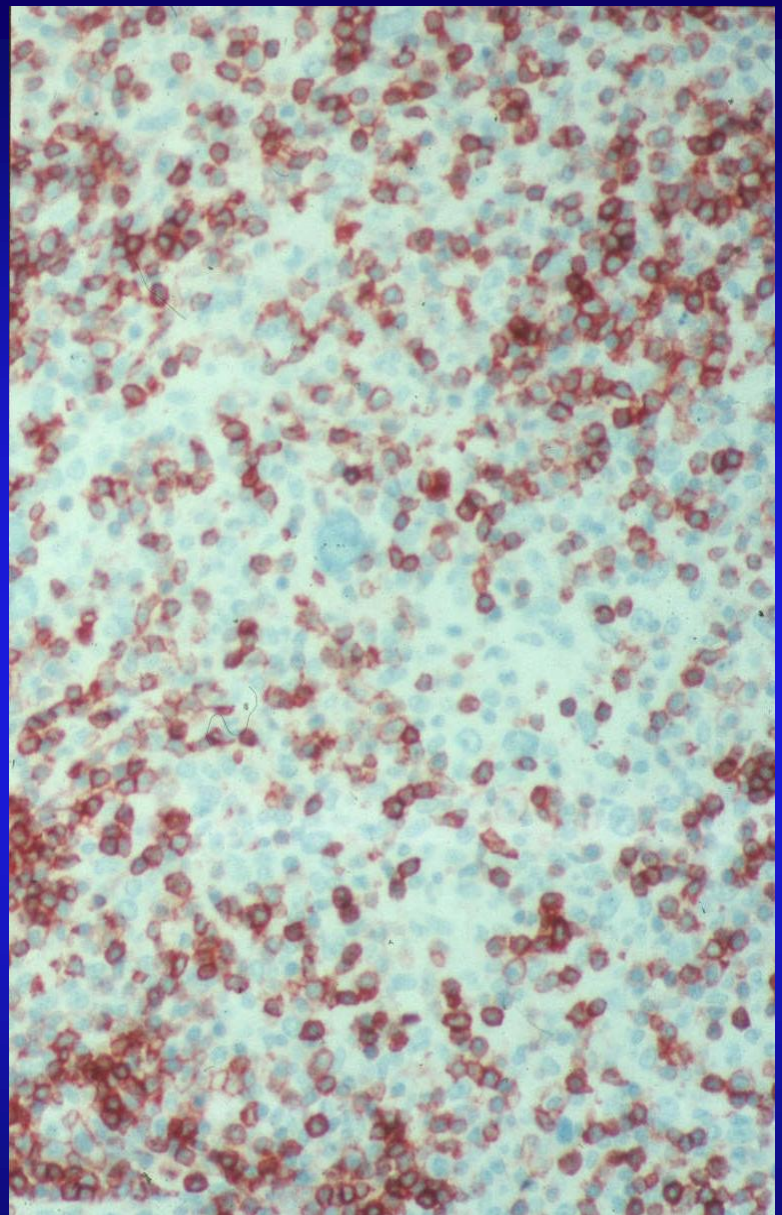
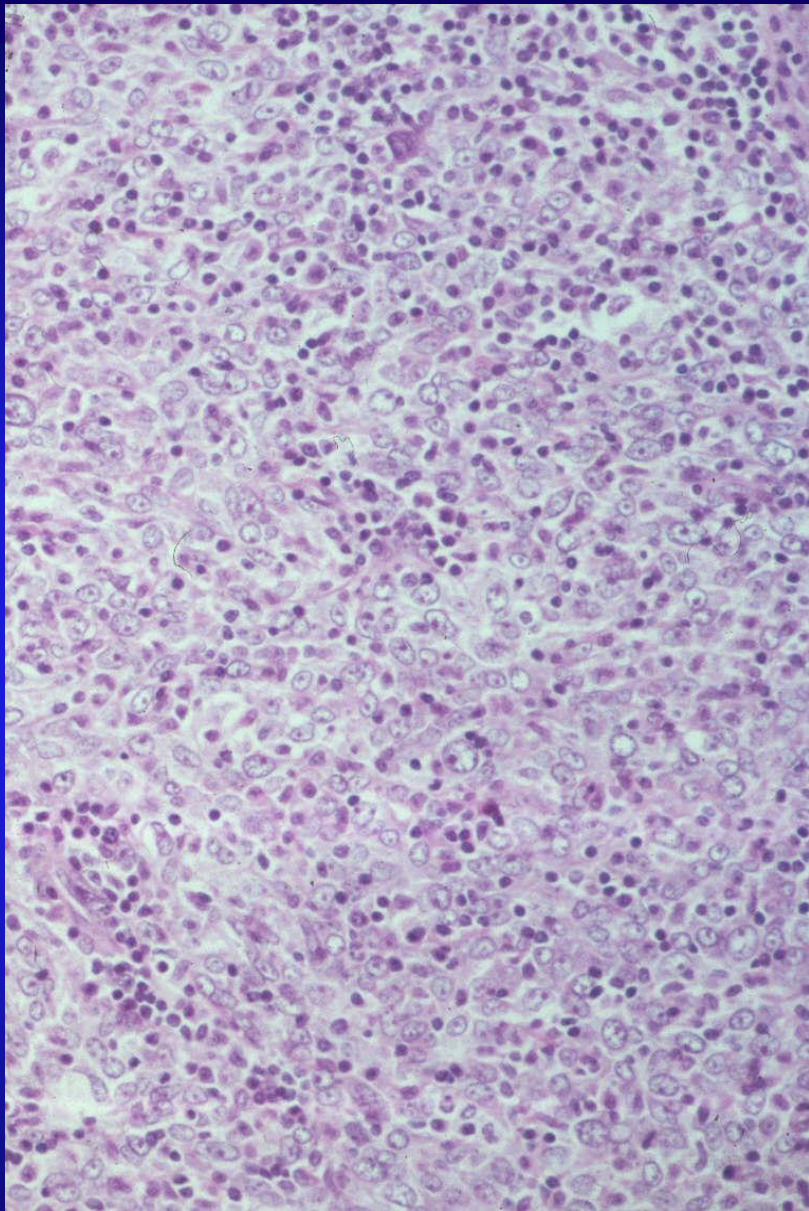


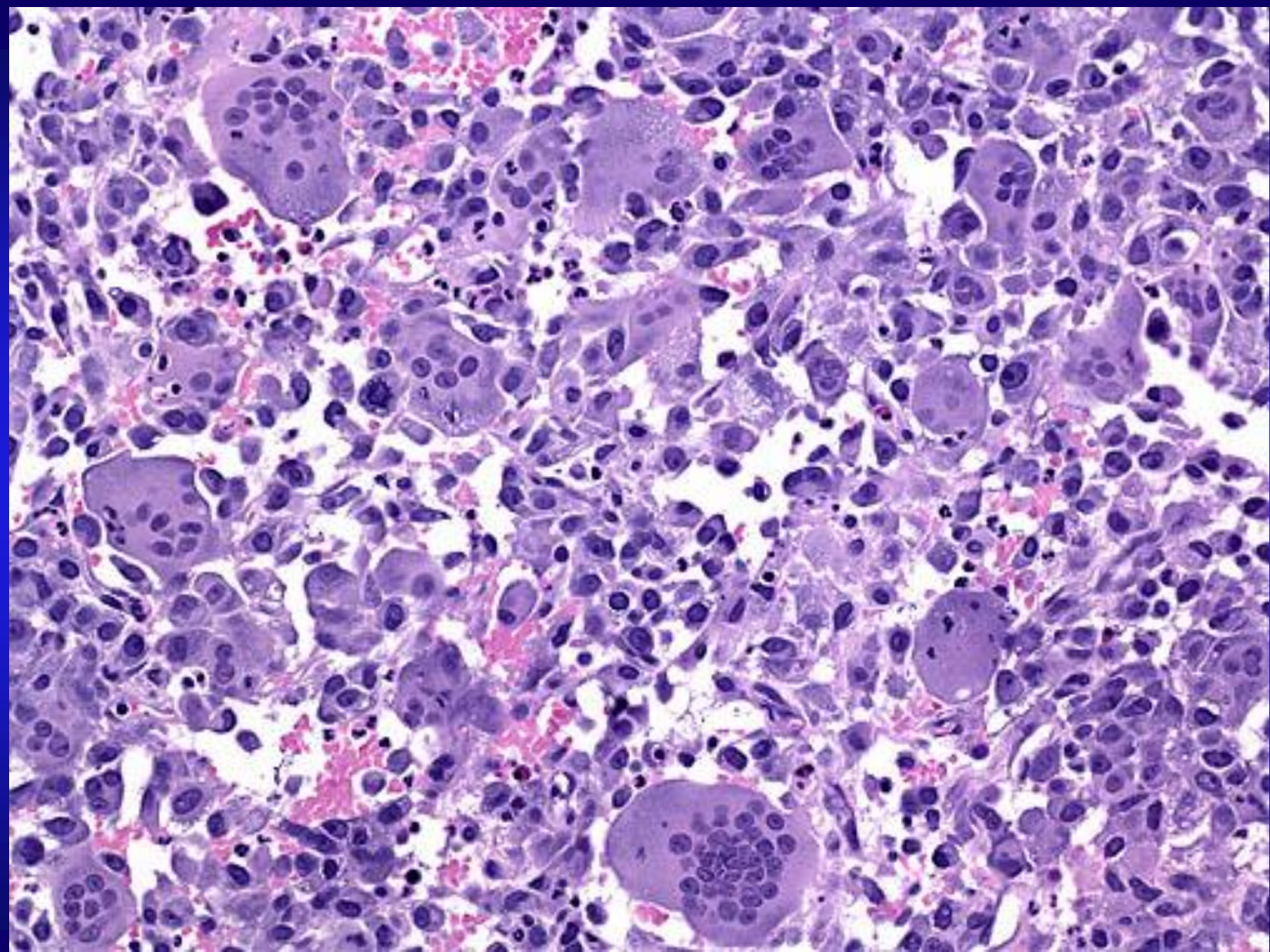


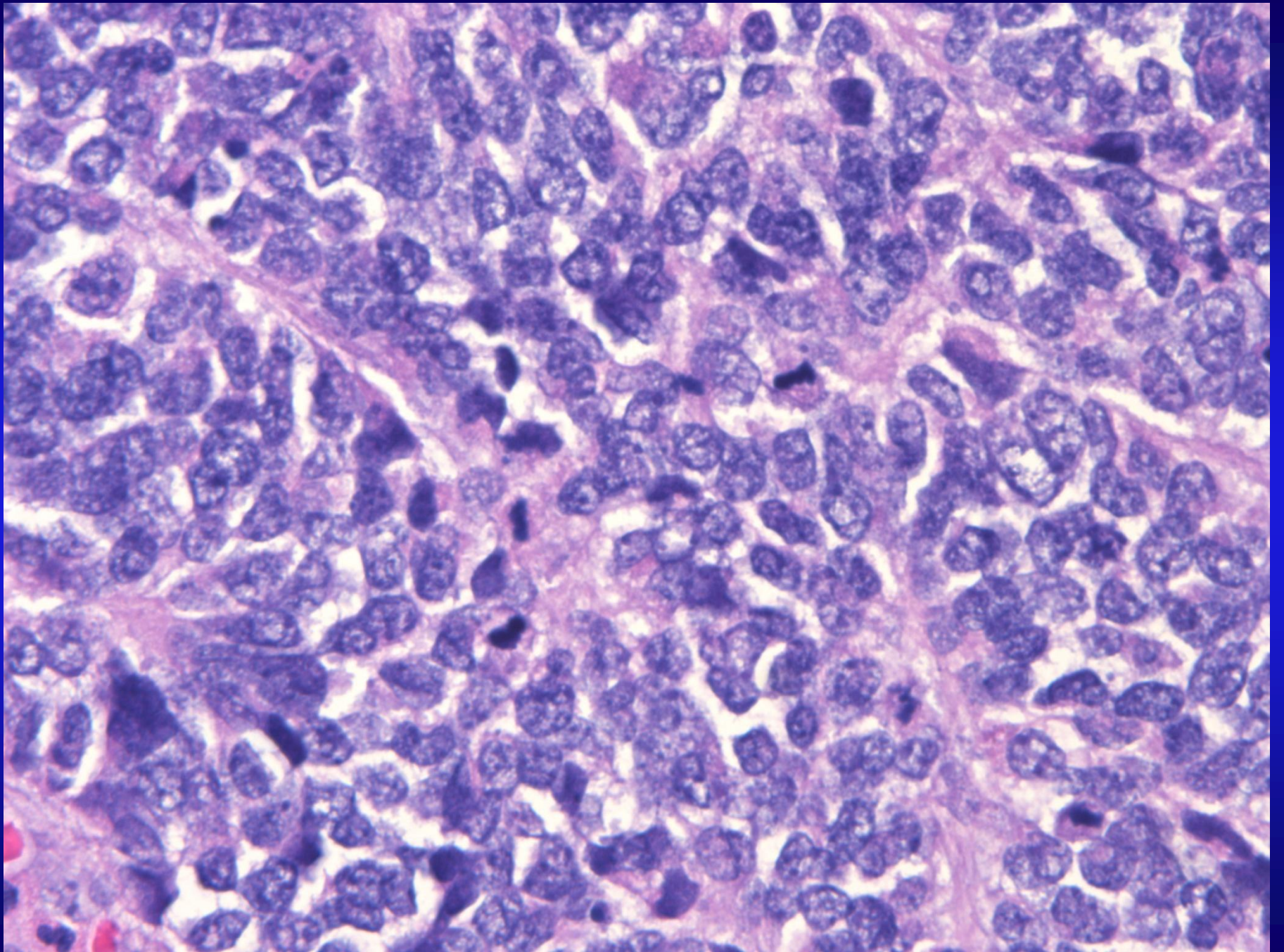










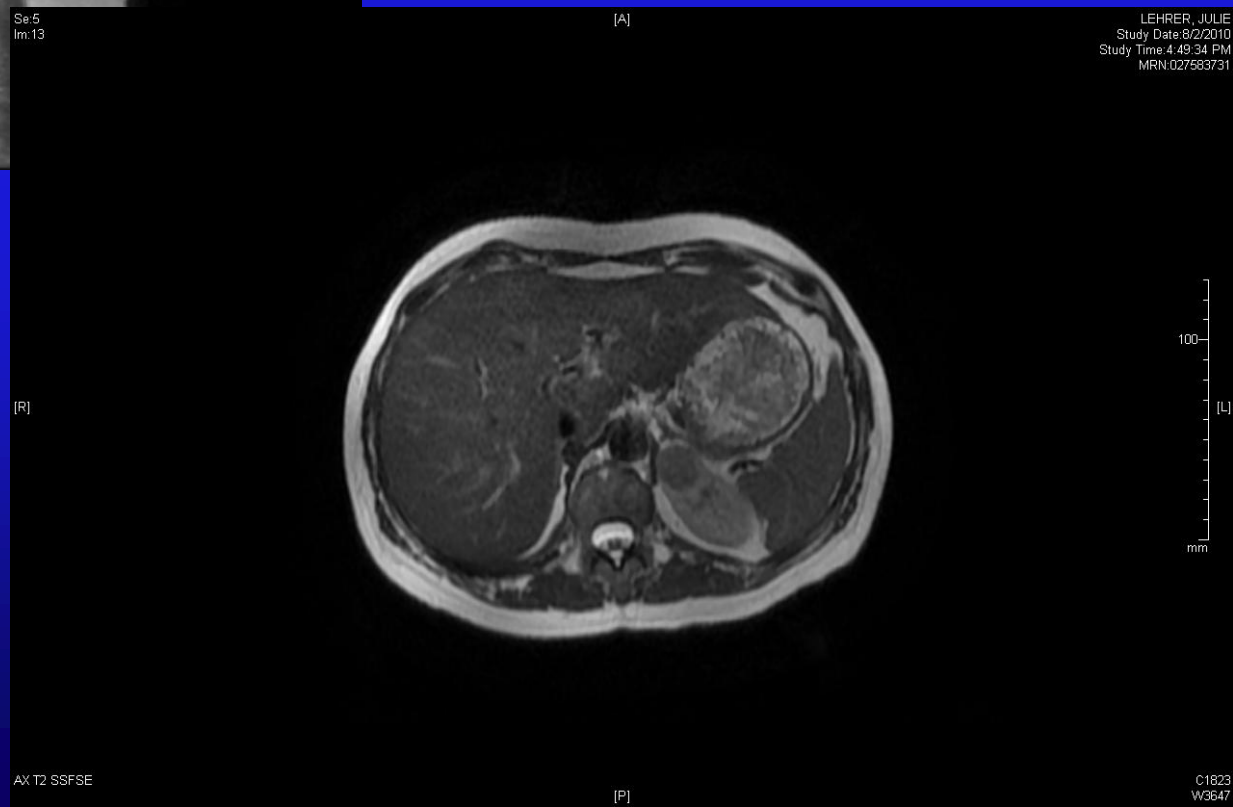
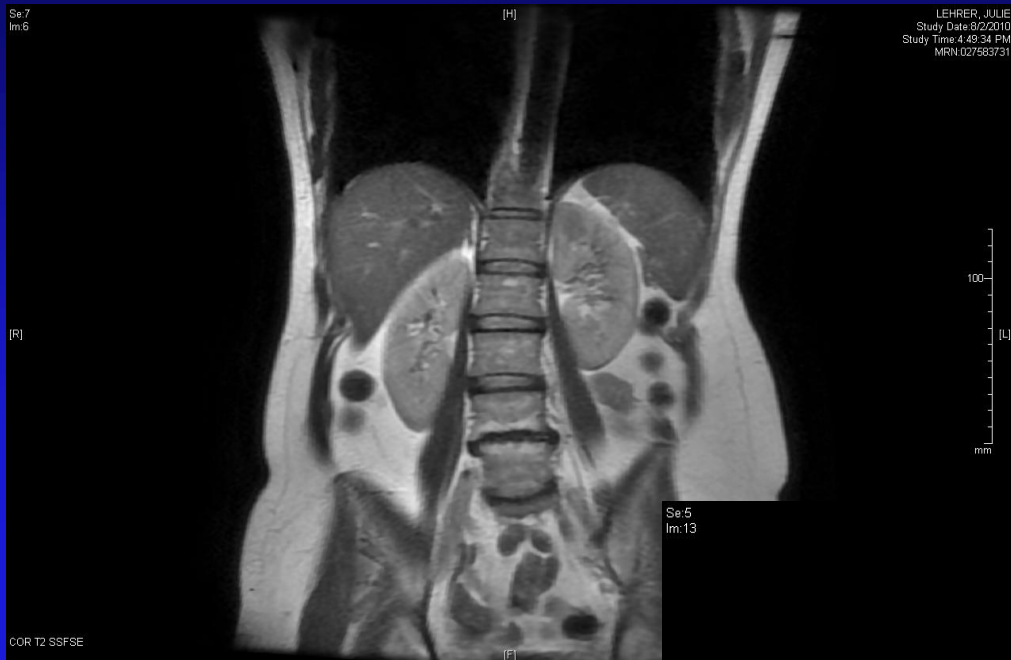

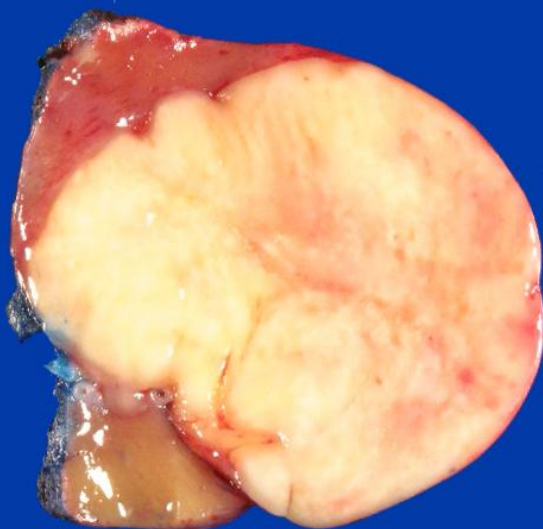


## Case 2

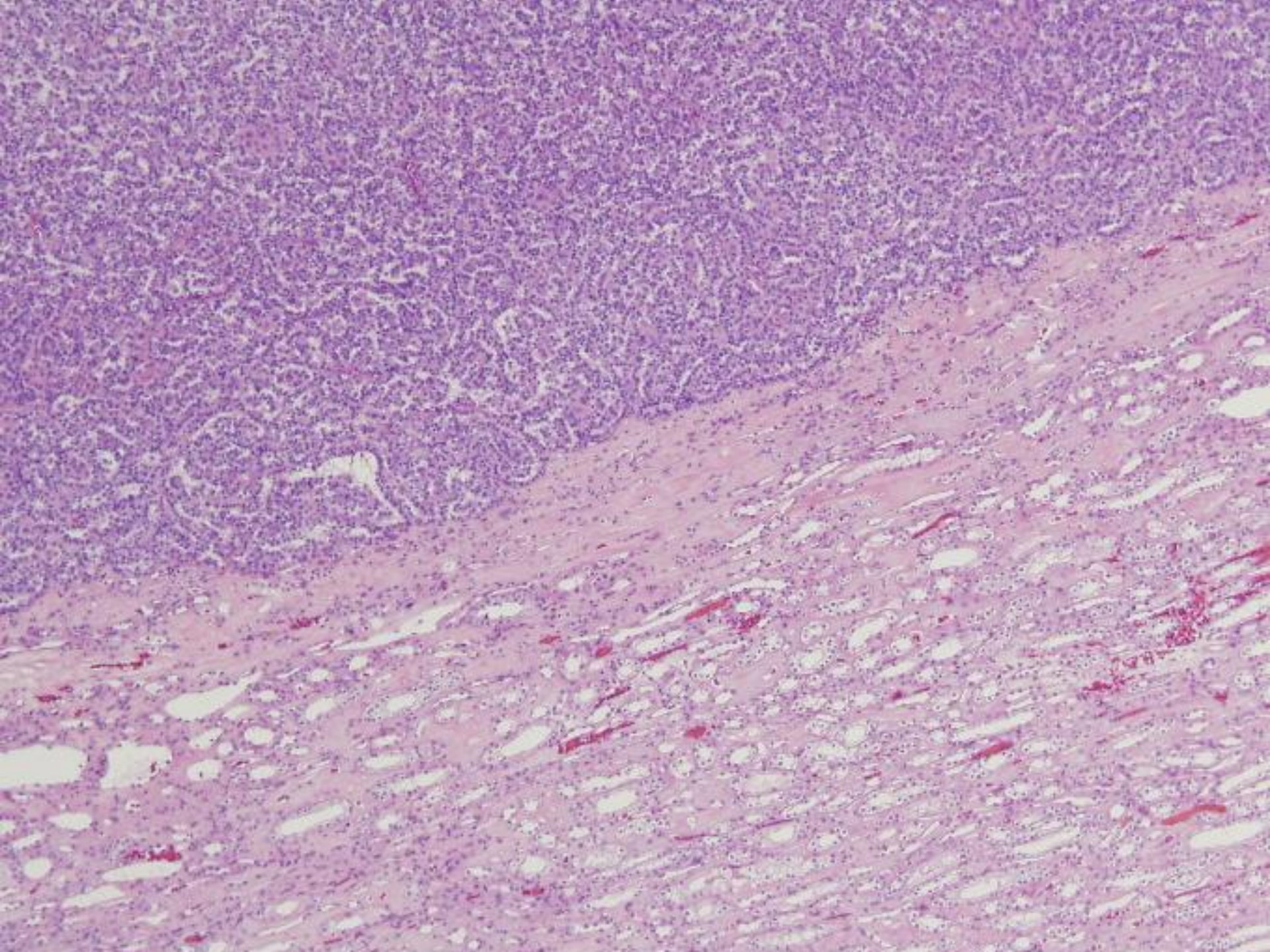
- **SM10-20986**
- **53 yo female. History of GERD with an incidental mass identified in the left kidney by US. MRI showed a 2.8 cm enhancing left upper pole renal mass.**

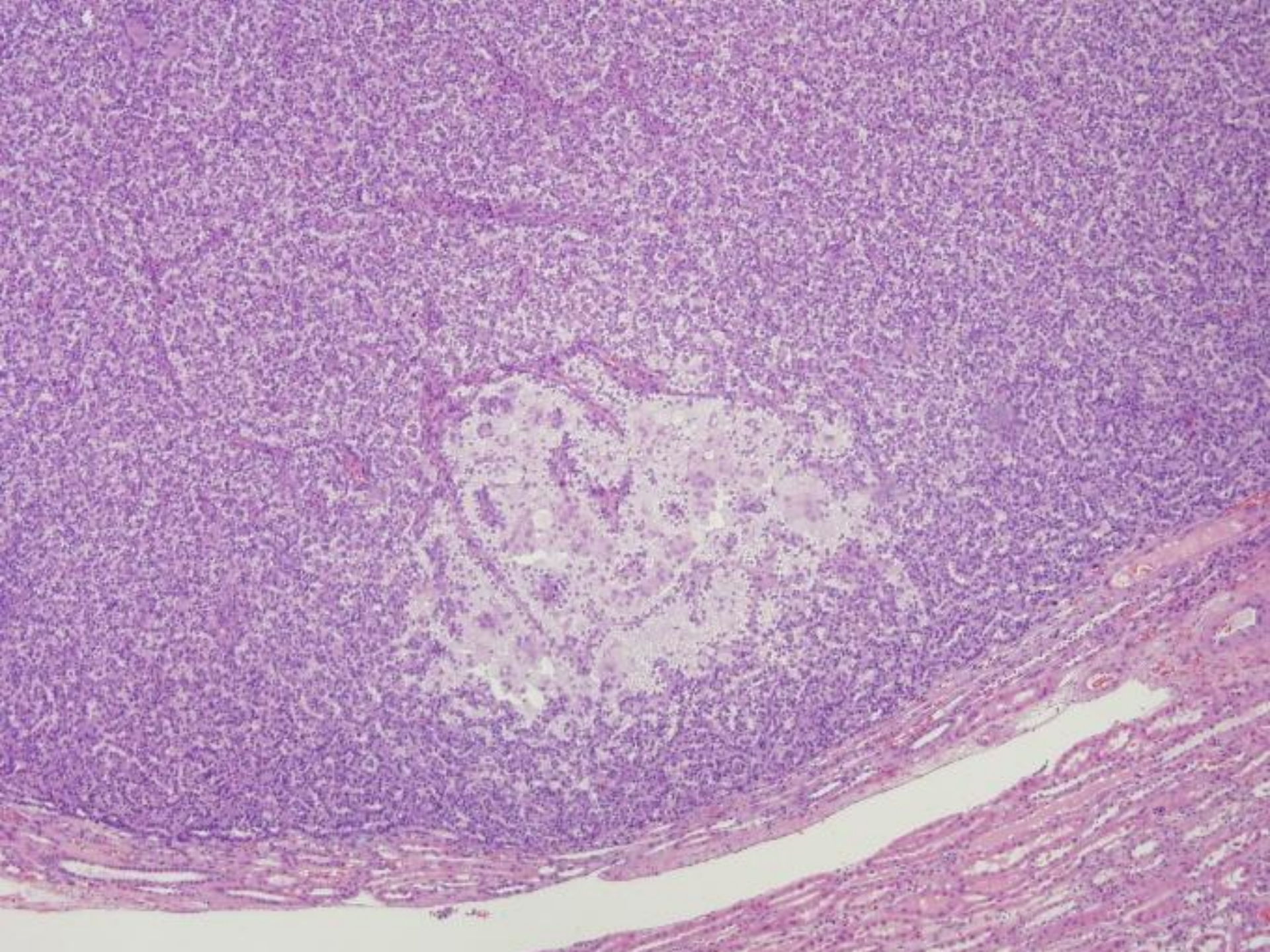
# SM10-20986

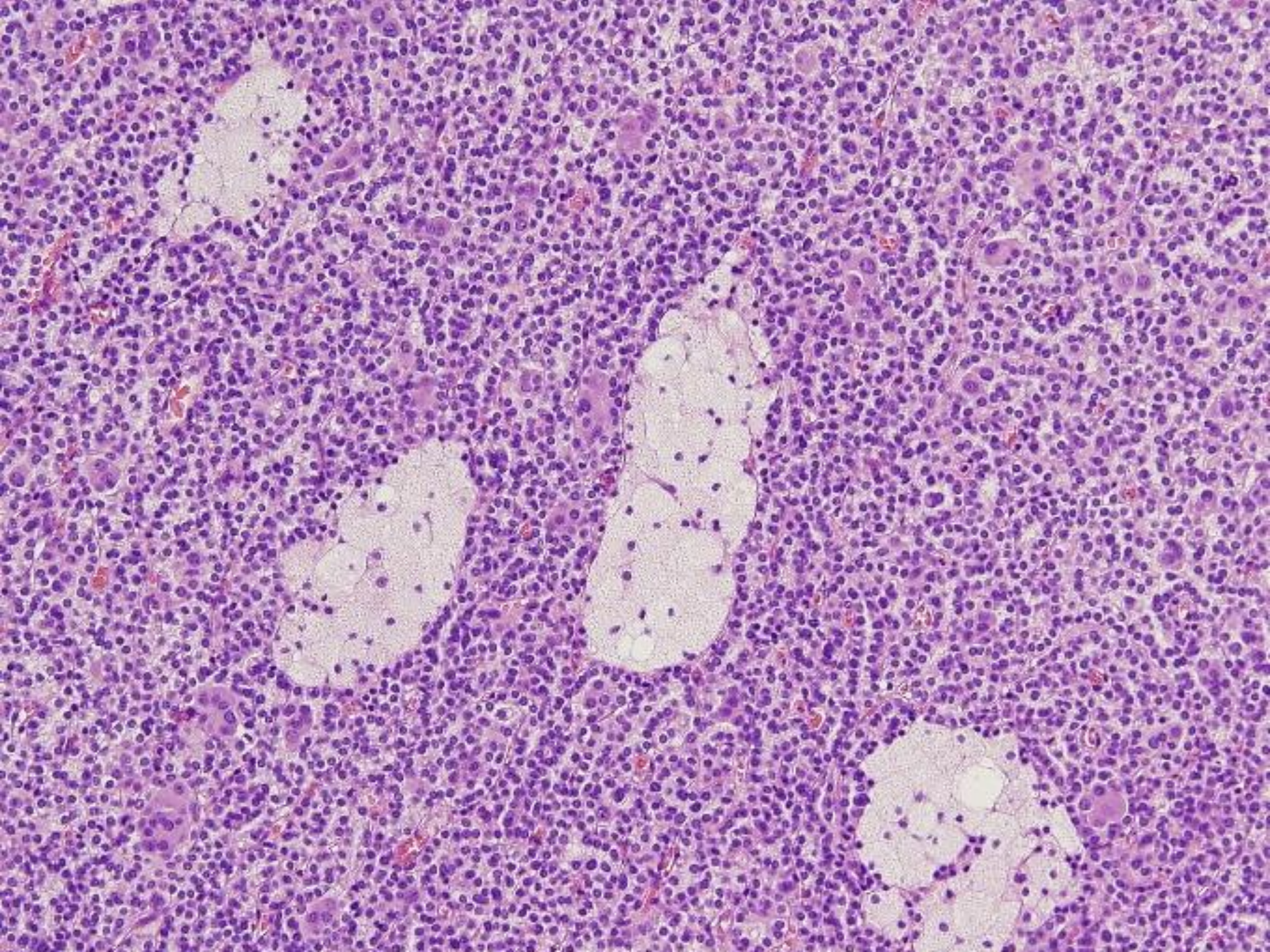


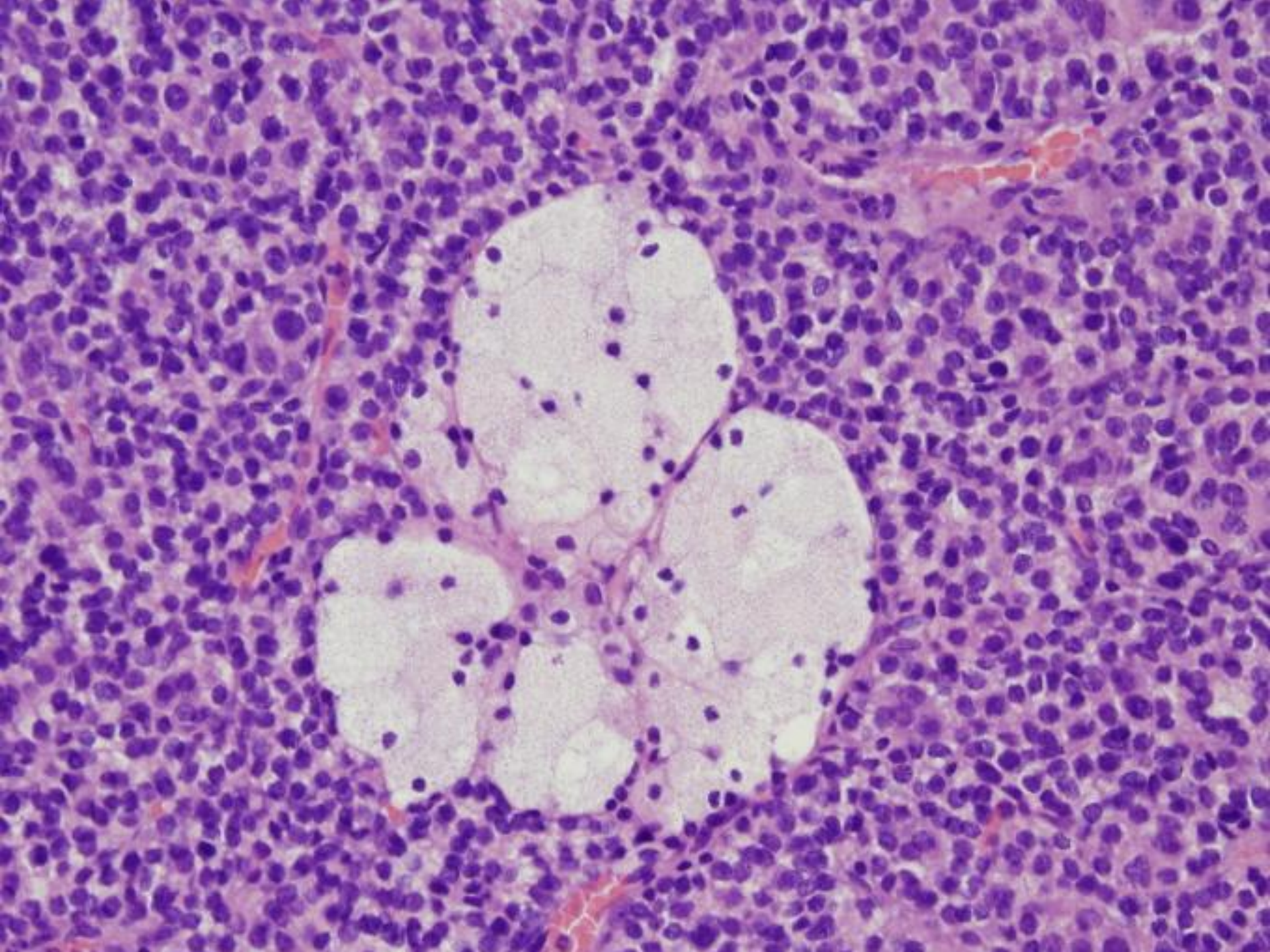


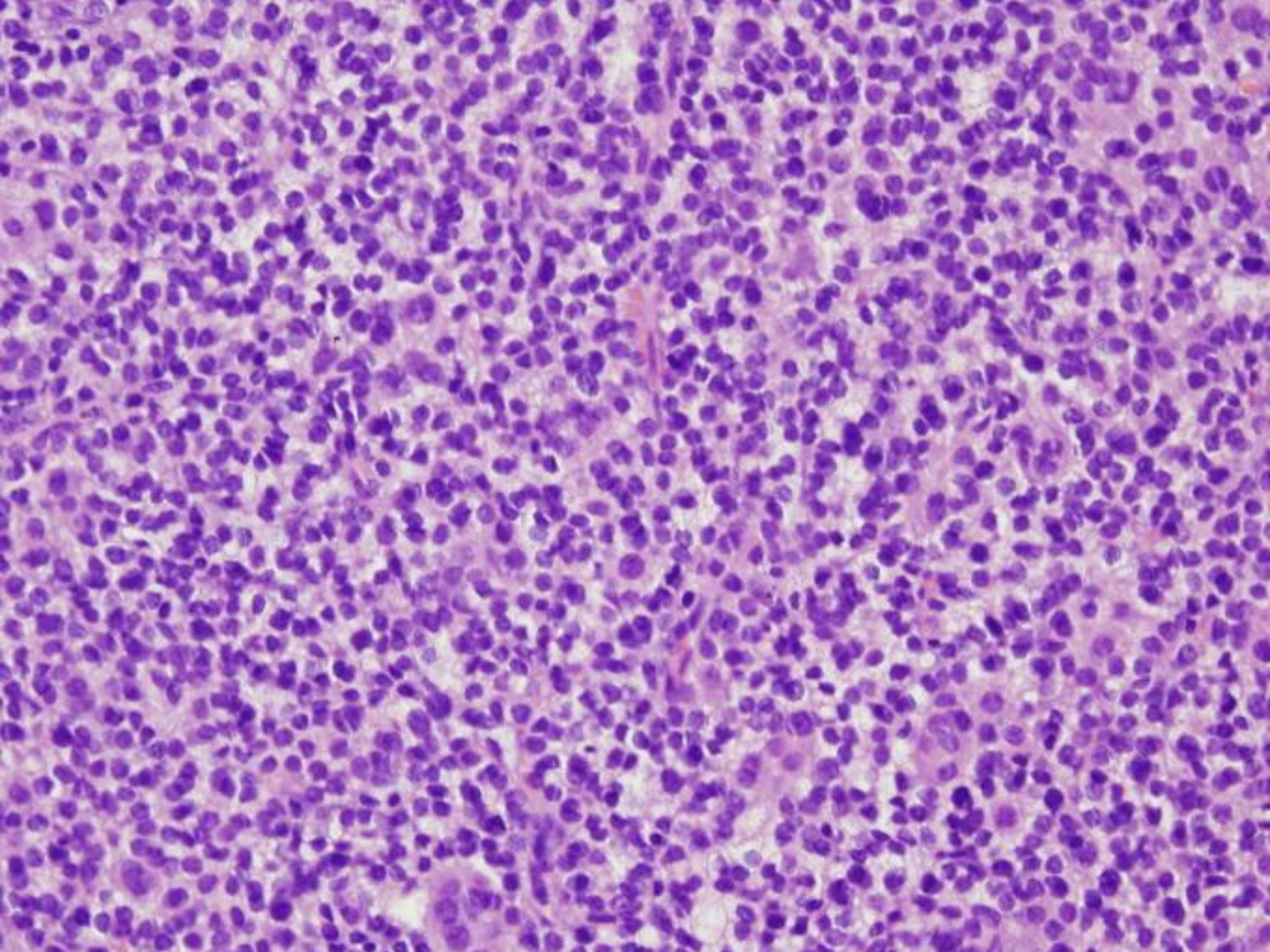
cm | 1 2 3 4 5 6  
SPECIMEN SM10-20986 B DATE 9-3-10

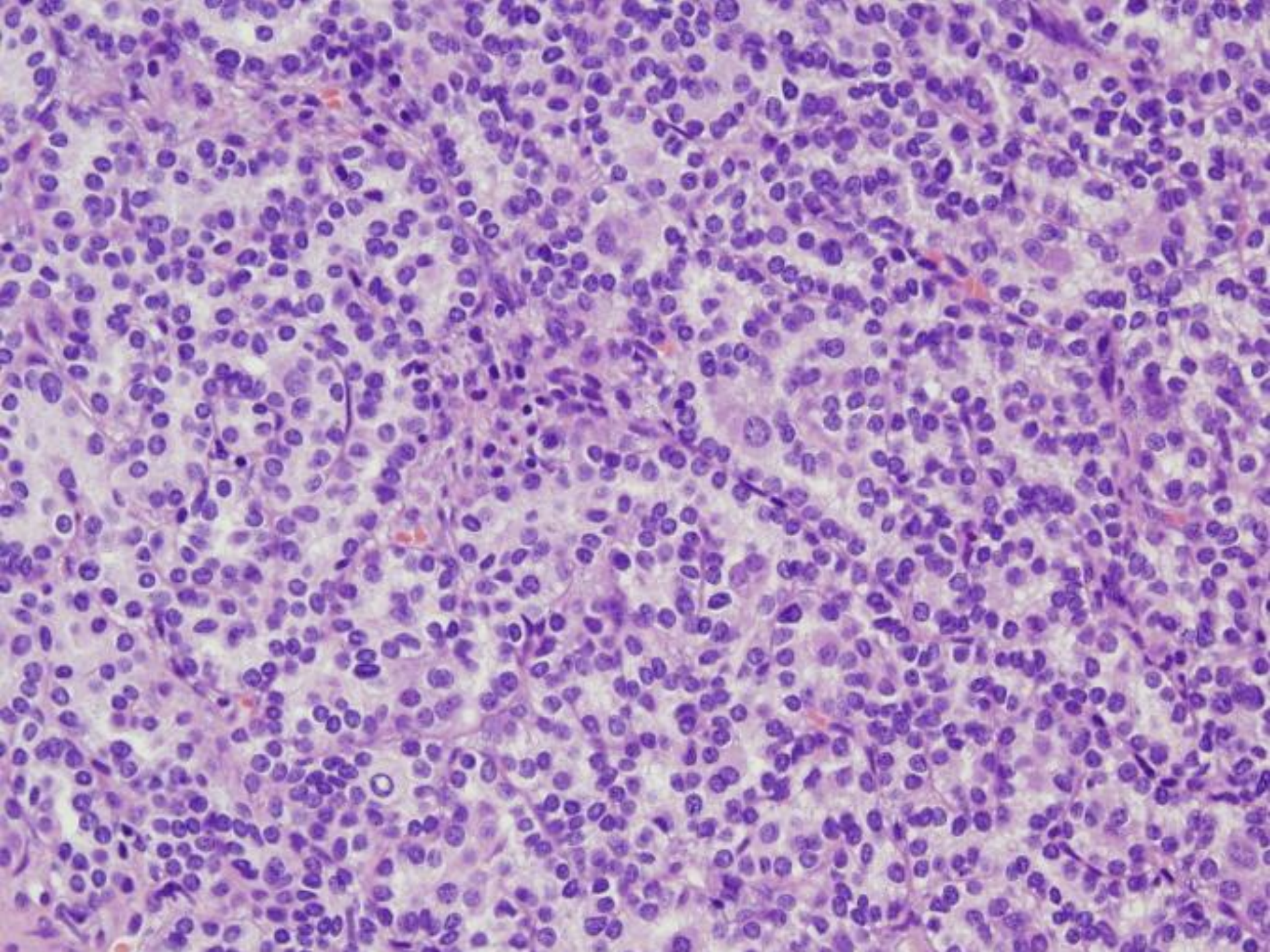


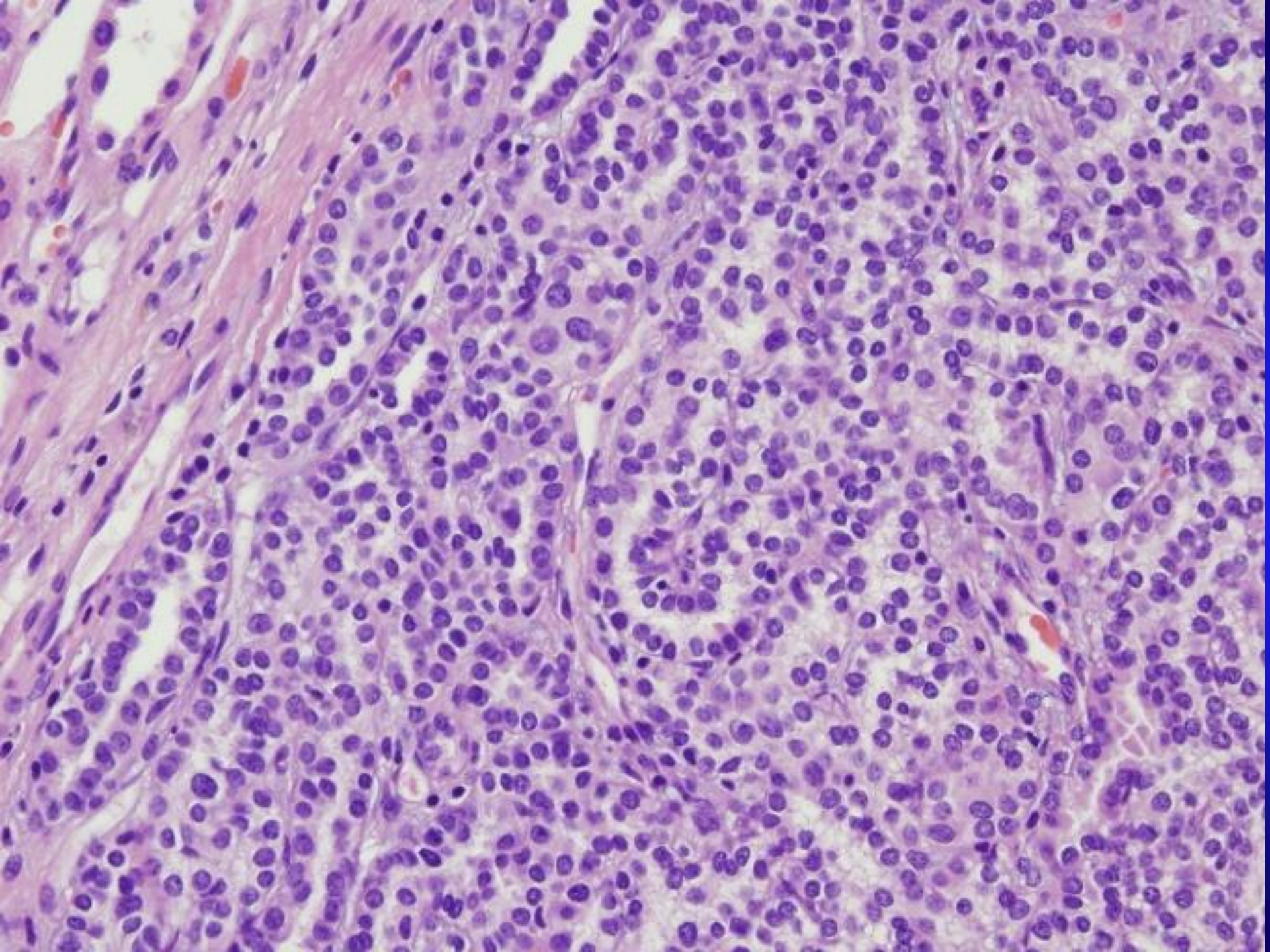


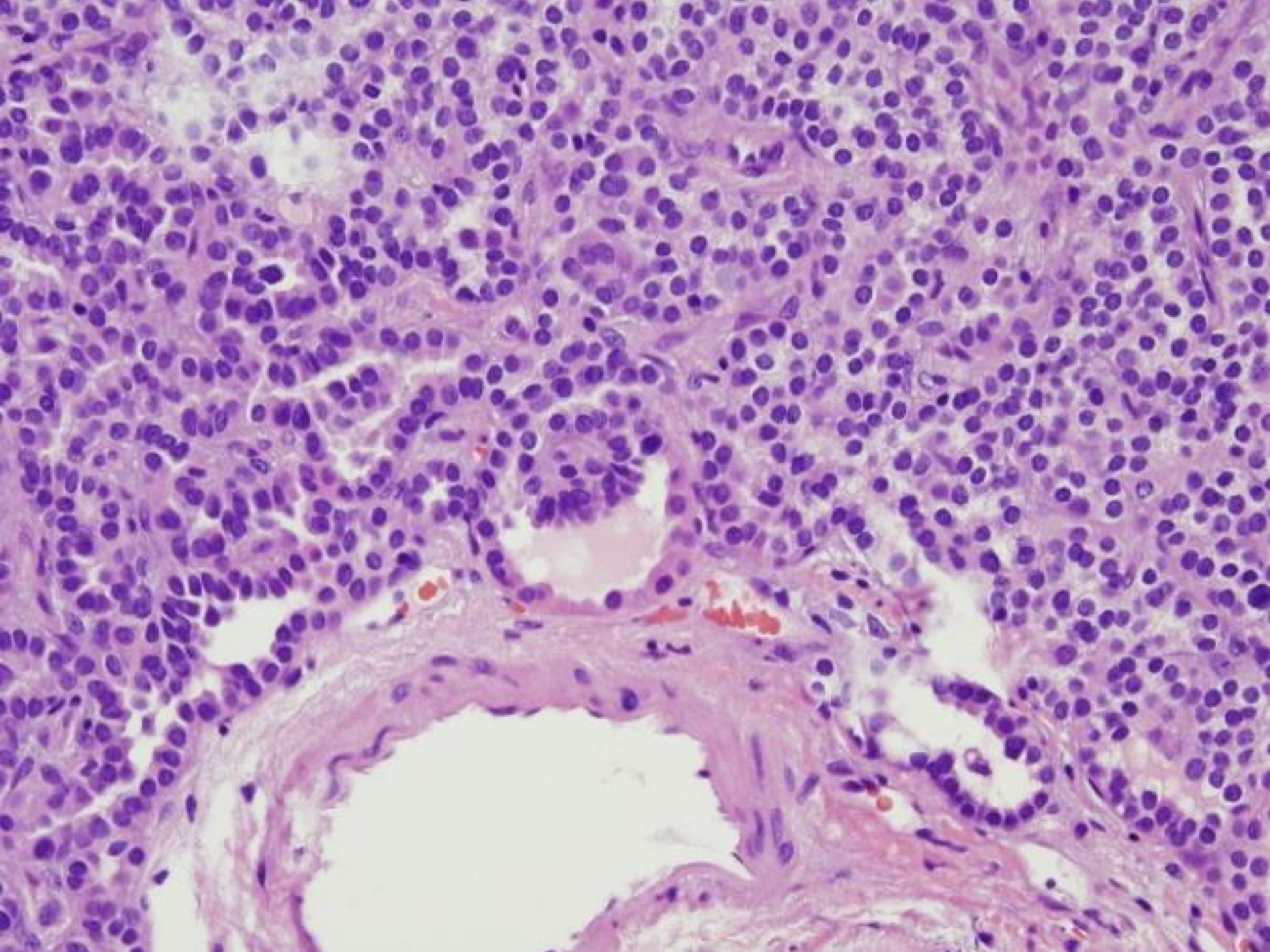


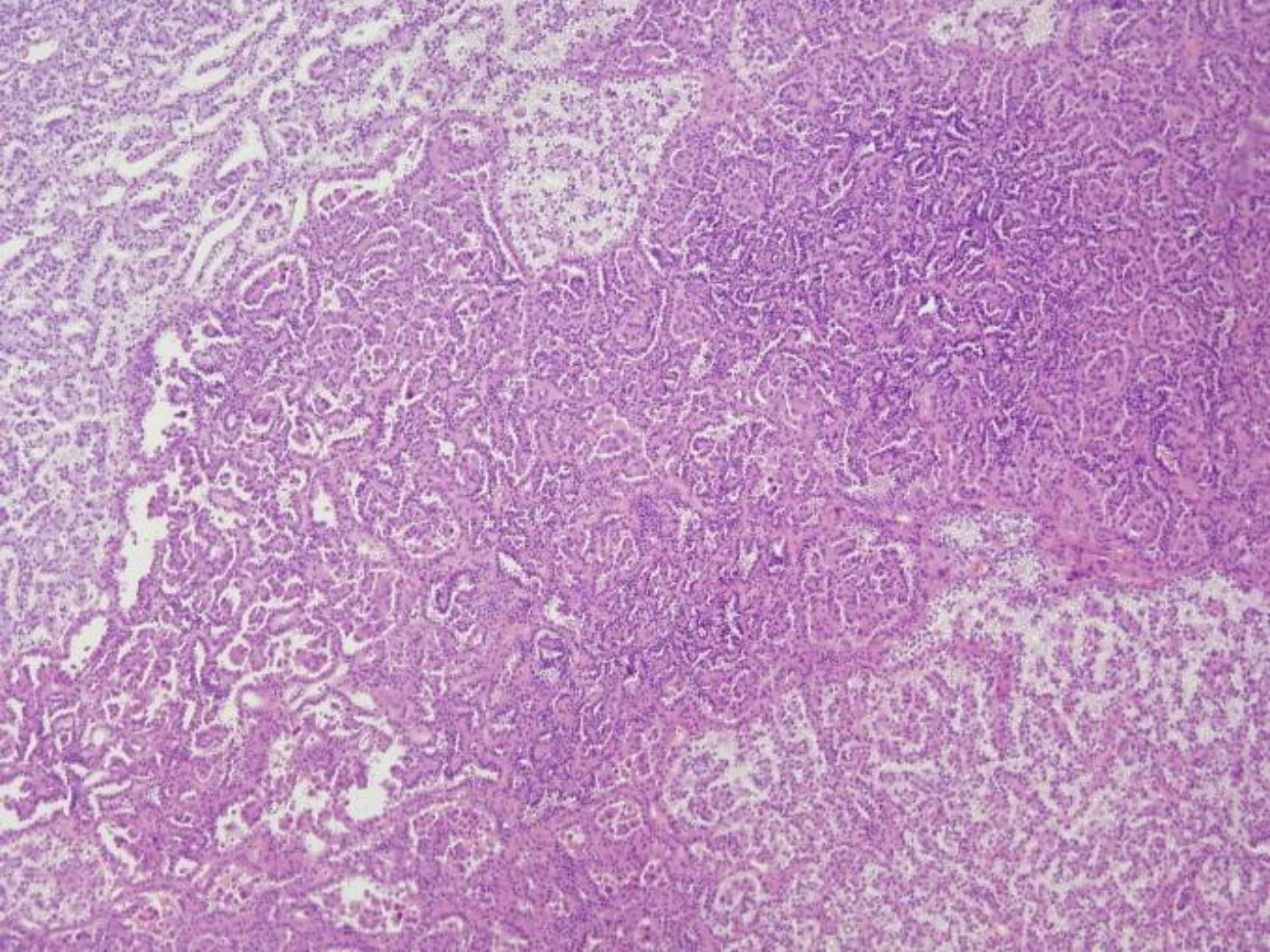


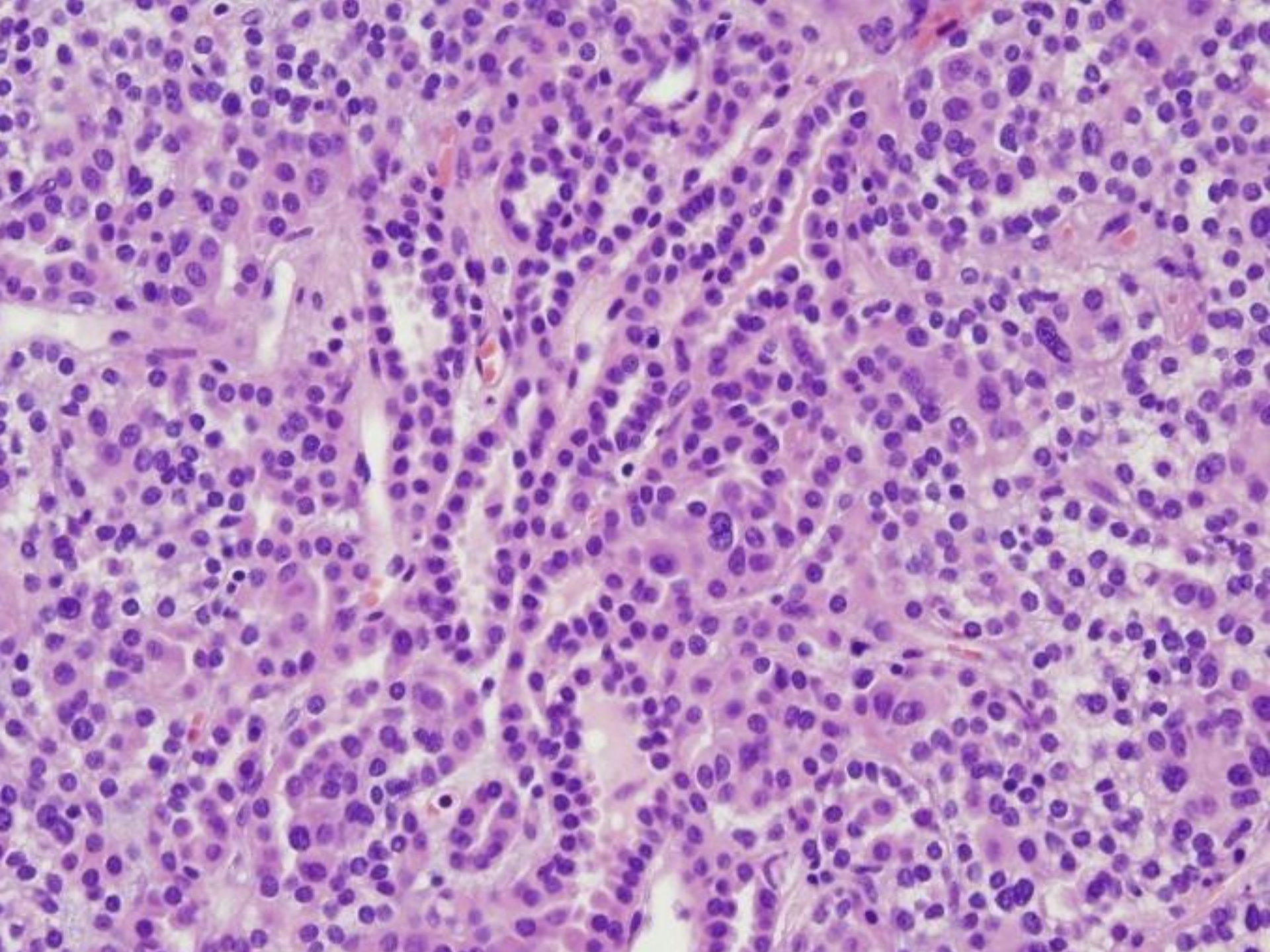


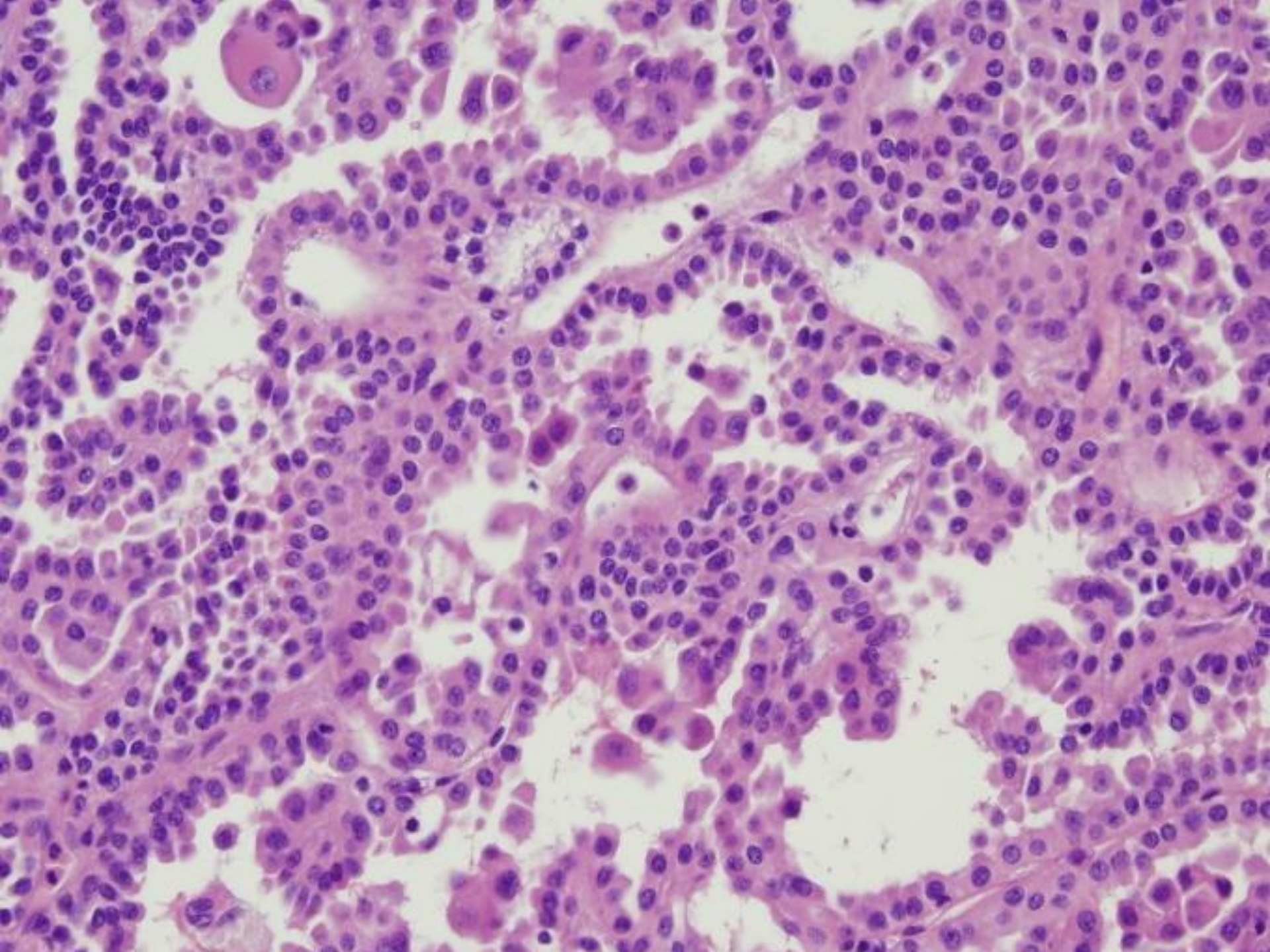


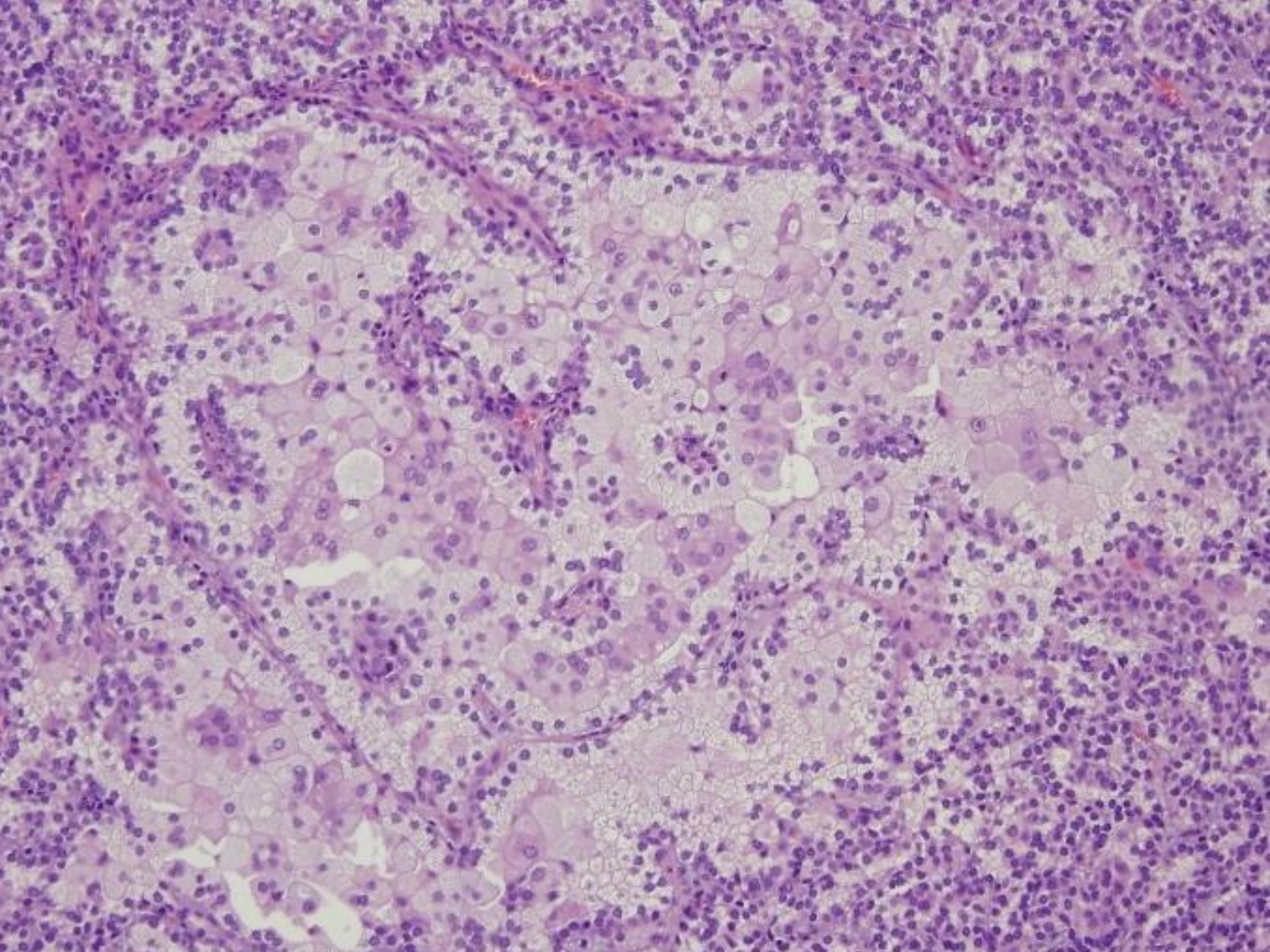


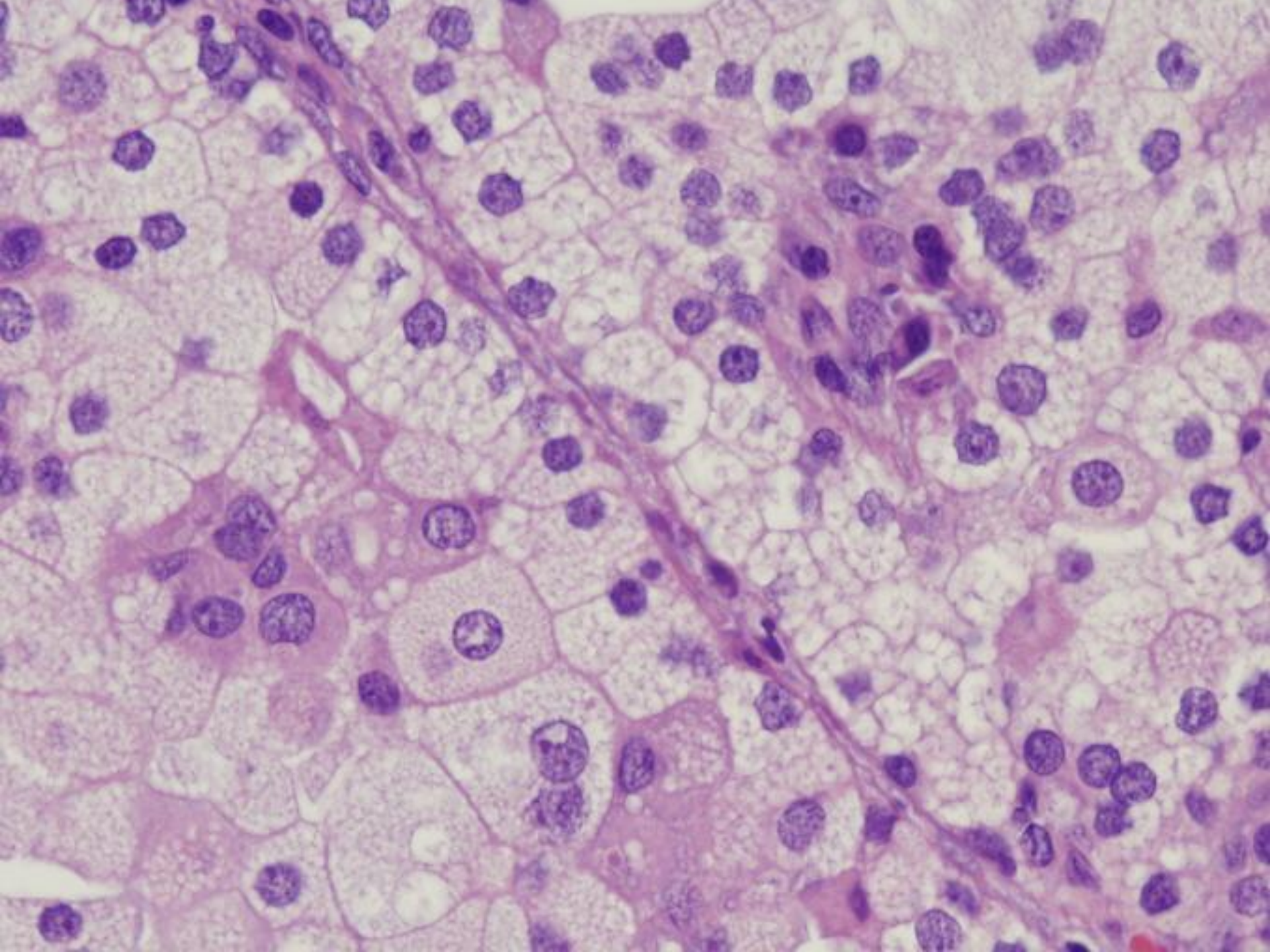






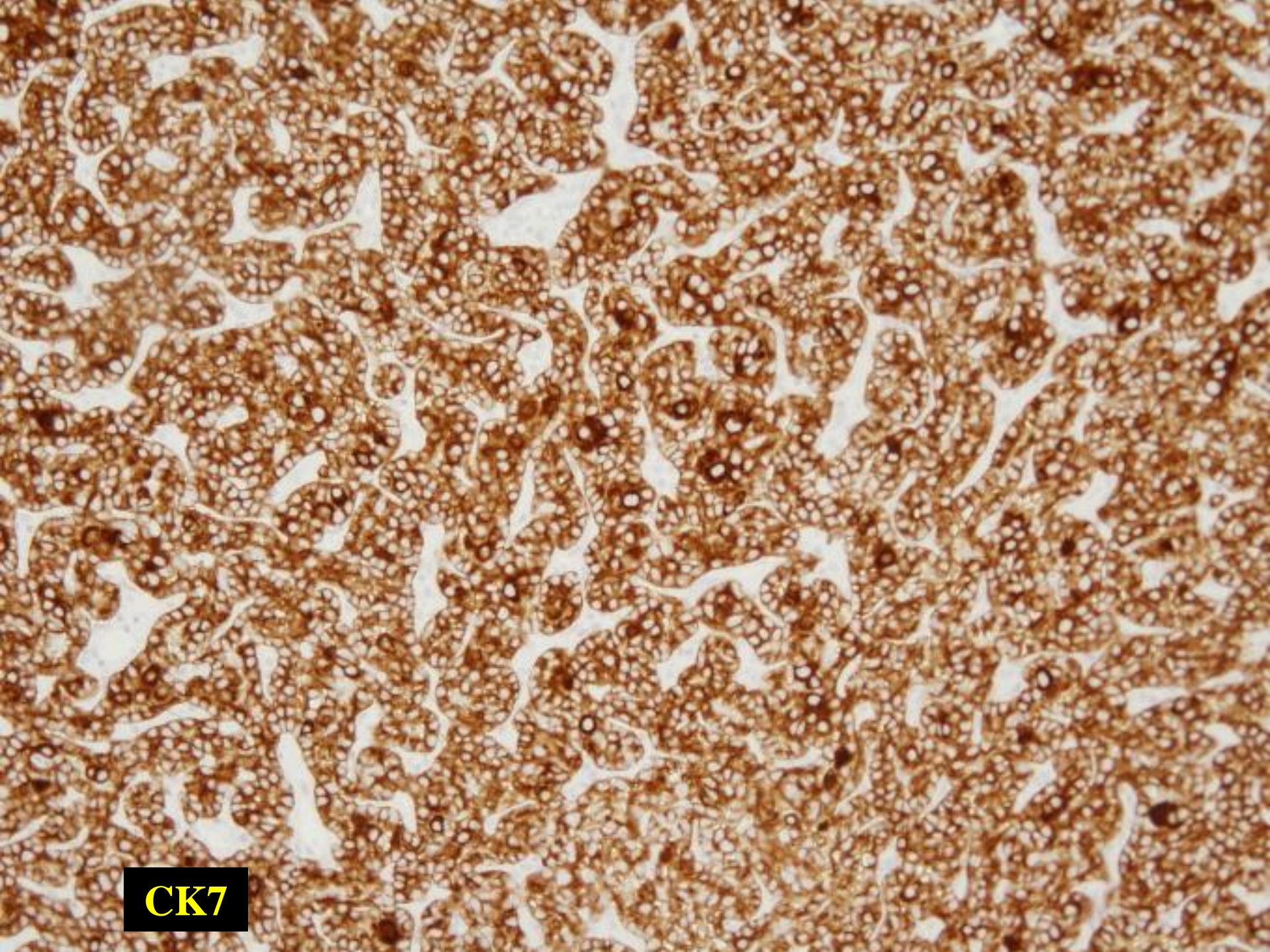




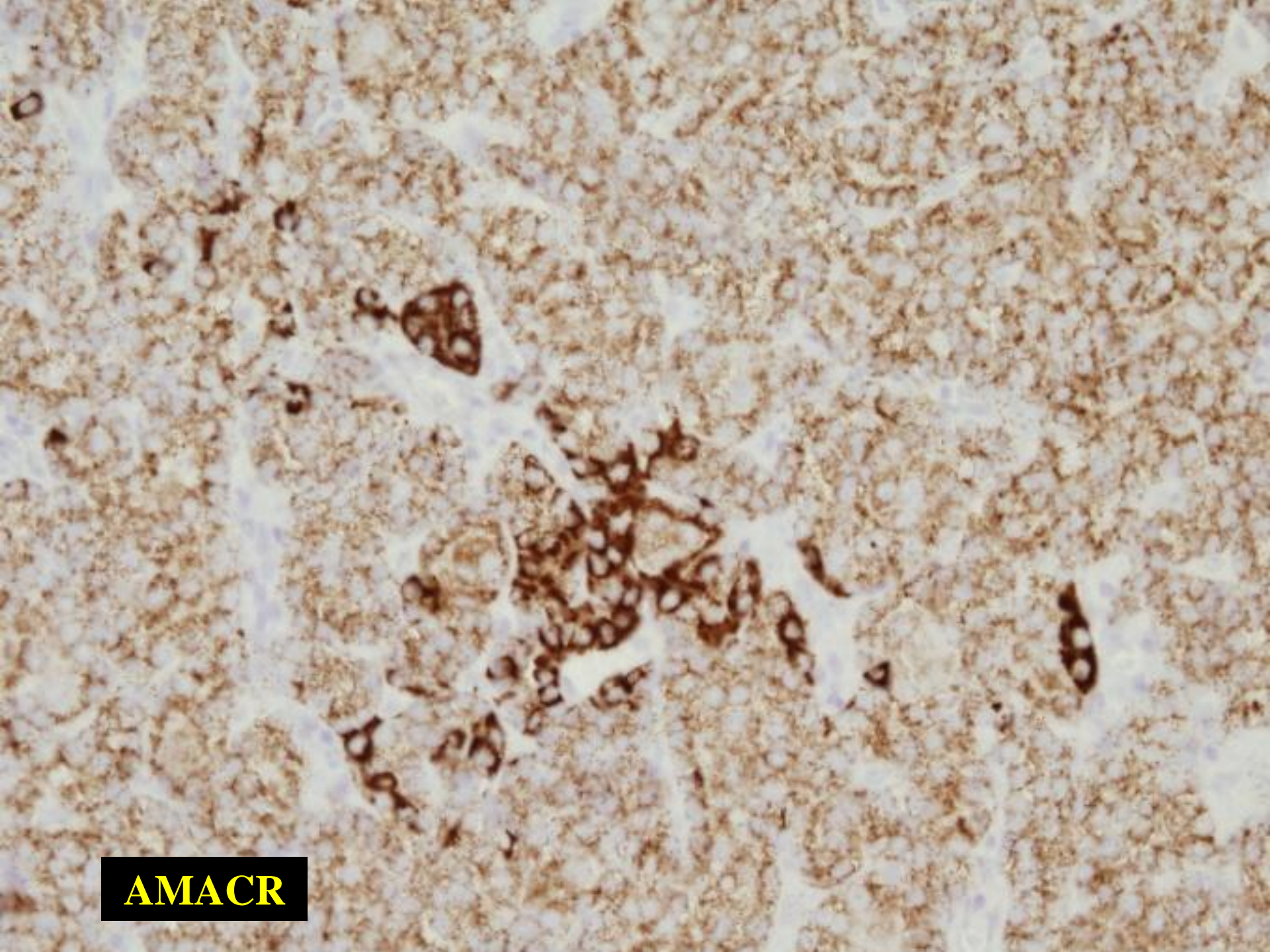


# Diagnosis and D.D.

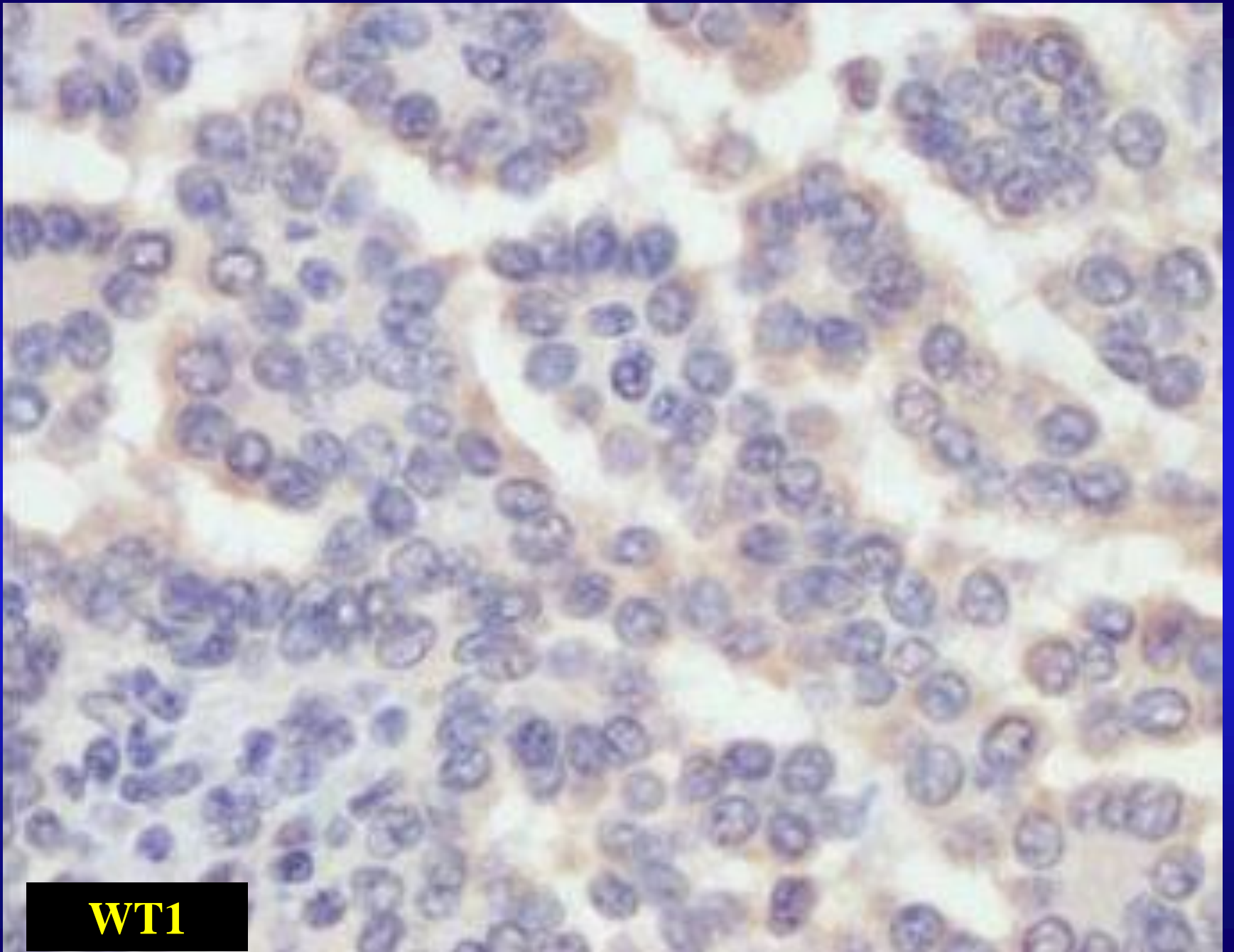
- **Metanephric adenoma**
- **Wilms' tumor**
- **Papillary RCC**
- **Others**



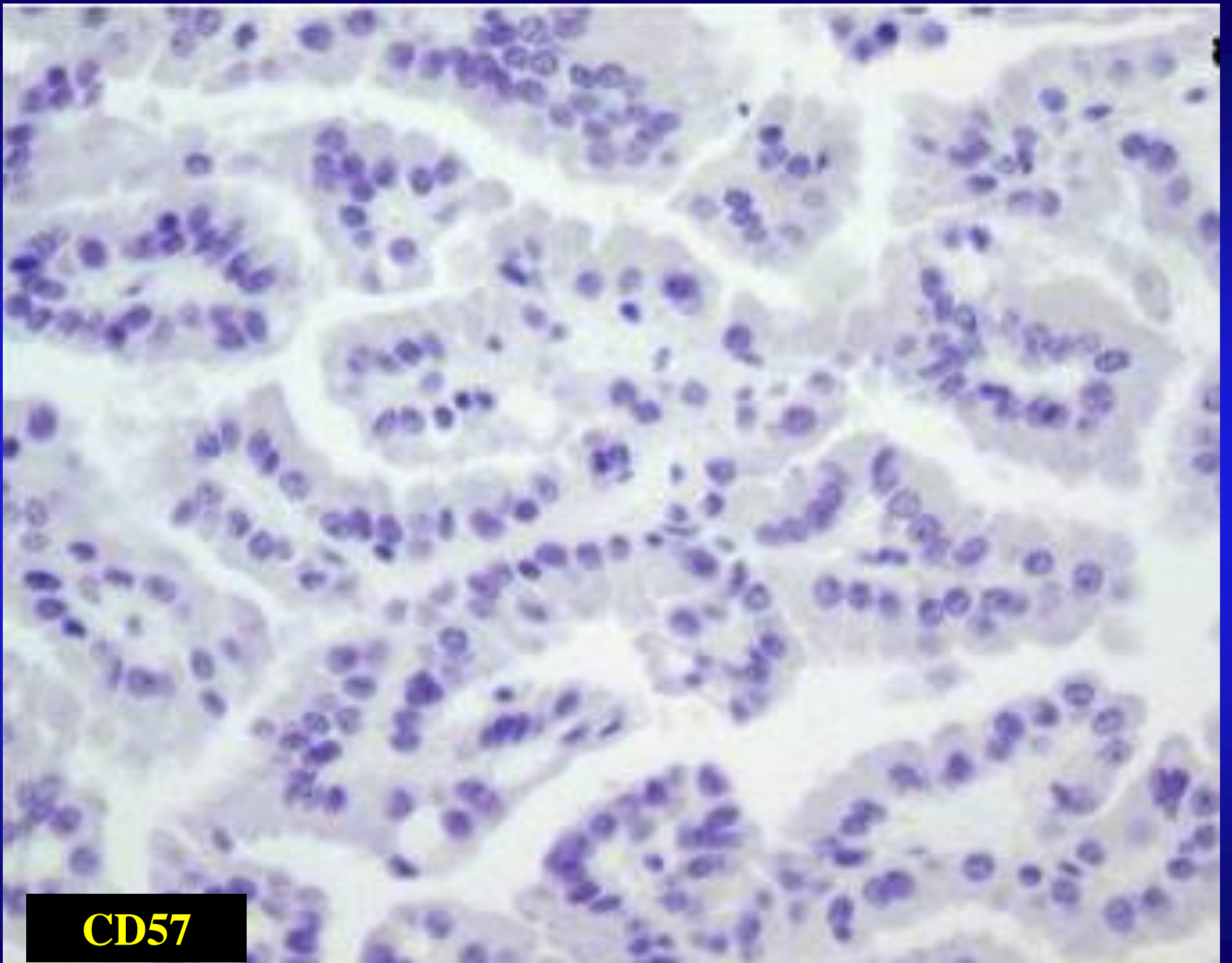
**CK7**



**AMACR**



**WT1**



**CD57**

# Diagnosis

- Metanephric-like pRCC

Battery of stains

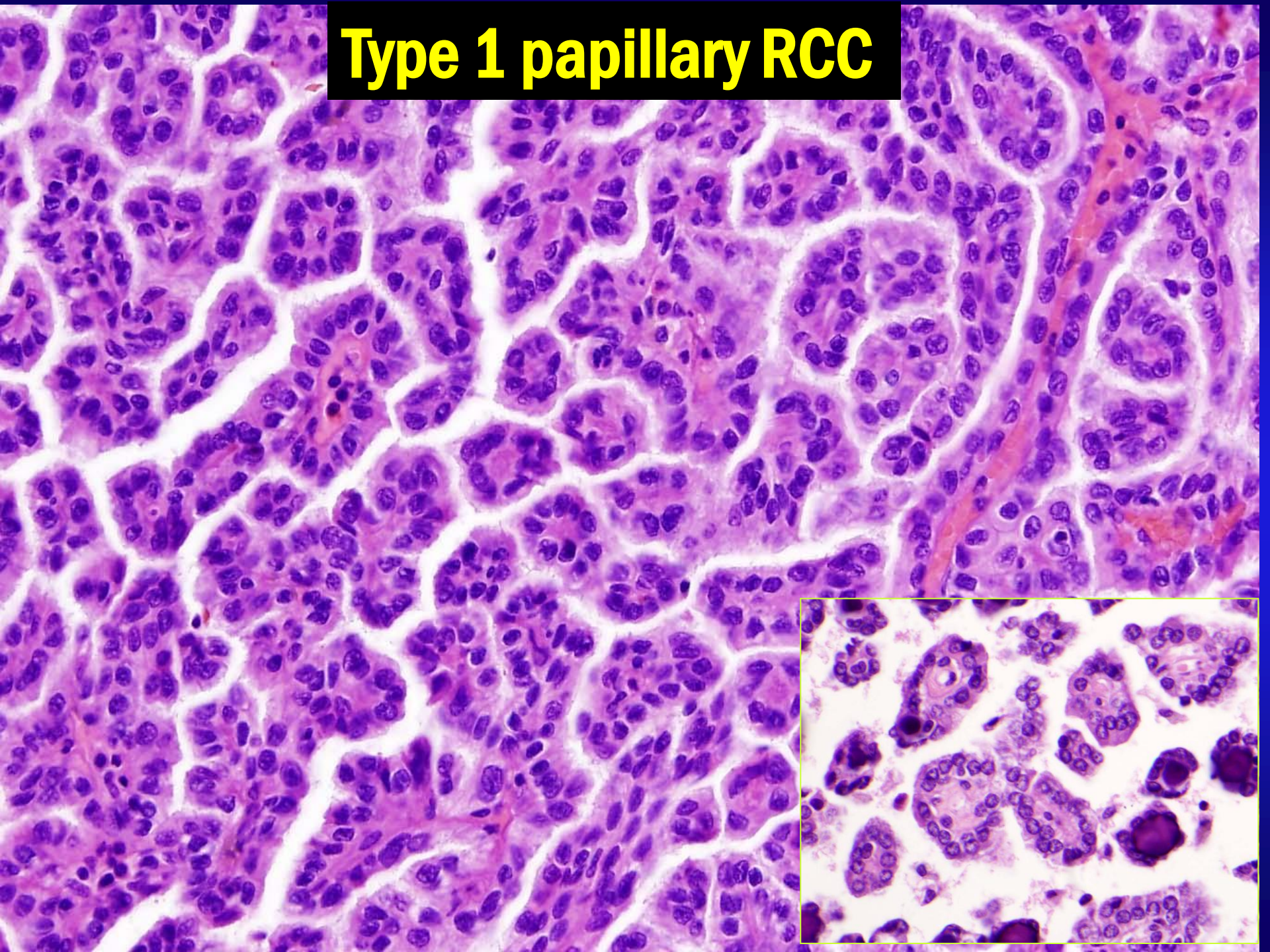
	<b>CK7</b>	<b>AMACR</b>	<b>CD57</b>	<b>WT1</b>
<b>pRCC</b>	+	+	-	-
<b>MA</b>	-	-	+	+

# Papillary RCC

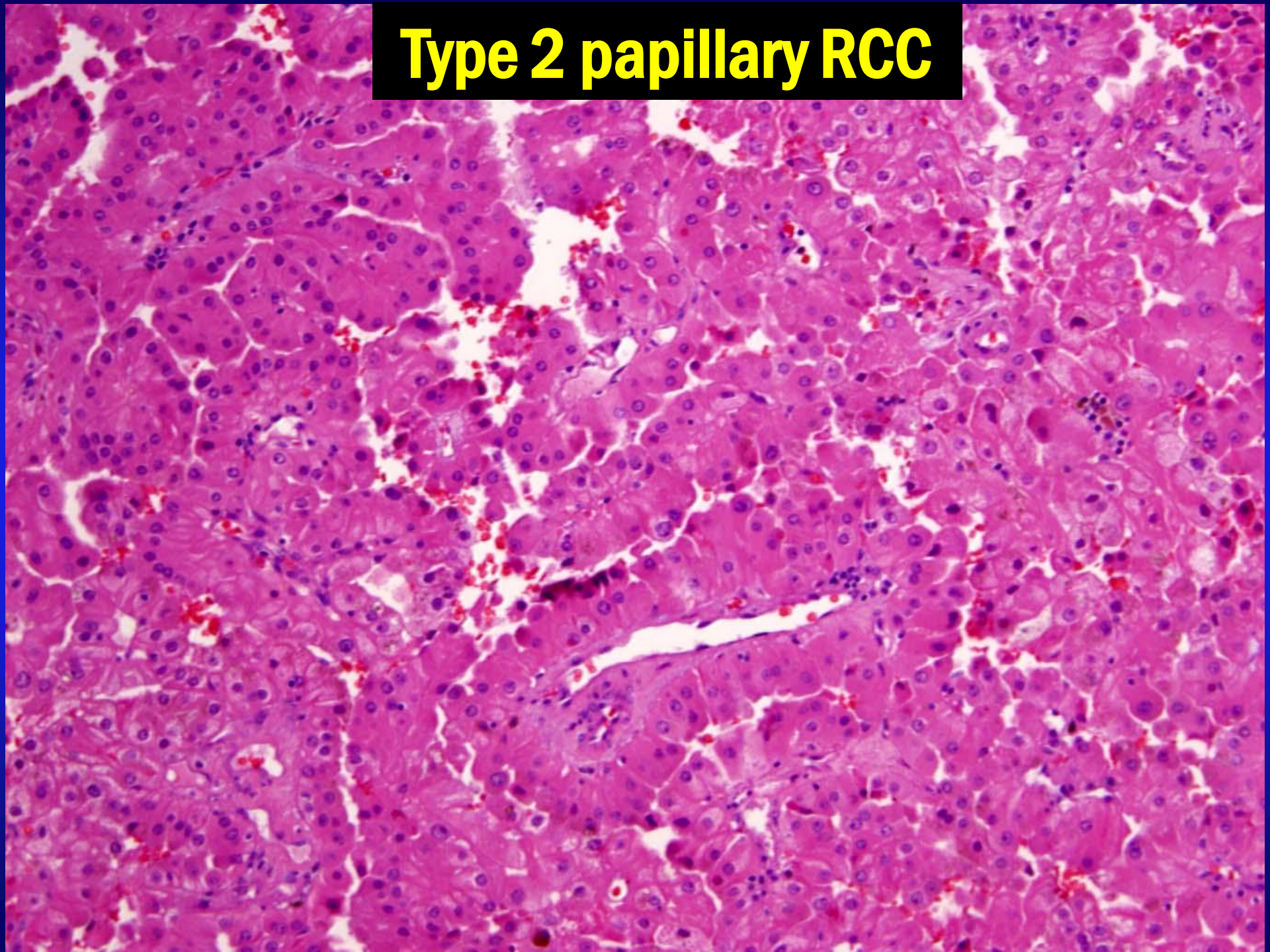


- The second most common type RCC
- Cytogenetic changes: +7, +17, -Y
  - Met protooncogene
- More frequent regional nodal metastasis
  - Prognosis variable

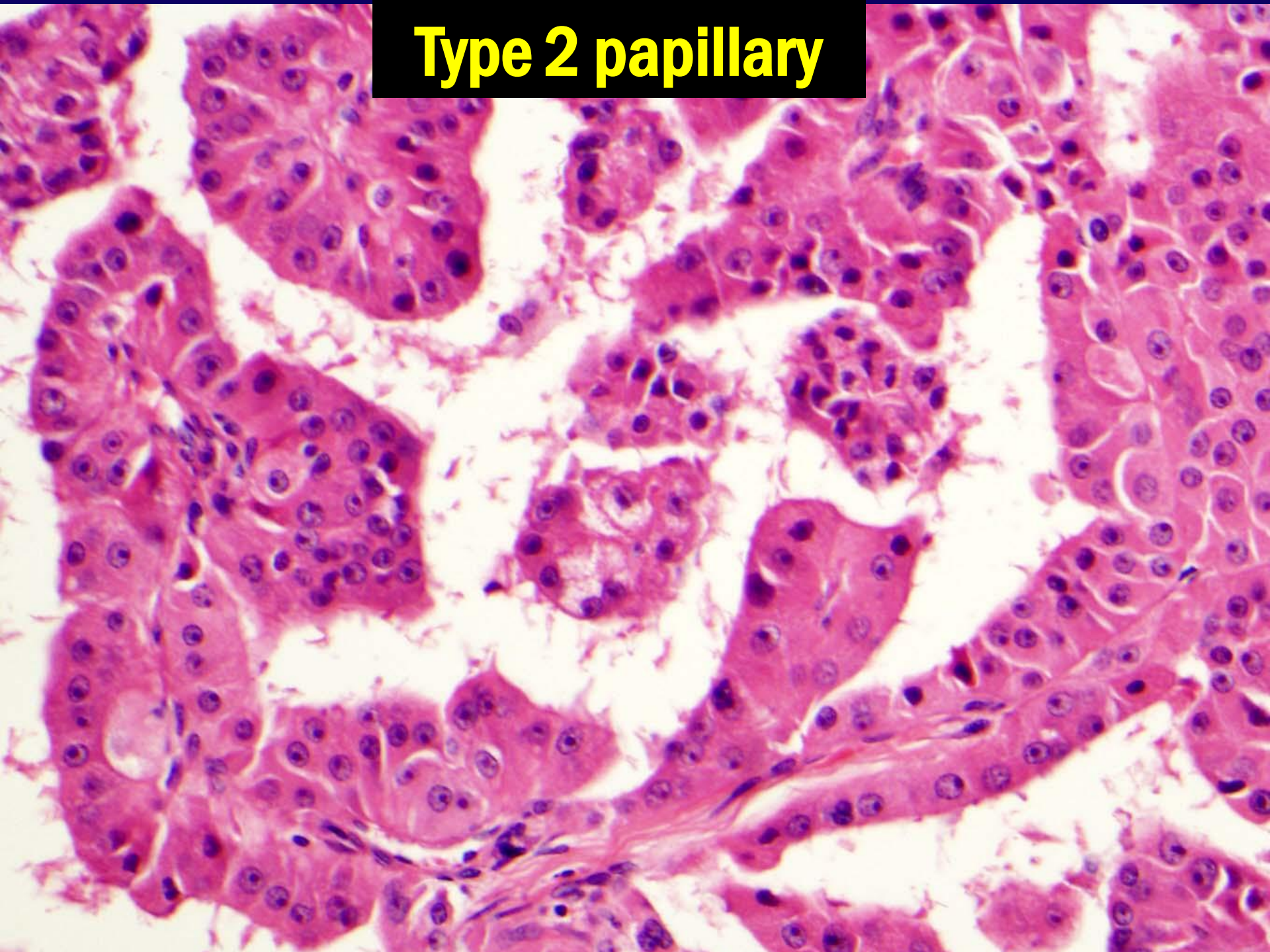
# Type 1 papillary RCC



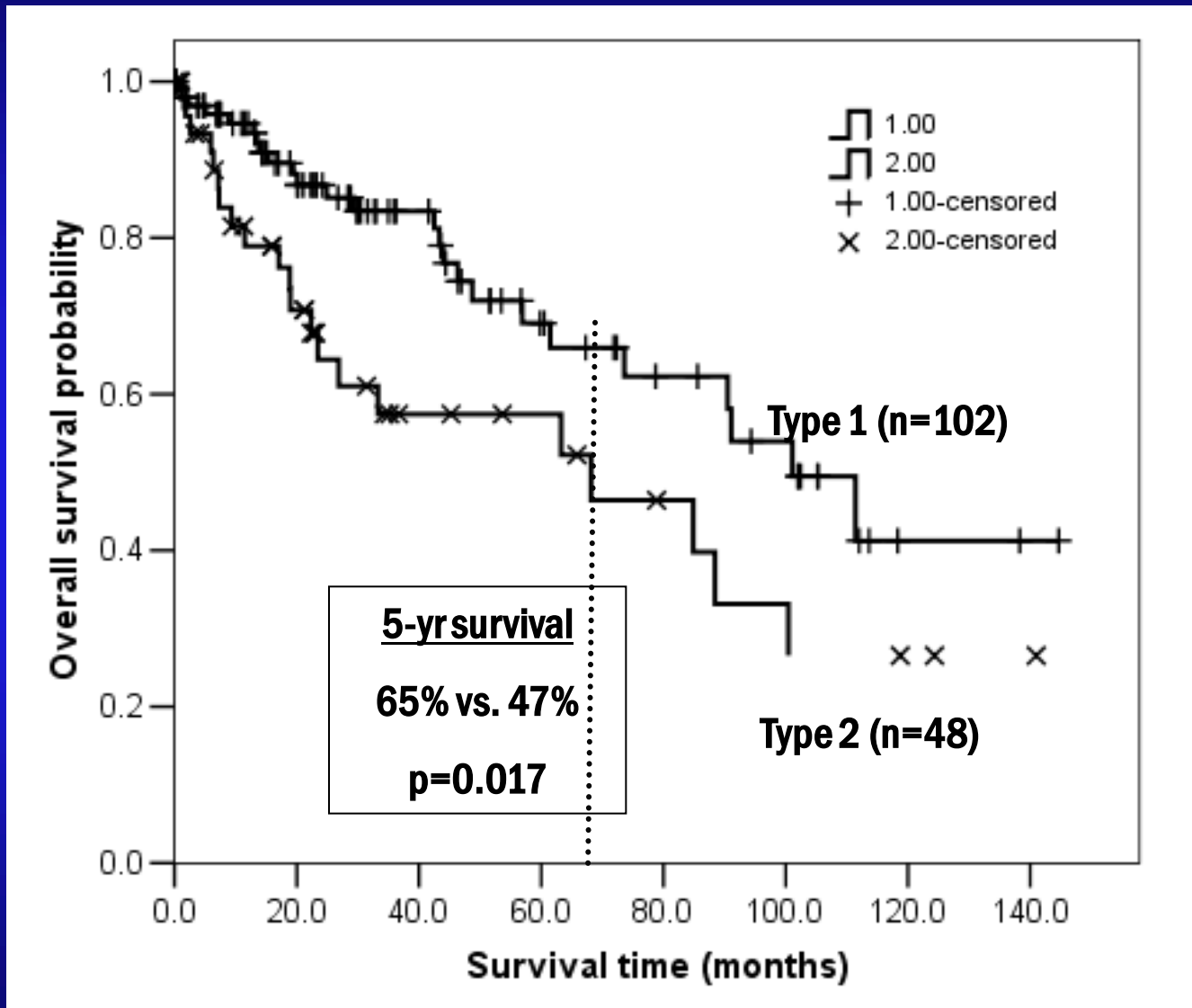
# Type 2 papillary RCC



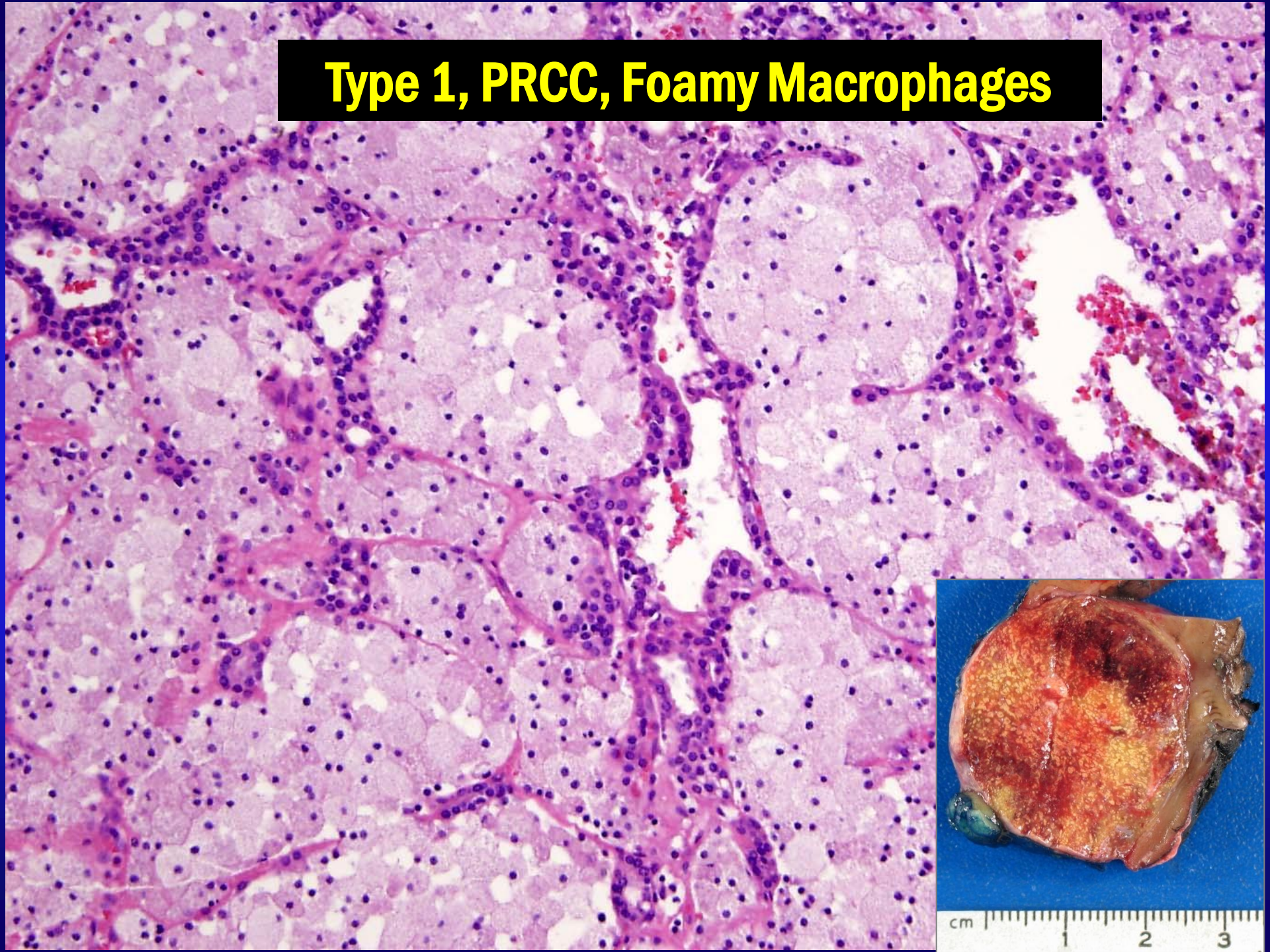
# Type 2 papillary



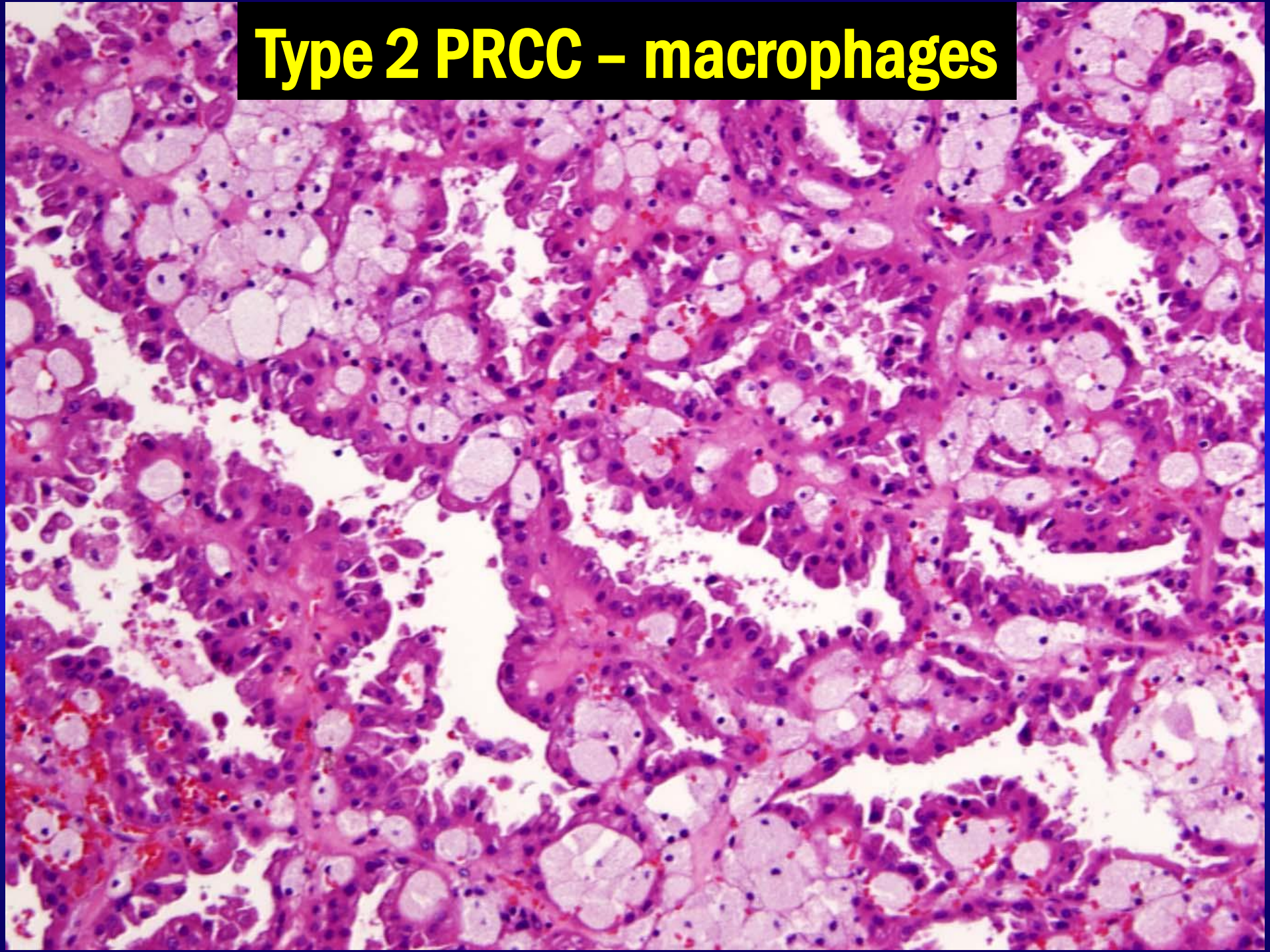
# PRCC, type 1 vs. type 2



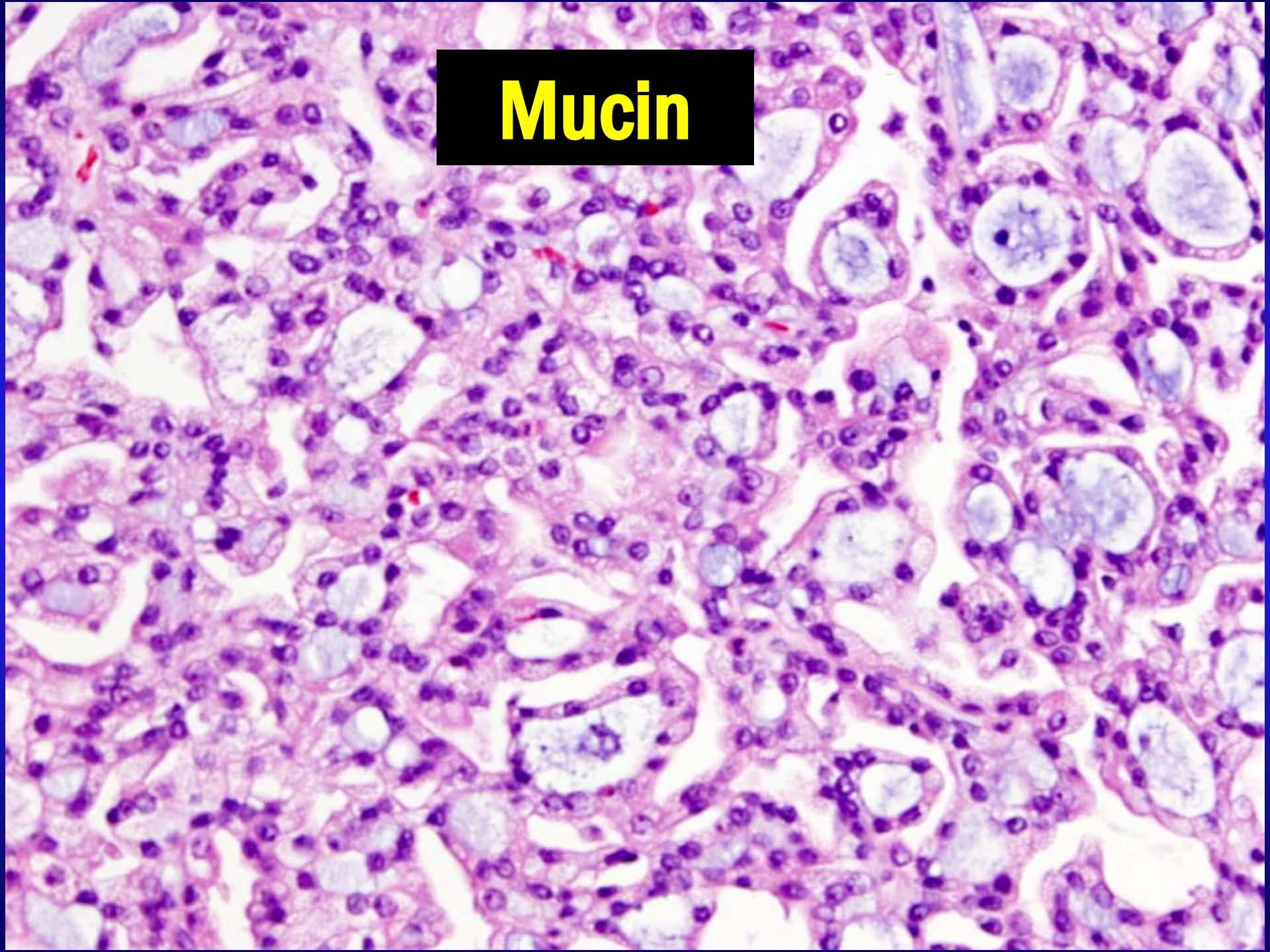
# Type 1, PRCC, Foamy Macrophages



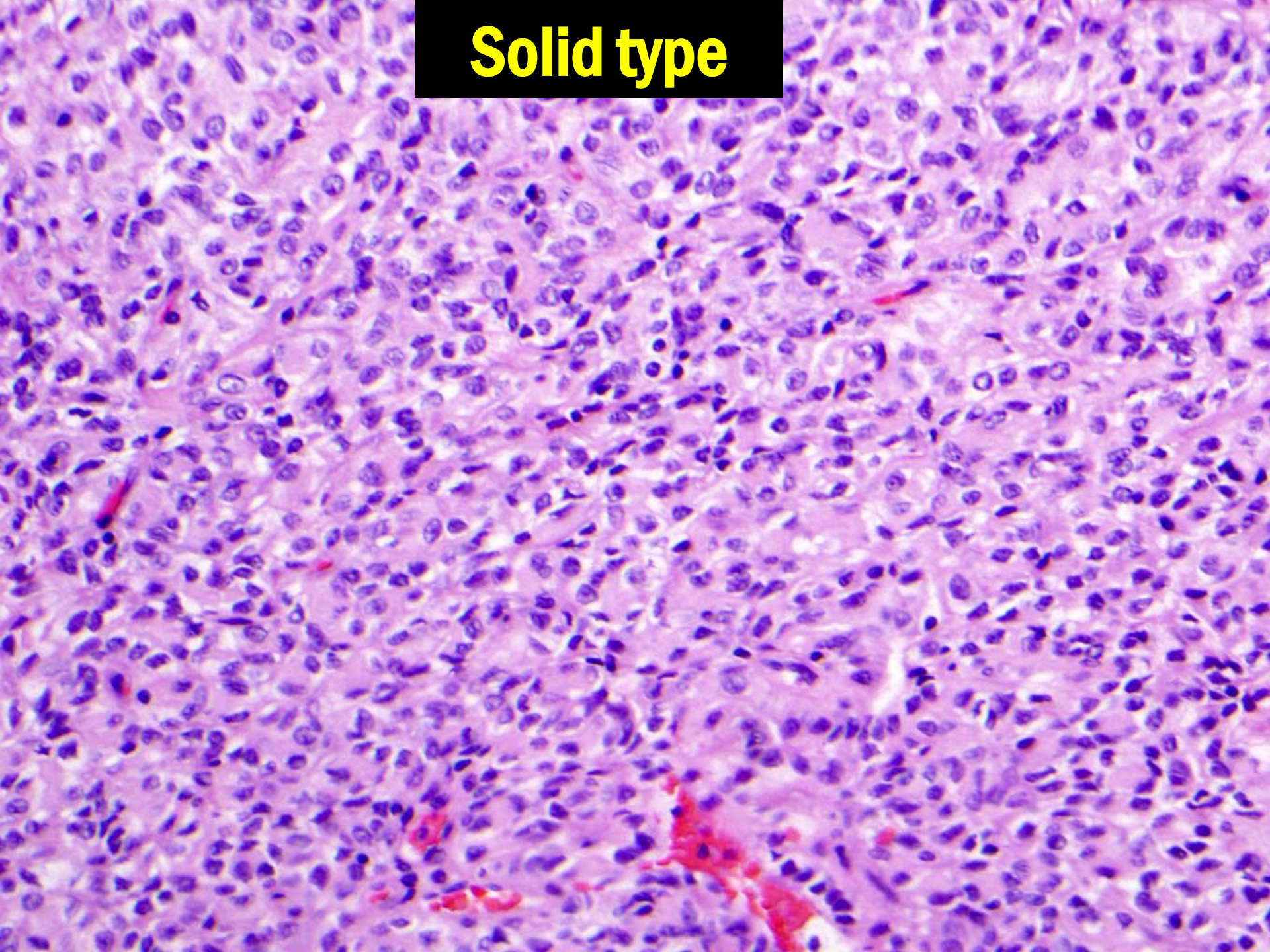
# Type 2 PRCC – macrophages



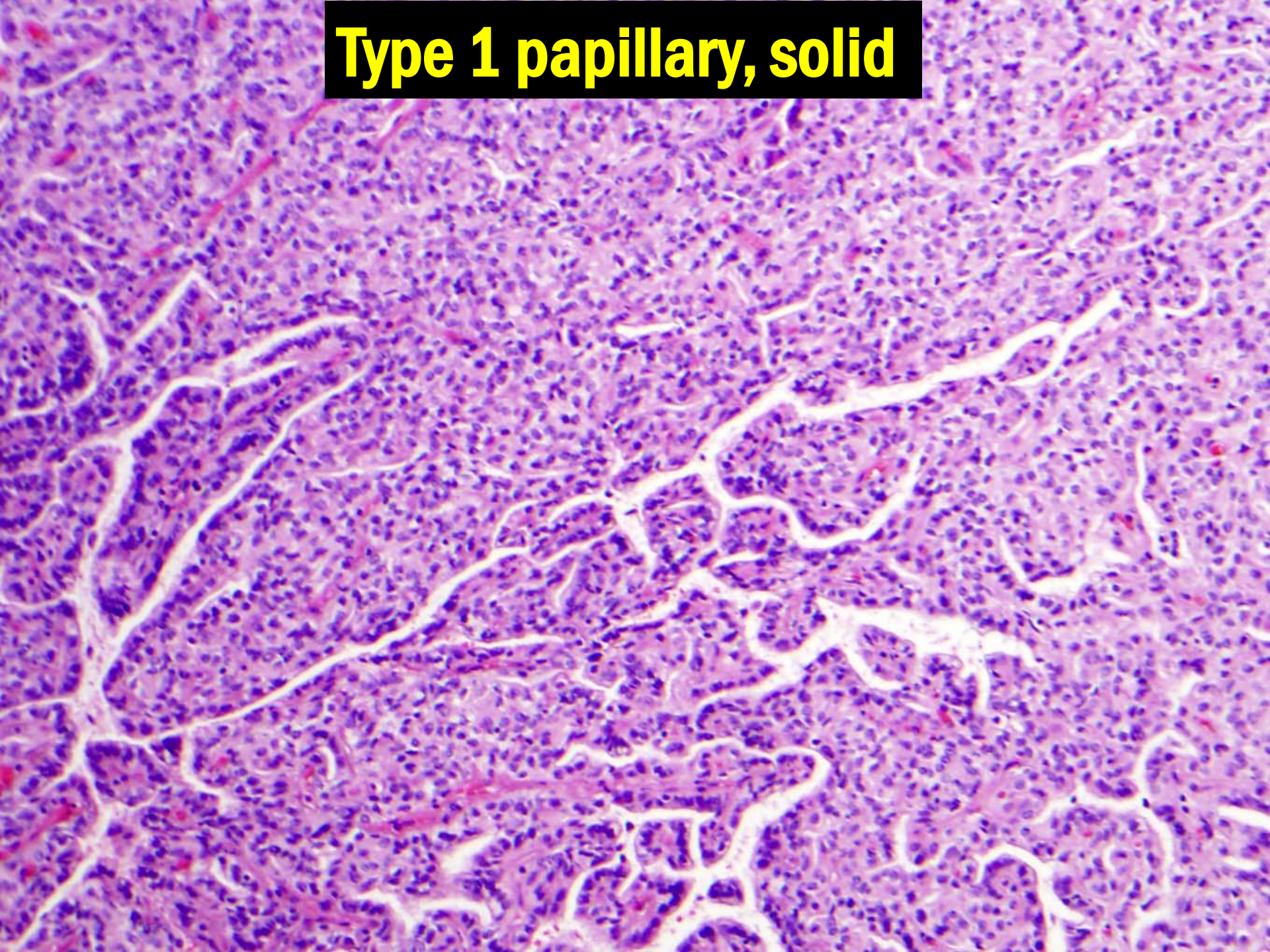
**Mucin**



**Solid type**

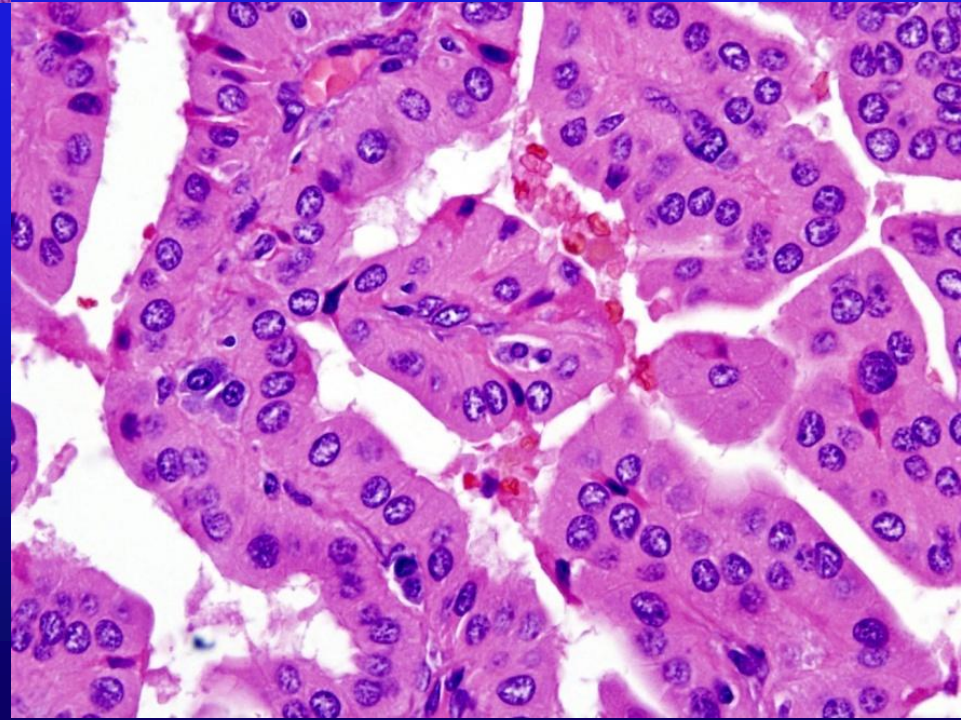
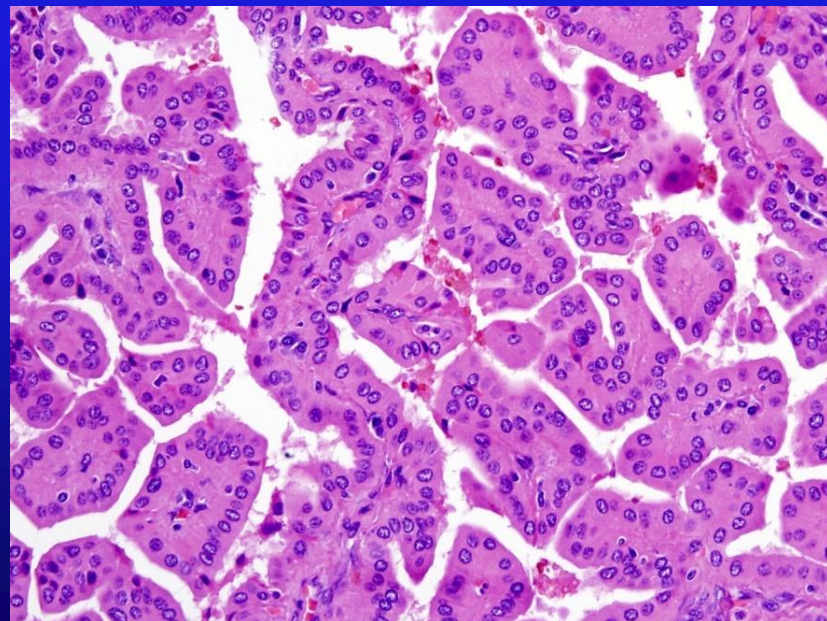
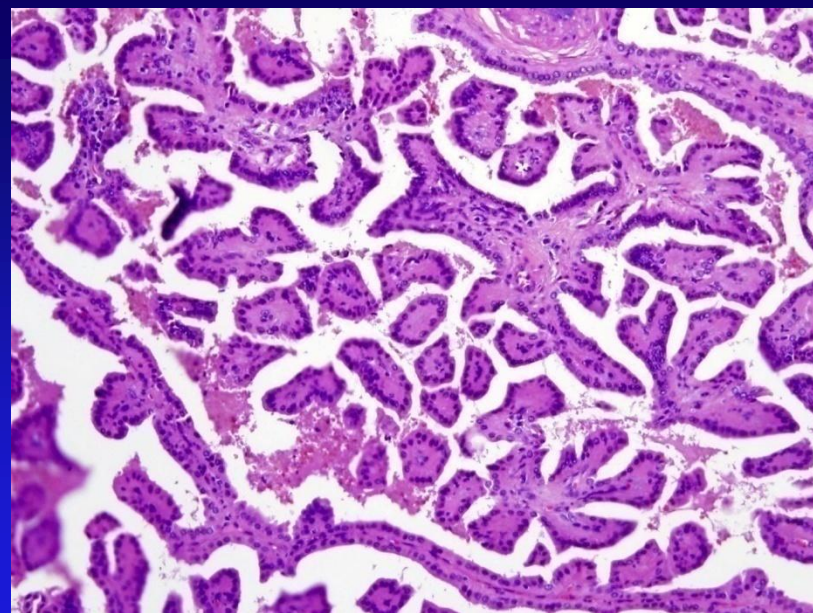
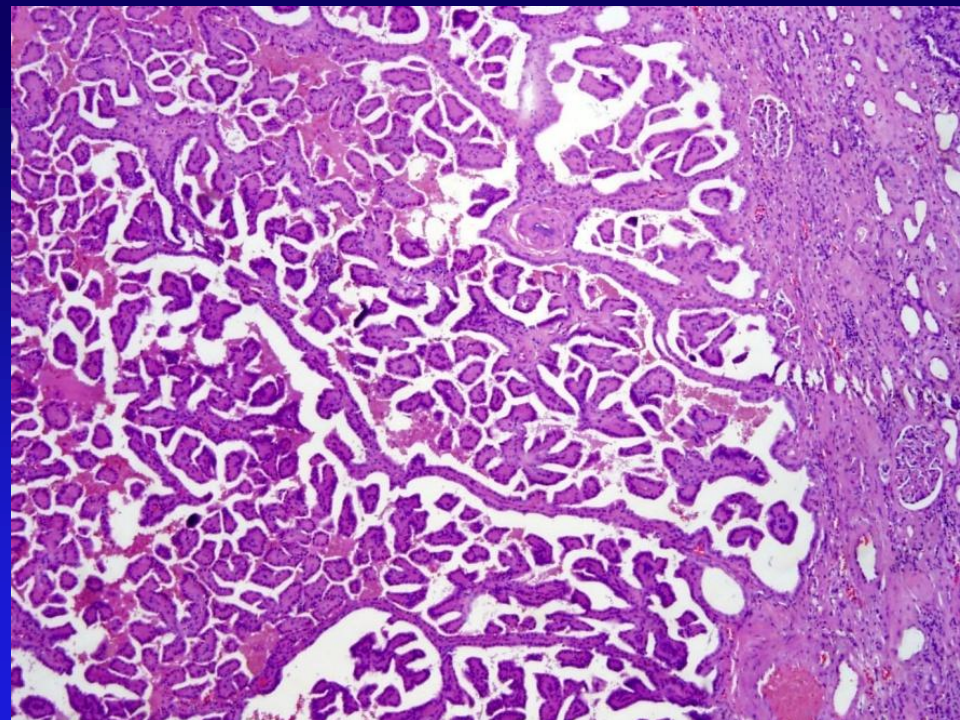


**Type 1 papillary, solid**



# Issues of Papillary RCC

- **Morphologic variation of PRCC**
- **Clear cell RCC, particularly higher grade can have pseudopapillary pattern**
- **Mixed type 1 and type 2**
- **Oncocytic papillary RCC?**



# Oncocytic Papillary RCC

May be a “distinct” subgroup

## Kunju et al. (2008)

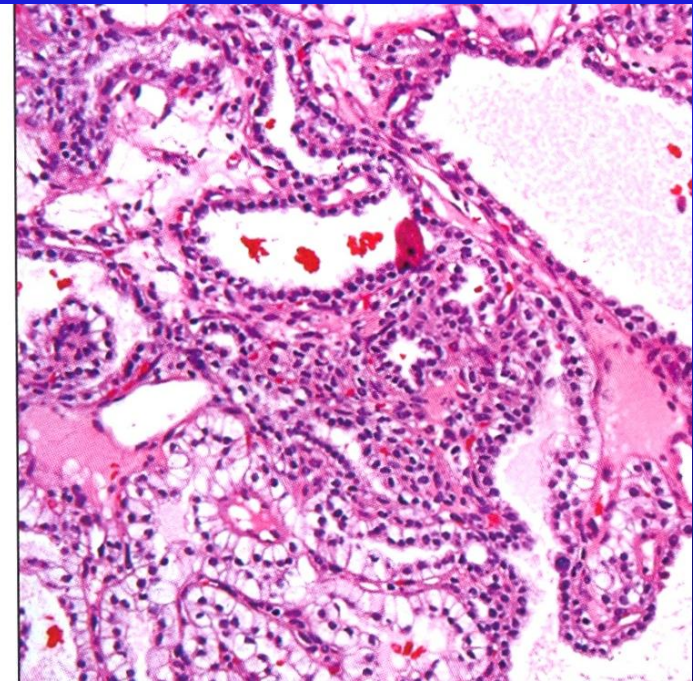
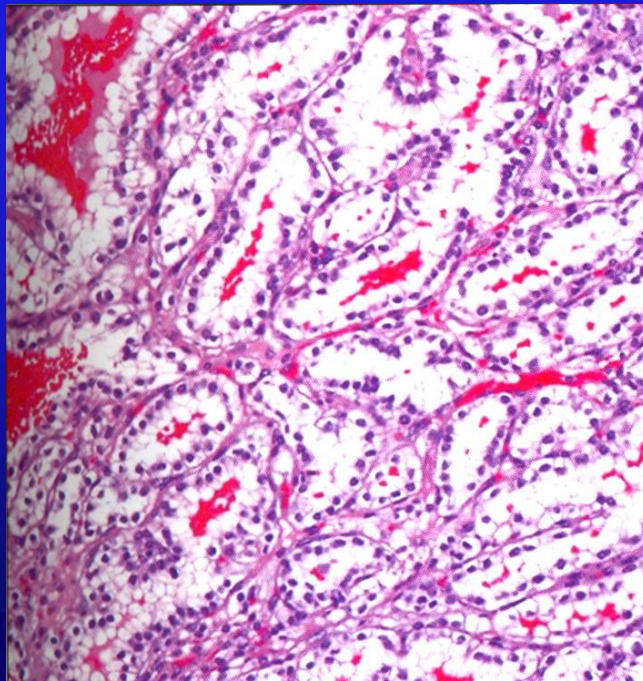
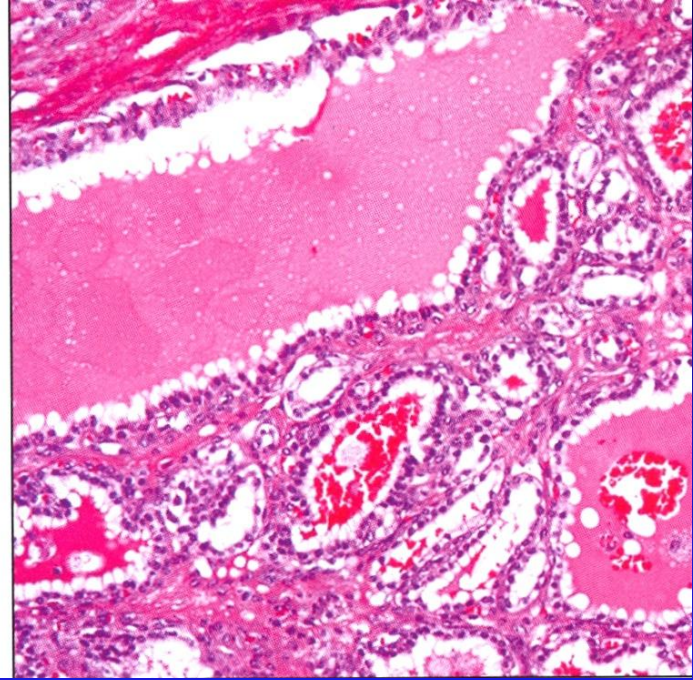
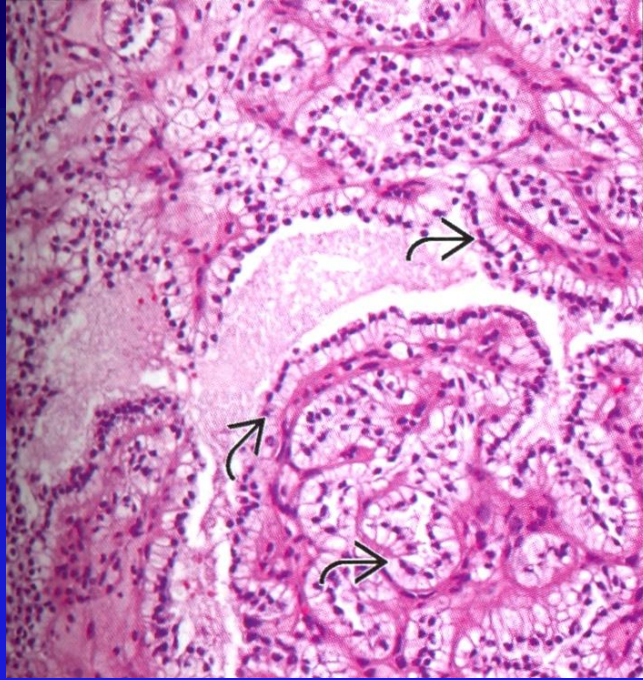
- Smaller tumor (mean 2.0 cm)
- IHC: CK7+ (7/7), CD10+ (7/7), AMACR+ (5/7)
- FISH: all trisomy 7, 17
- No recurrence or metastasis in 22 months

## Park et al., (2009)

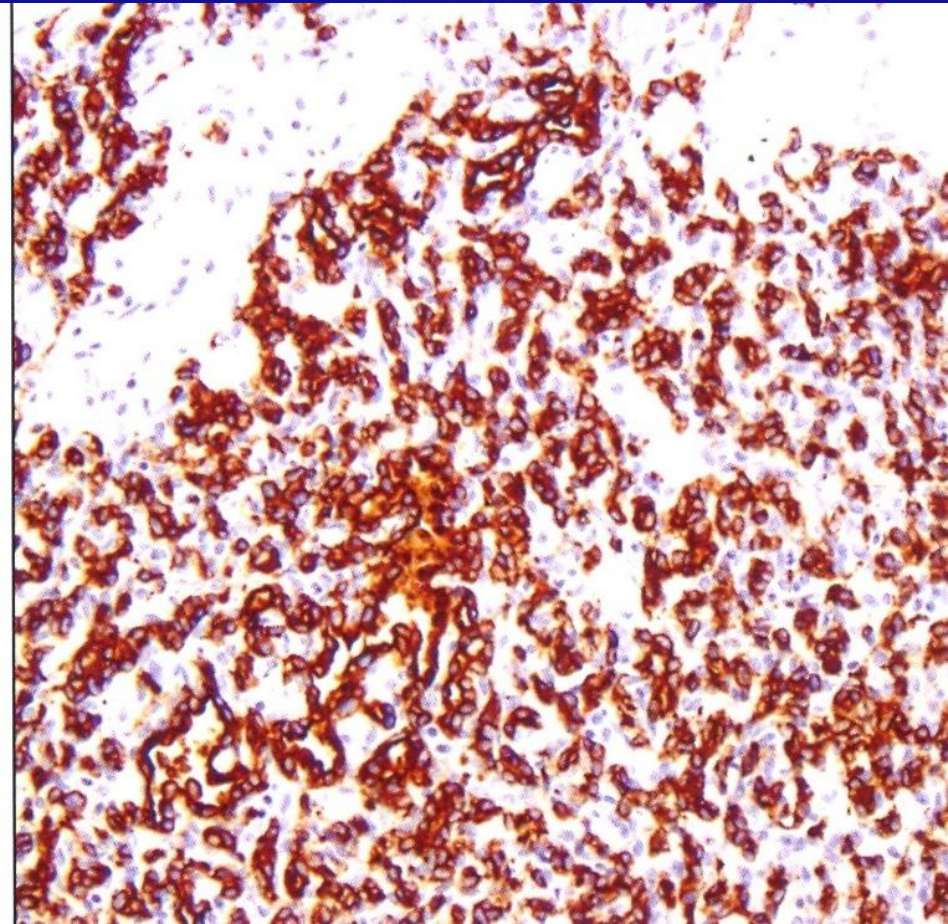
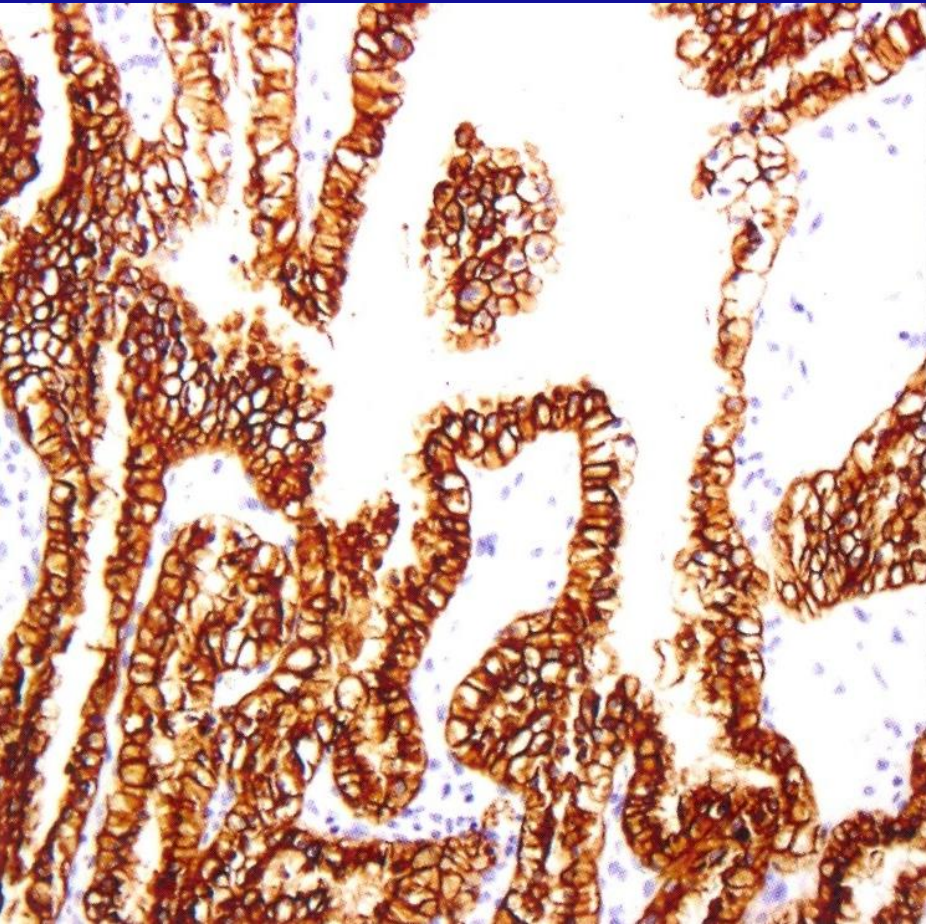
- Histology: nuclei polarized to surface of papillae
- IHC: AMACR+ (7/7), CK7+ (7/7), CD15+ (6/7)
- Cytogenetics: 3p+, 11q+, 17q+, 4q-
- No recurrence or metastases in 3 years

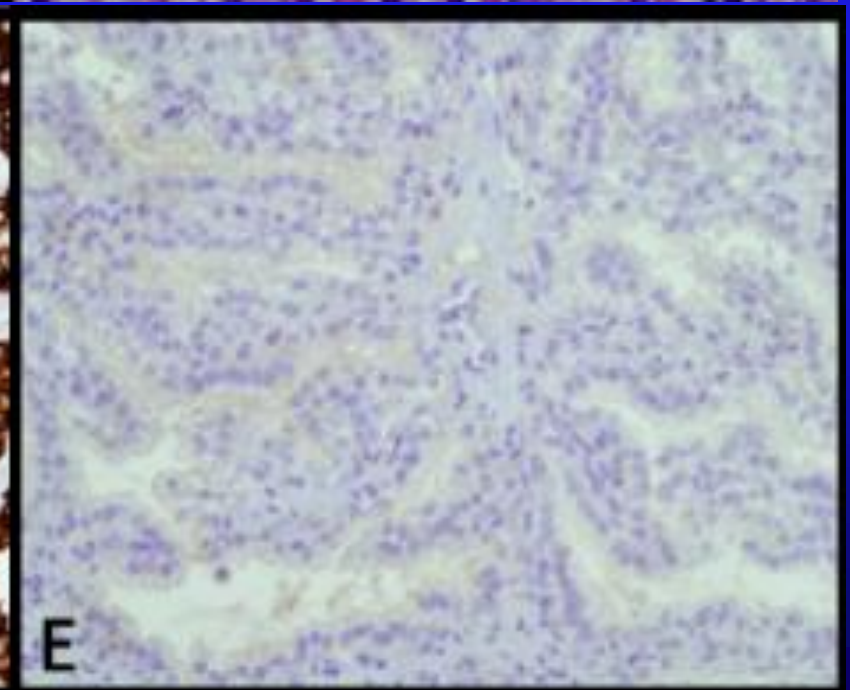
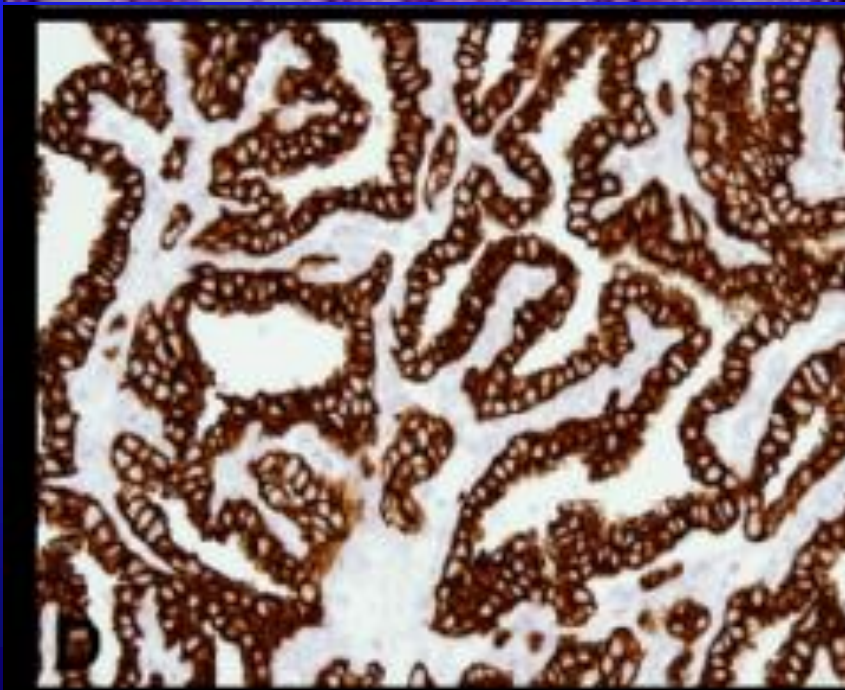
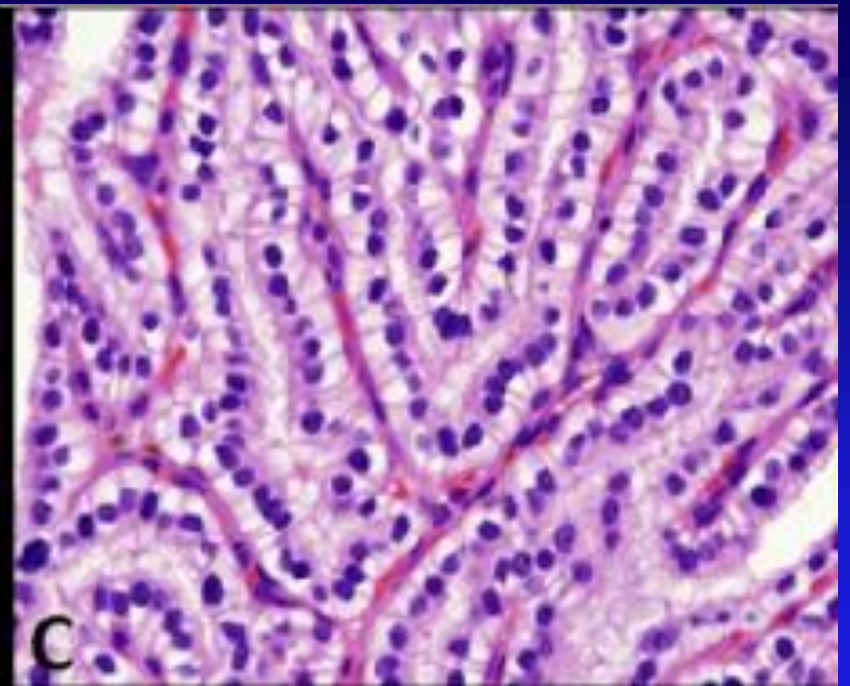
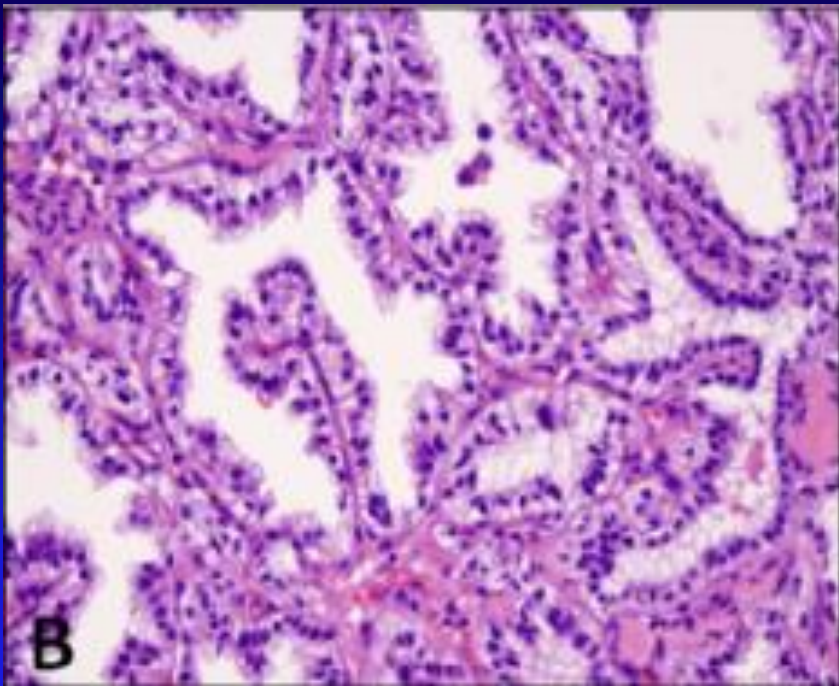
# Clear cell papillary RCC

- Both end stage renal disease and also seen in non-end-stage setting
- Unicentric and occasionally multicentric
- Most are small pT1 with rare pT3
- No LN or other sites metastasis
- Clear cells with low NG; papillary/tubular-acinar; nuclei in linear arrangement away from basal aspect of cells
- AMACR and CD10-; CK7, CA9 and HMCK +



# CK7 + in both papillary and tubular areas

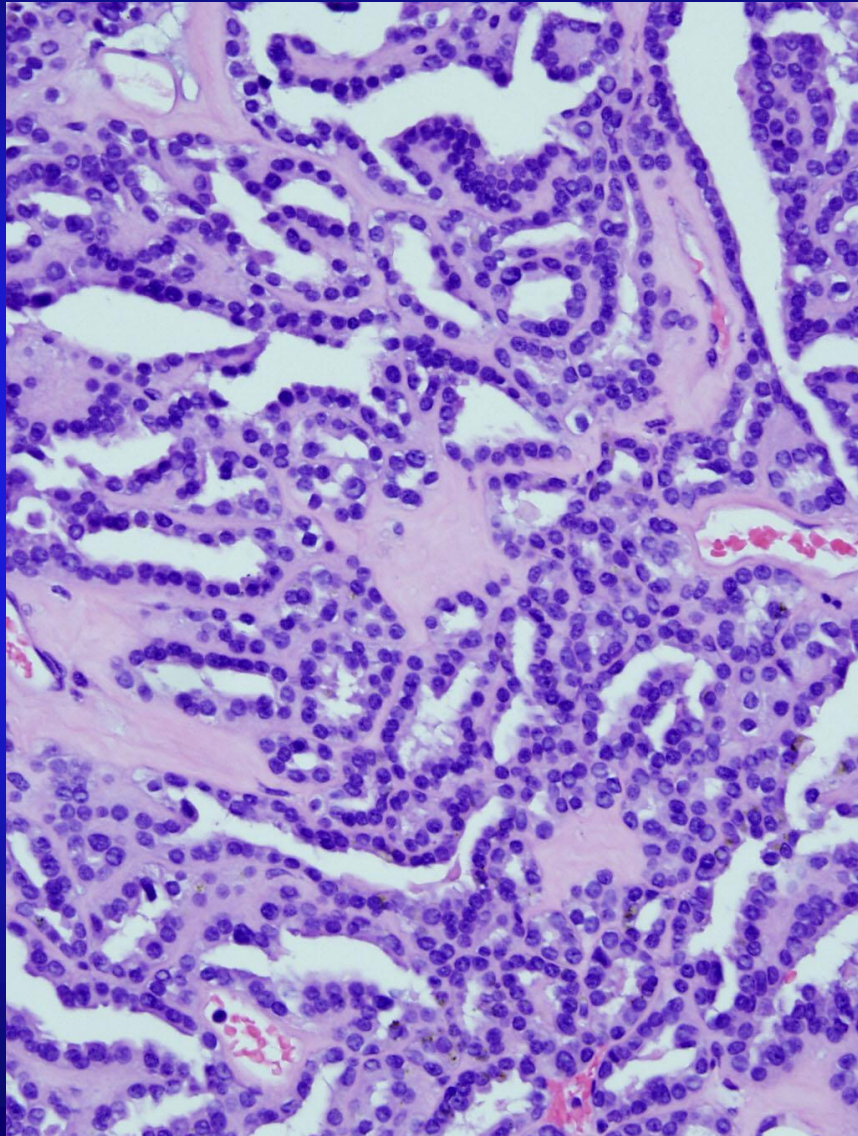




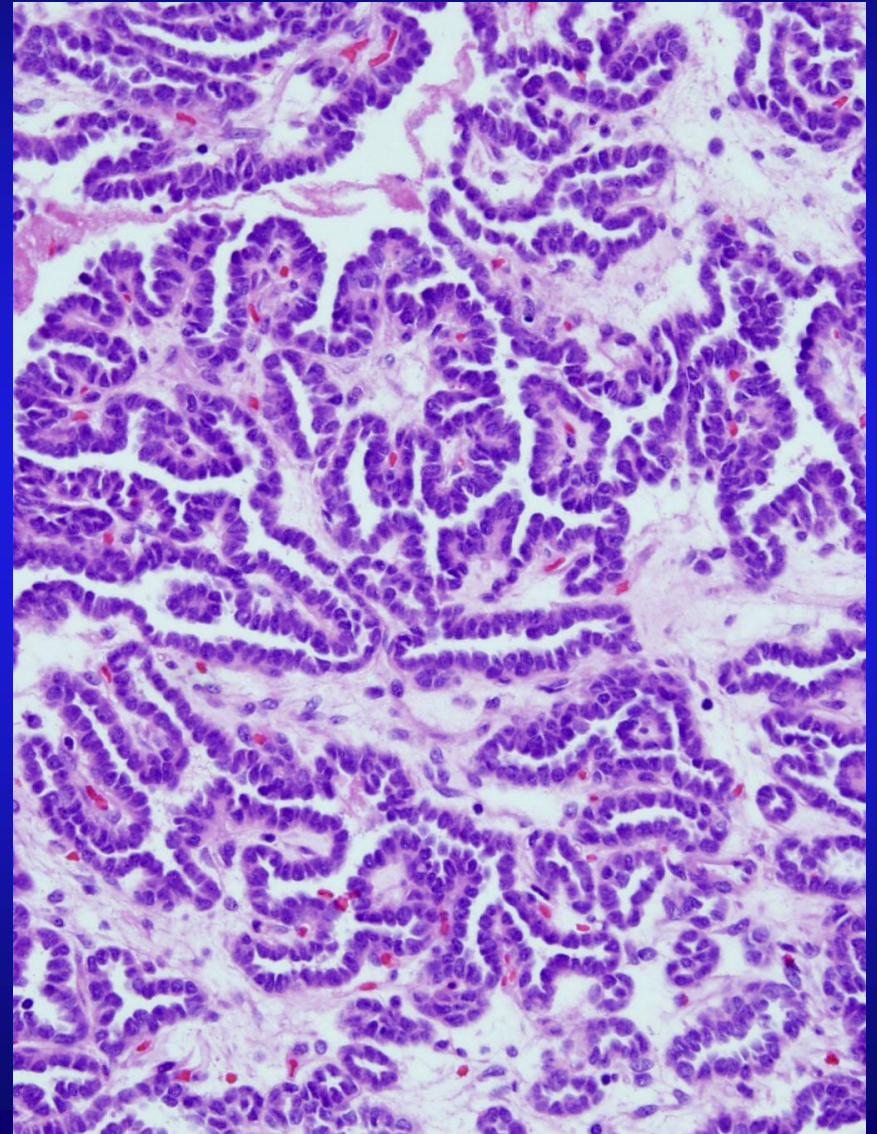
# **Metanephric adenoma**

- **rare benign renal neoplasm**
- **Similar to Wilms tumor, papillary RCC, type 1**
- **Size 0.3-15 cm (mean 5.5 cm)**
- **Polycythemia and frequent calcifications**
- **Should be exclude papillary RCC before make metanephric adenoma diagnosis**

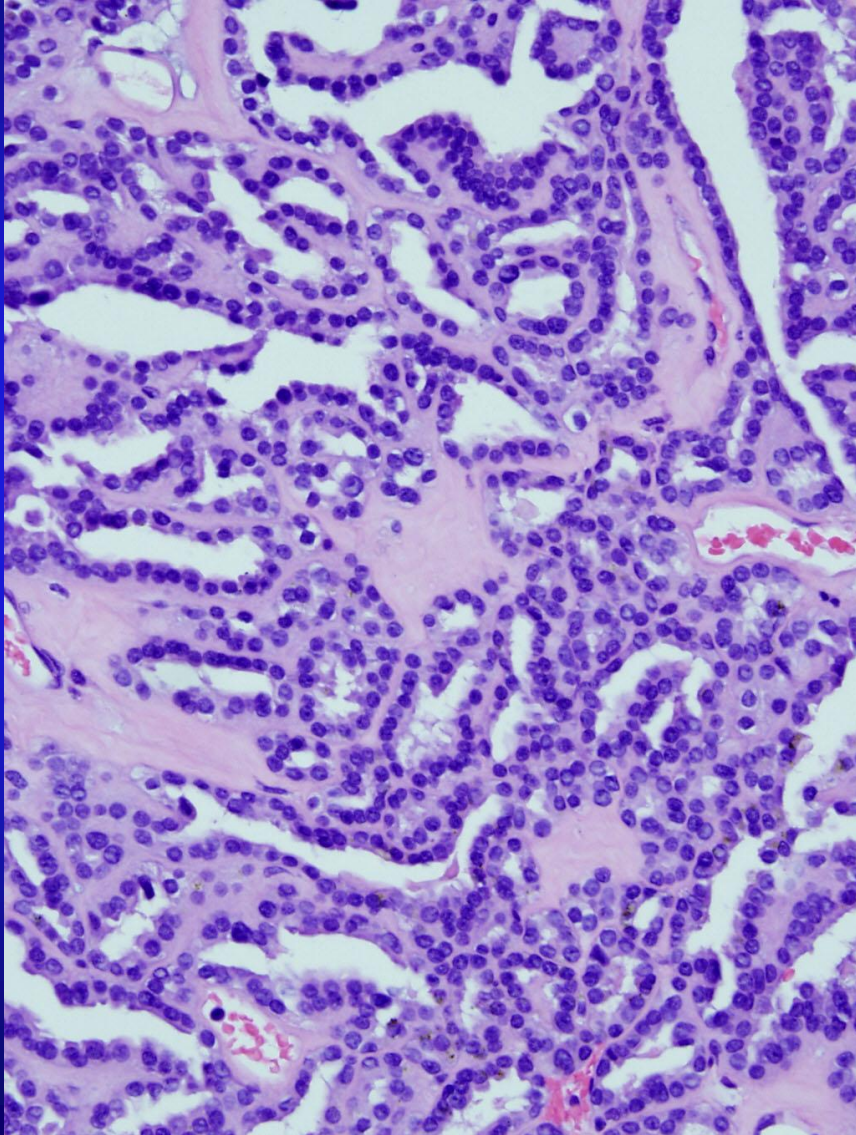
# Papillary RCC



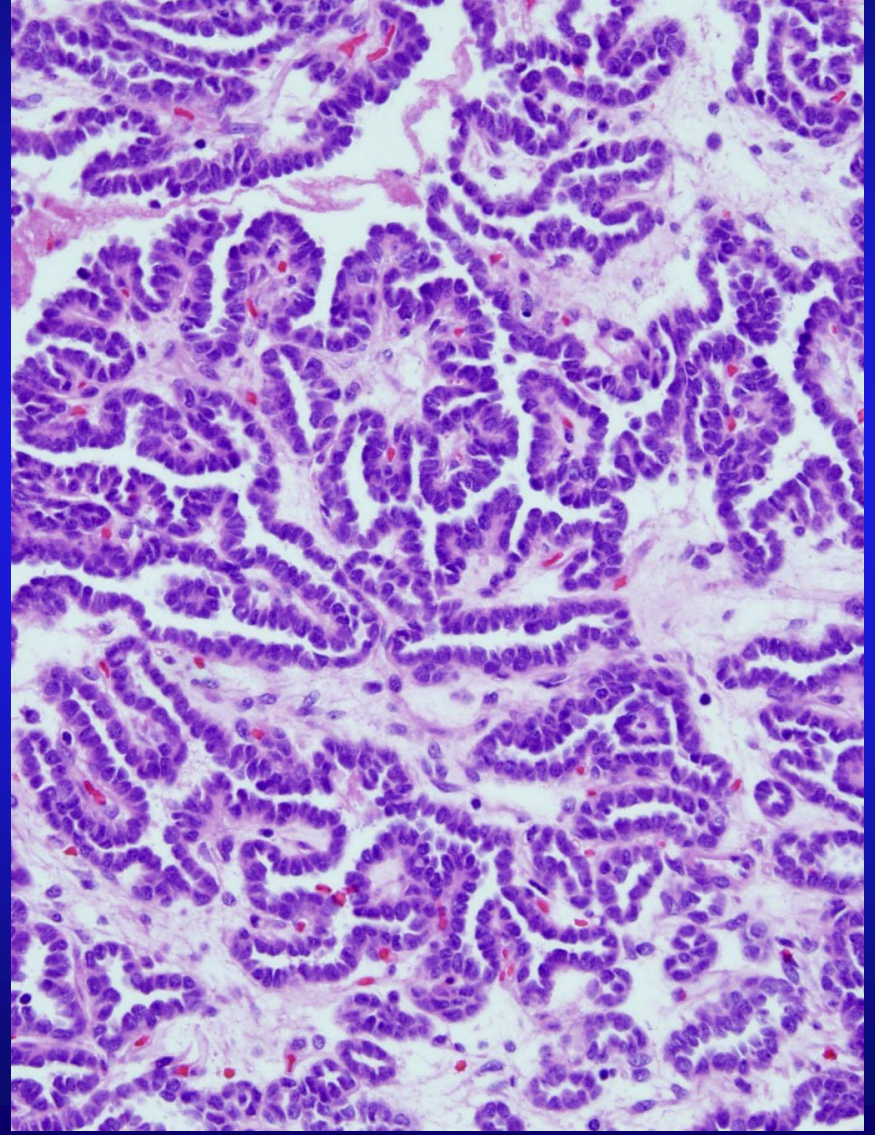
# Metanephric Adenoma

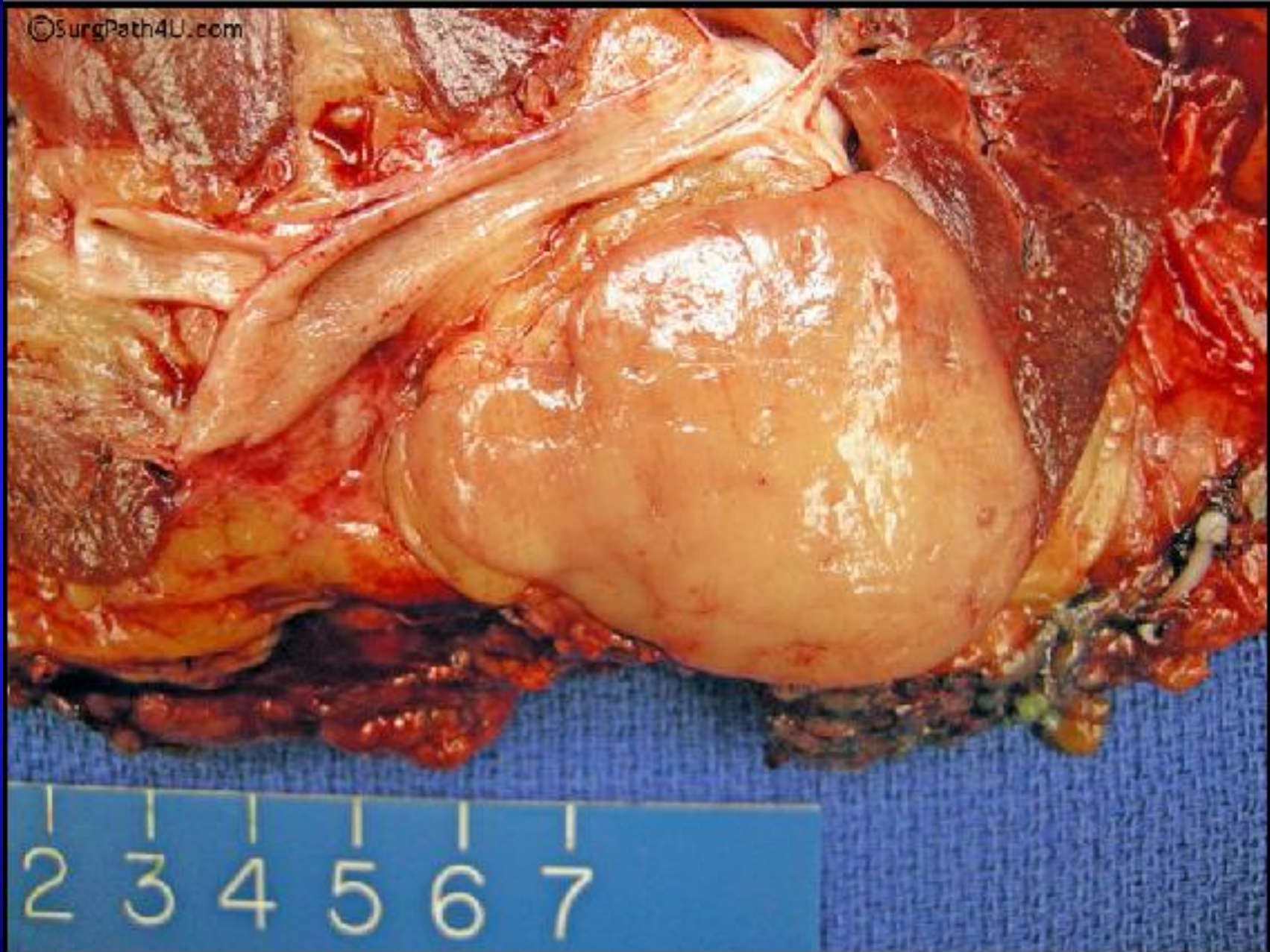


## Papillary RCC



## Metanephric Adenoma





# Morphologic Overlapping Metanephric Adenoma (MA) and Papillary RCC

	Papillary Pattern	Glomeruloid Pattern	Solid Pattern	Psammoma Bodies	Macrophages
MA	6/8 (75%)	4/8 (50%)	8/8 (100%)	6/8 (75%)	1/8 (13%)
PRCC	11/11 (100%)	4/11 (36%)	7/11 (64%)	1/11 (9%)	7/11 (64%)

Moore B. Dance et al. 2008 CAP Poster

# Metanephric Adenoma vs. Papillary RCC

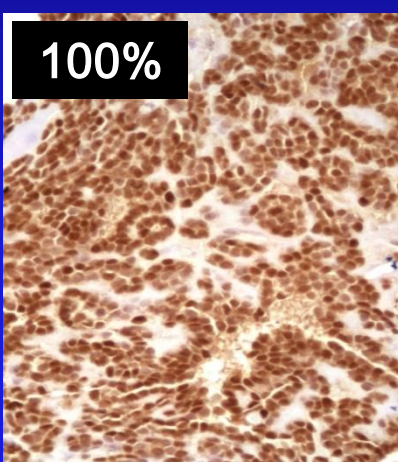
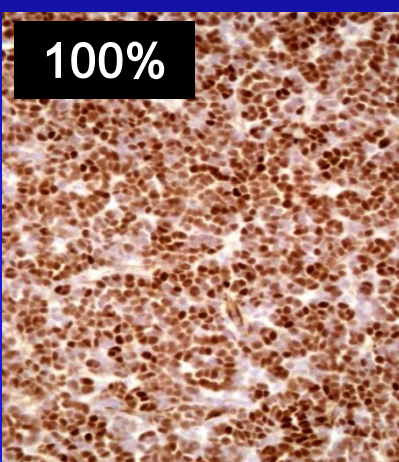
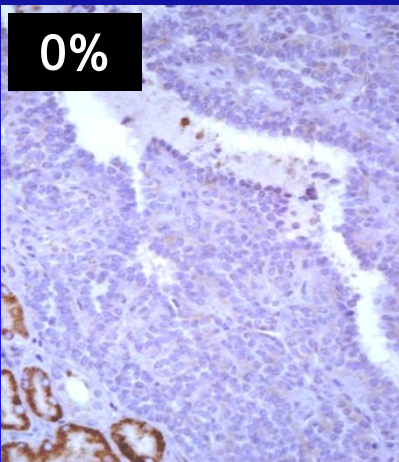
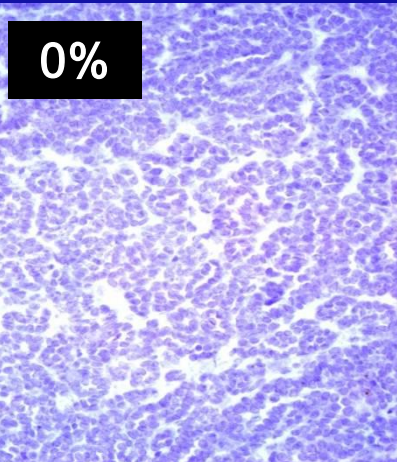
RCCm

AMACR

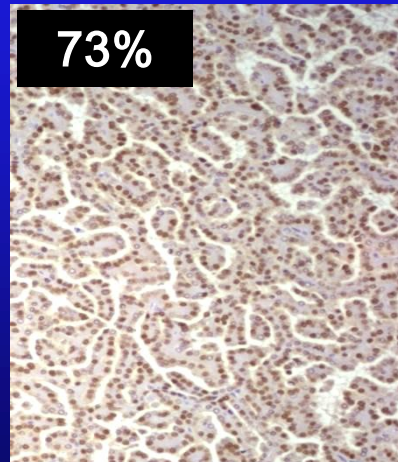
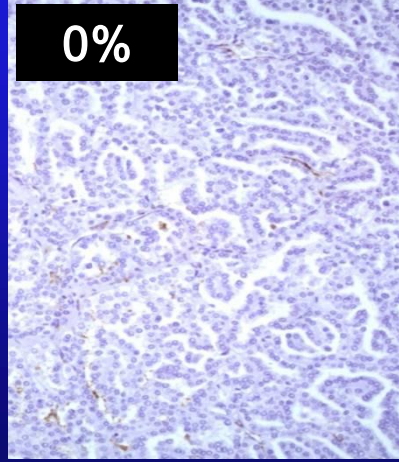
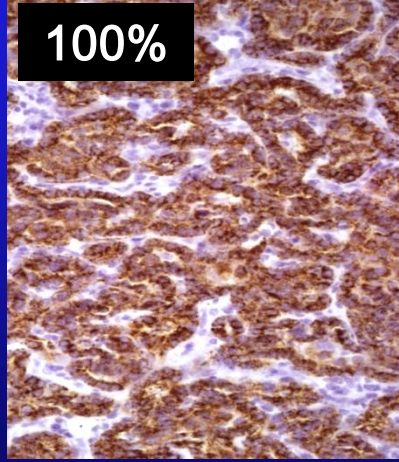
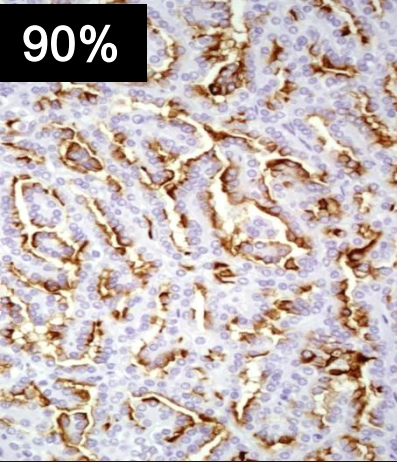
WT-1

PAX2

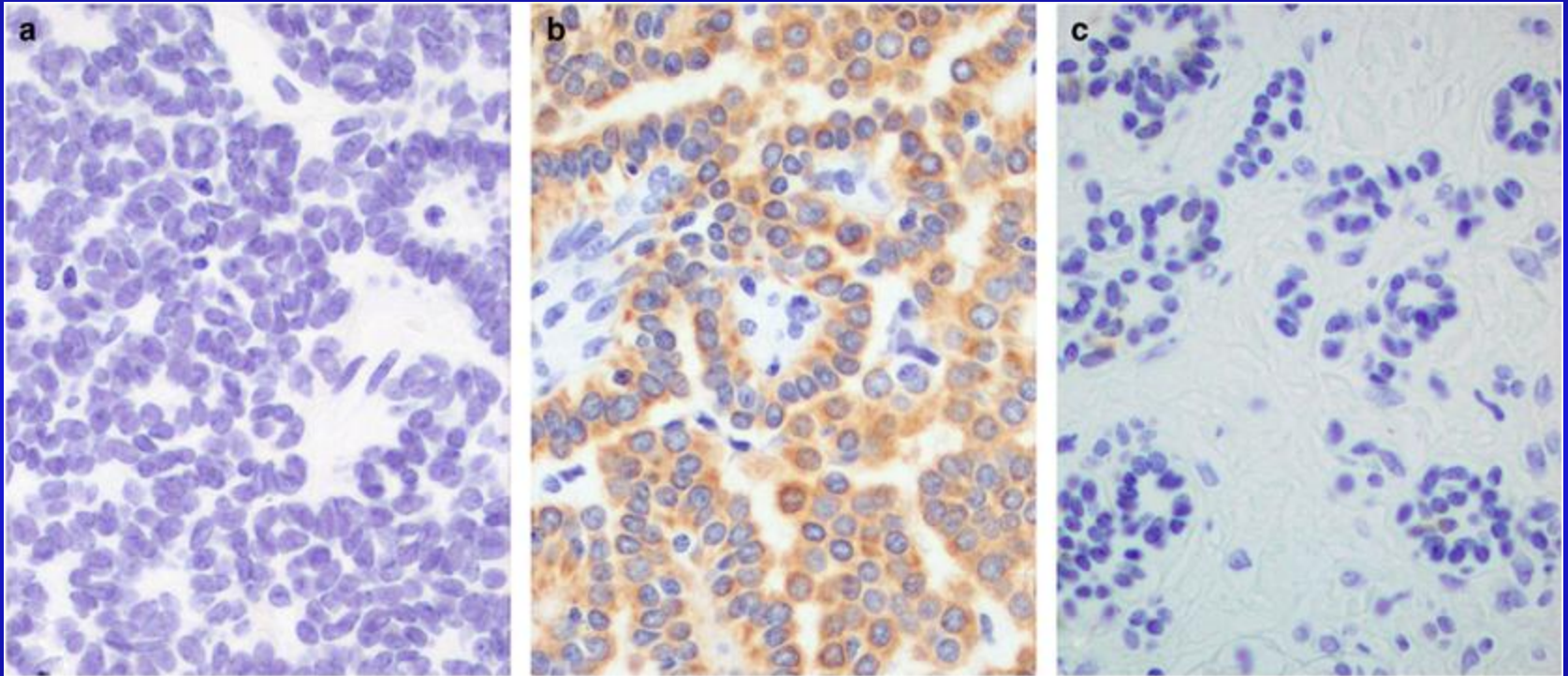
MA



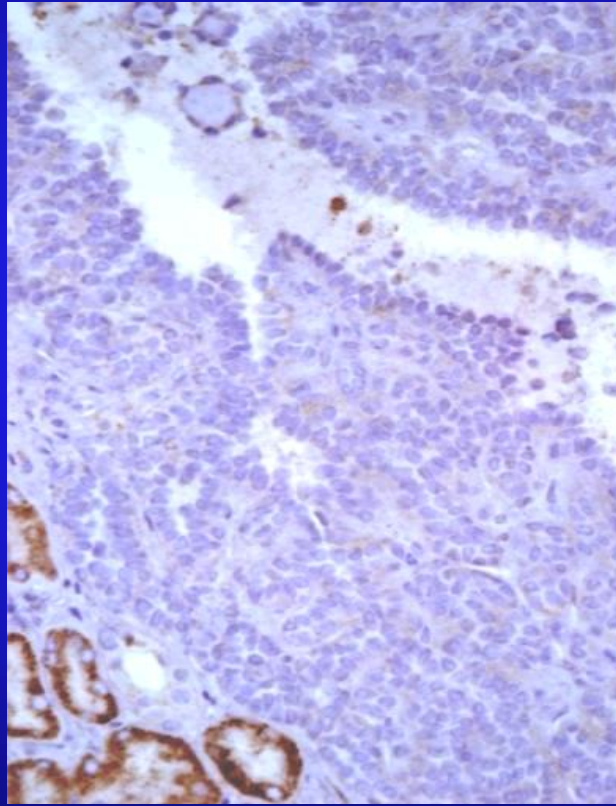
pRCC



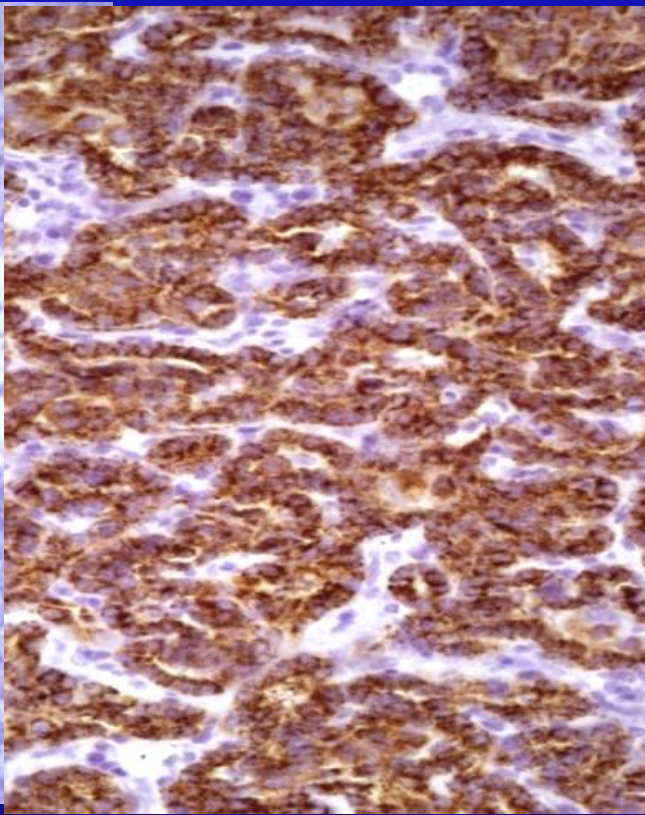
# CK7



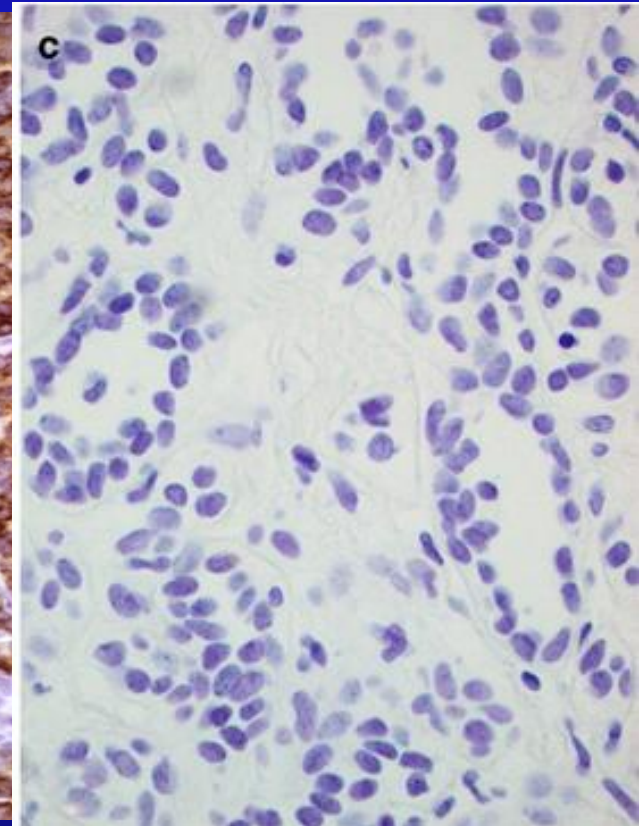
# AMACR



**MA**

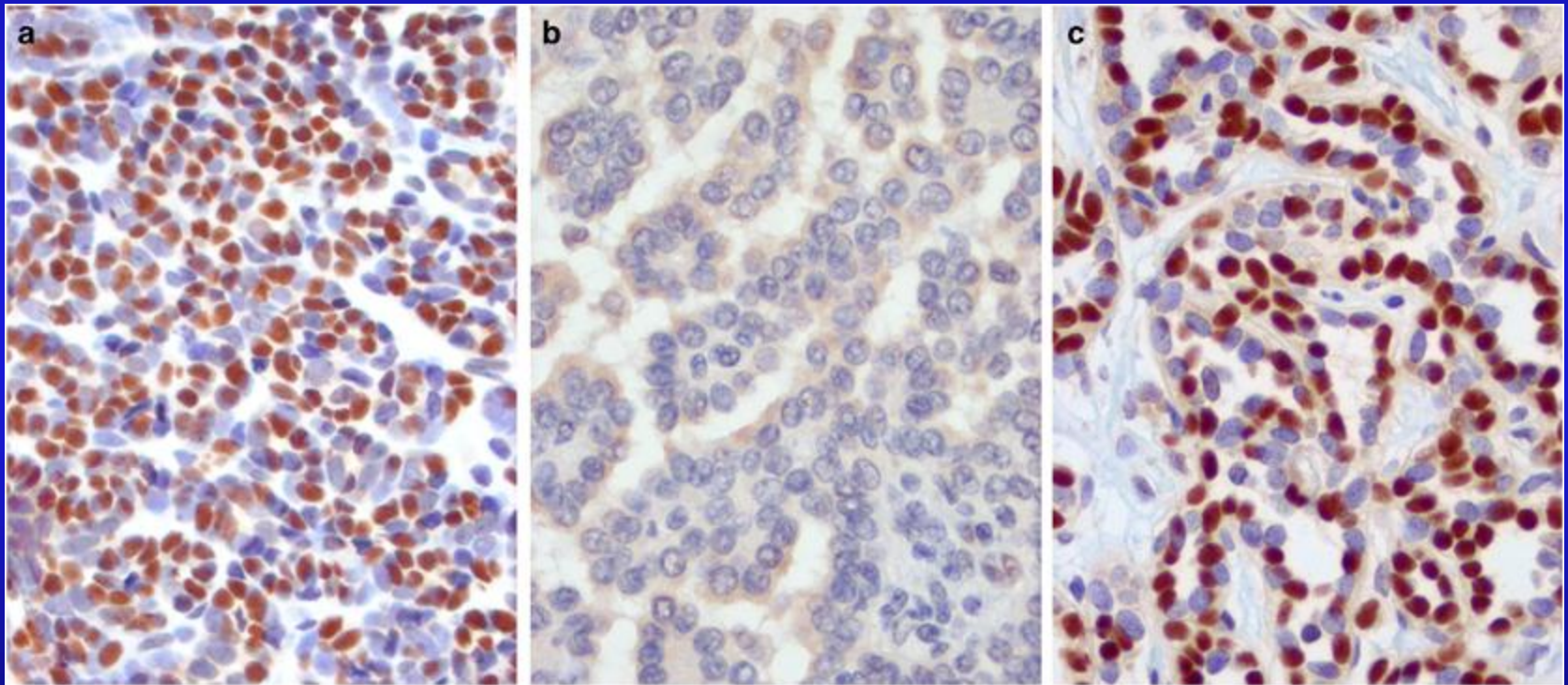


**pRCC**

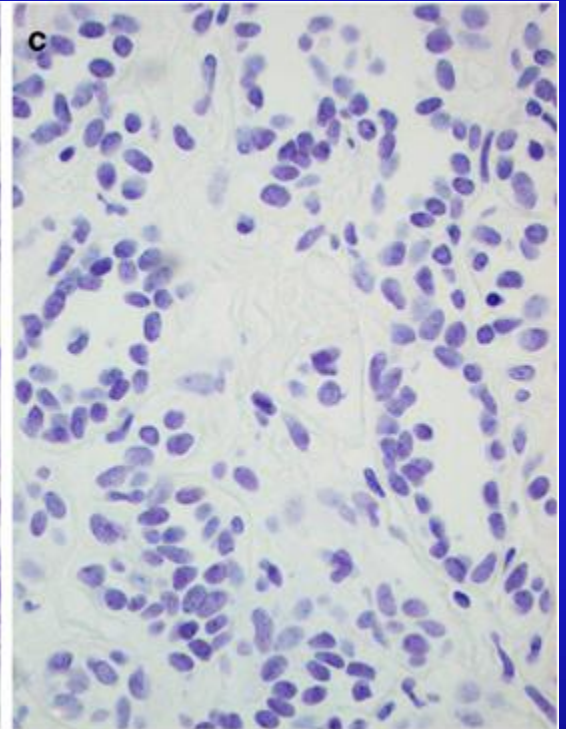
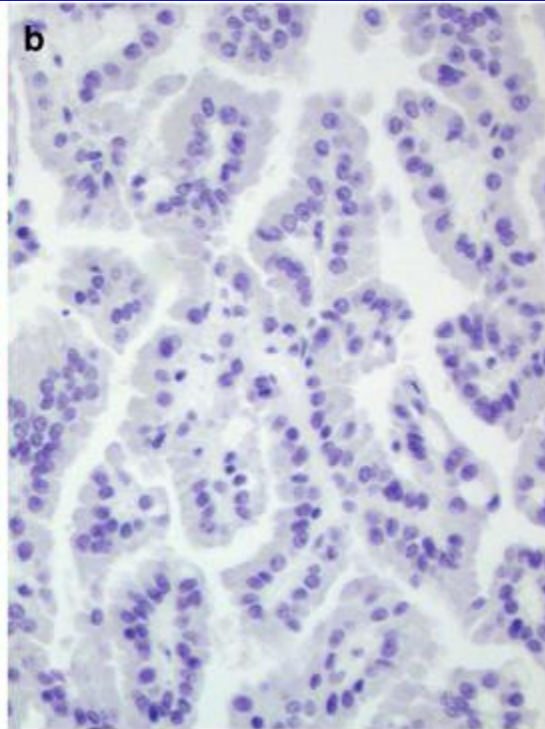
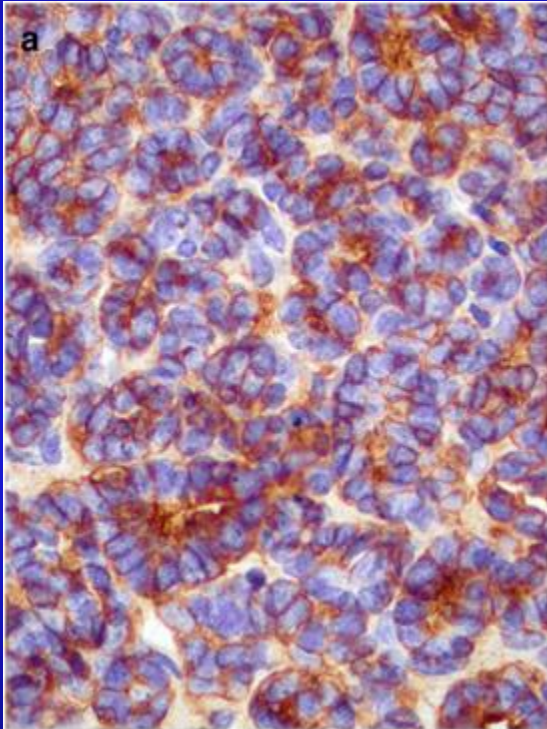


**WT**

# WT1

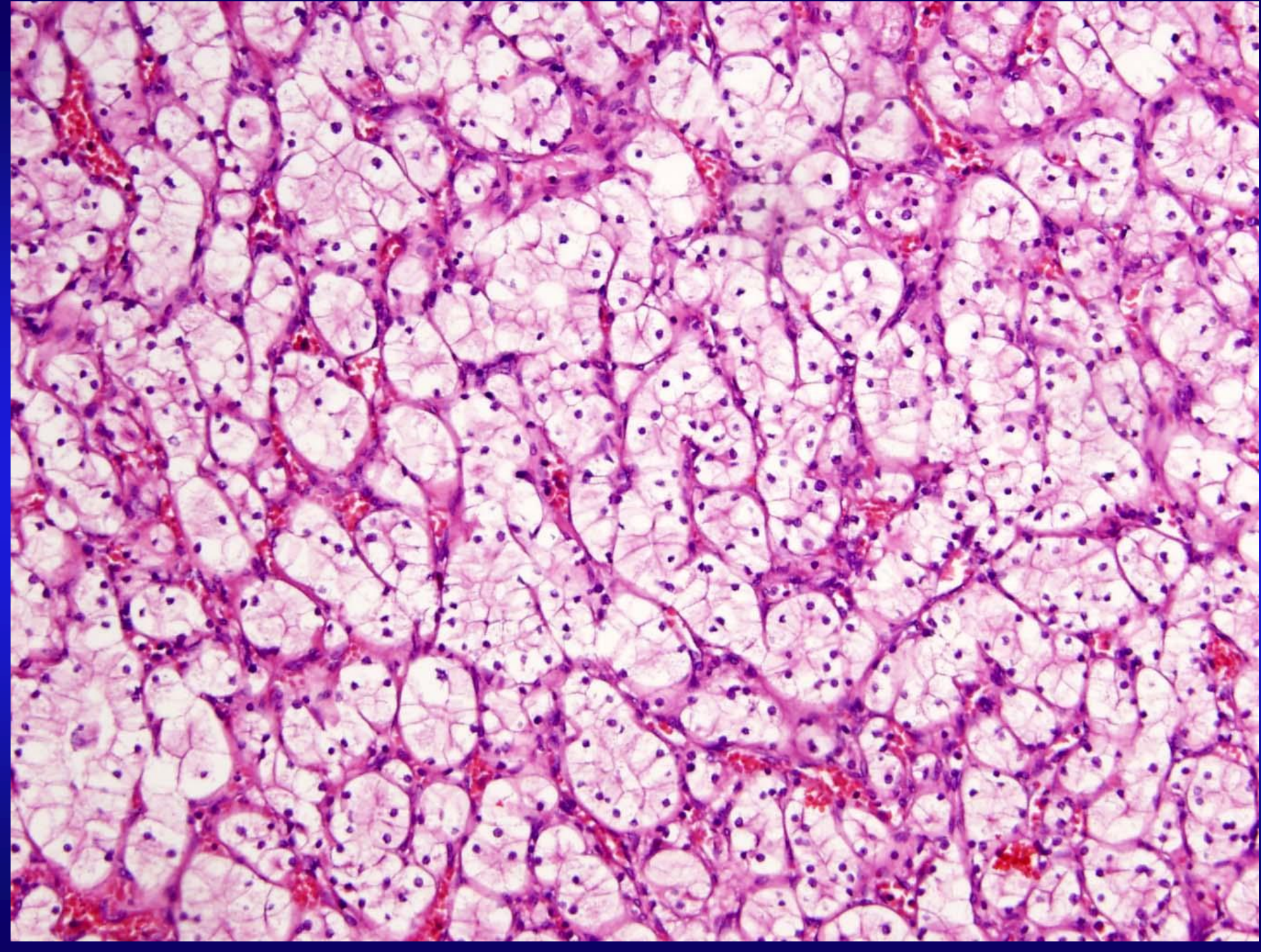


# CD57

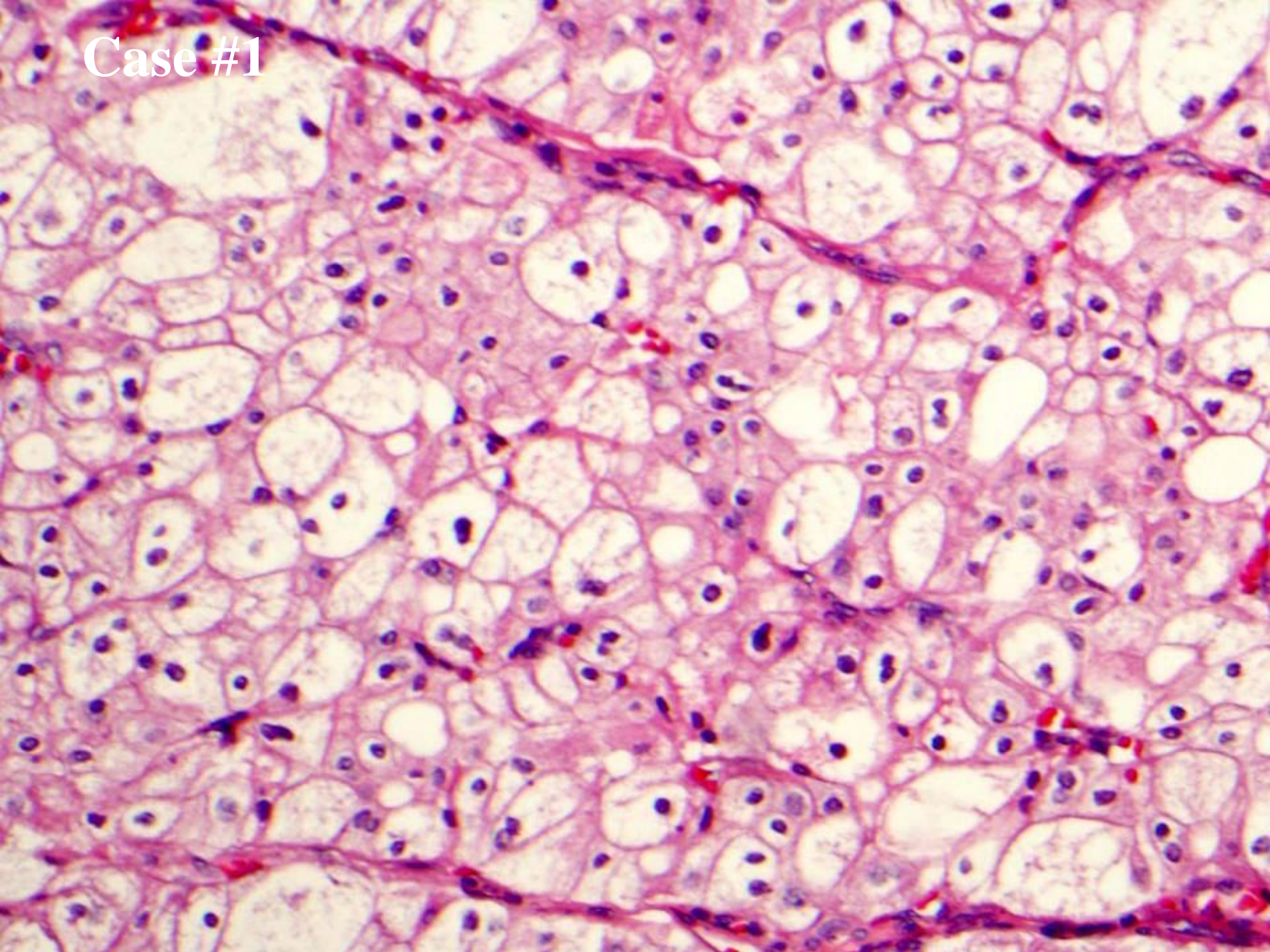


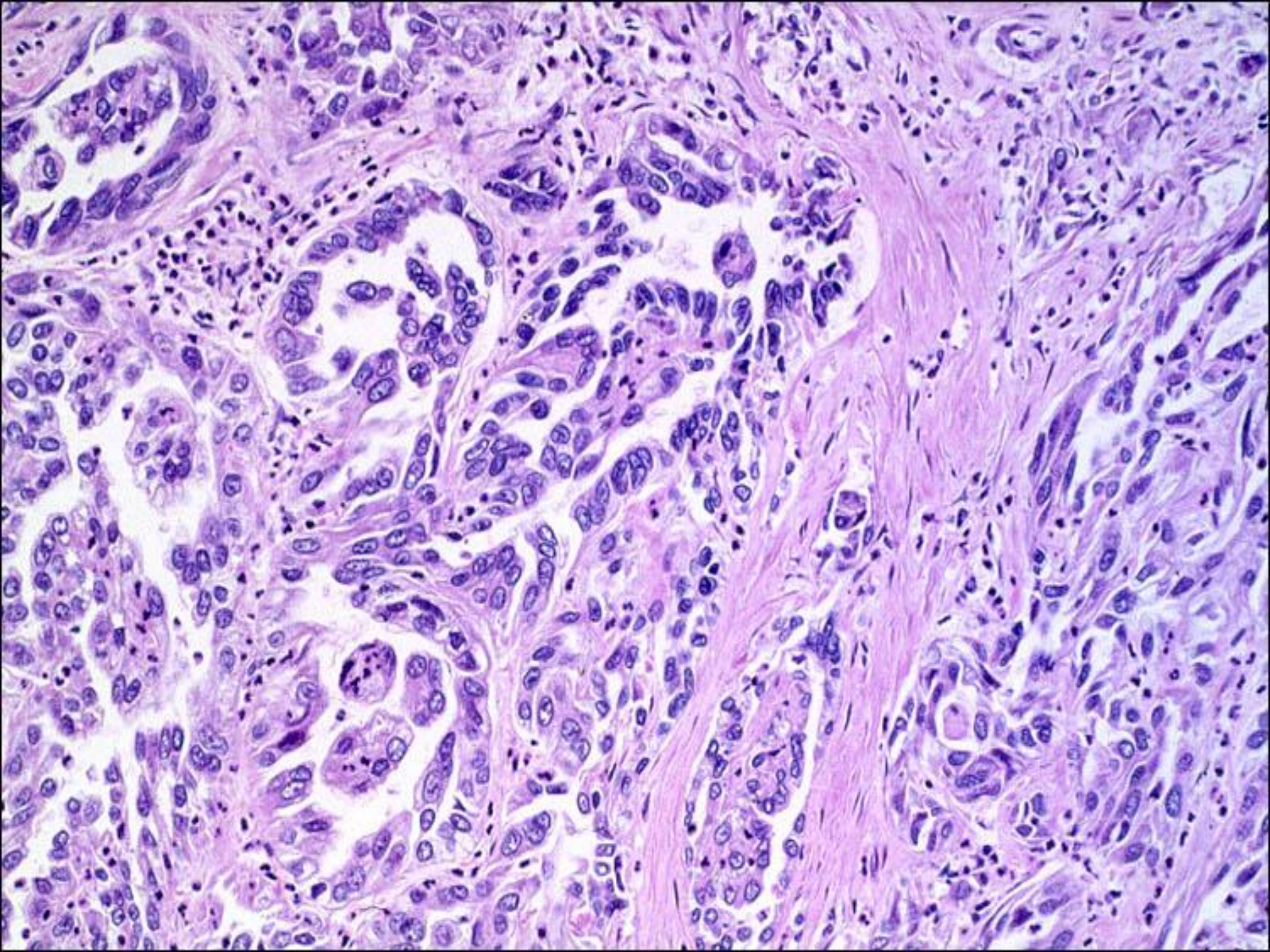
# 5 Major Kidney Cancer (RCC)

- Papillary renal cell carcinoma (pRCC)
- Conventional (clear cell) RCC
- Chromophobe RCC
- Collecting duct carcinoma
- Unclassified RCC



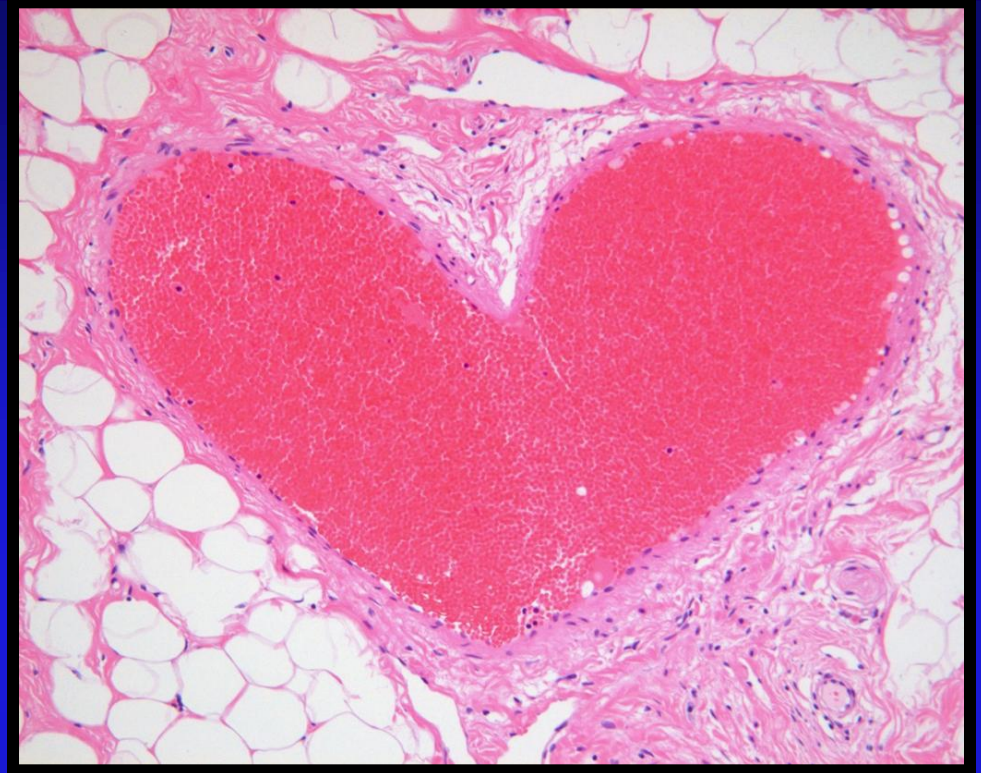Case #1





# **Renal Cell Carcinoma, Unclassified**

- Reserved for those truly unclassifiable based on adequate sampling of tumor
- Rule out metastatic tumor
- Consultation is advisable
- Immunohistochemical stains may be helpful
- Cytogenetic analysis?



**Do your BeST!**

# Pathology Resident Wiki

On the Wiki

Pathology Fellowship and Residency Directory

Wiki Activity

Random page Random Videos/Wiki Photos Pathology Jobs

Dr. Ro's BeST

 View source

Pathology Links

Talk 0

**500** PAGES ON THIS WIKI

## BeST

"You must always do your BeST to be a good pathologist."

—Dr. Ro

Besides the literal meaning of best, we have our own "BeST." The "BeST" stands for "B" representing "Basics", "e" for "enjoyment", "S" for "Study" and "T" for "Think".

### Basics:

The art of pathology is observing and diagnosing tissue or cells that are abnormal or diseased. Obviously, it is impossible to do this without knowing what "normal" looks like in the first place. Dr. Ro often repeats his favorite mantra: "You must study basic histology!" This is usually said after one of his residents confuses breast tissue with prostate, or skin with mucosa. It is an obvious truth that a solid foundational knowledge of basic normal histology is one of the keys to becoming an excellent pathologist. A diagnosis of "no pathologic alteration" (i.e.- normal) is often harder to make than a diagnosis of carcinoma. A pathologist who is well acquainted with histology and all of the unusual variations of morphology that may be seen in "normal" tissues will more easily be able to discern normal from diseased tissue.

